

CELIAC GANGLIONECTOMY FOR RAYNAUD'S DISEASE

Further Report of a Case Operated on Three Years Ago

GEORGE CRILE, M.D.

Three years ago (July, 1937) I reported in this journal¹ the immediate results of bilateral celiac ganglionectomy for a case of Raynaud's disease. The patient was a forty-two year old male who had had pain in the fingers and toes for fifteen years. He also had had intermittent numbness and tingling in the fingers, with the symptoms becoming progressive in nature so that he had been unable to work for five years. For three and a half years he had had paroxysmal pain in the finger tips which were very sensitive to pressure. This pain was so severe that he had become addicted to morphine for relief. There was a loss of sensation in the hands and feet and even in hot weather the fingers were ice cold. Typical gangrene developed in the fingers, necessitating the amputation of the right middle finger in 1934 and the left middle finger in 1937, three months before he was first seen at the Clinic (Fig. 1).

A left celiac ganglionectomy was performed on May 3, 1937 and a right celiac ganglionectomy on May 17, 1937. Complete relief from the symptoms of Raynaud's disease occurred almost simultaneously with the completion of the first operation. The patient has returned at intervals for check-ups, and was examined here on April 11, 1940. At this

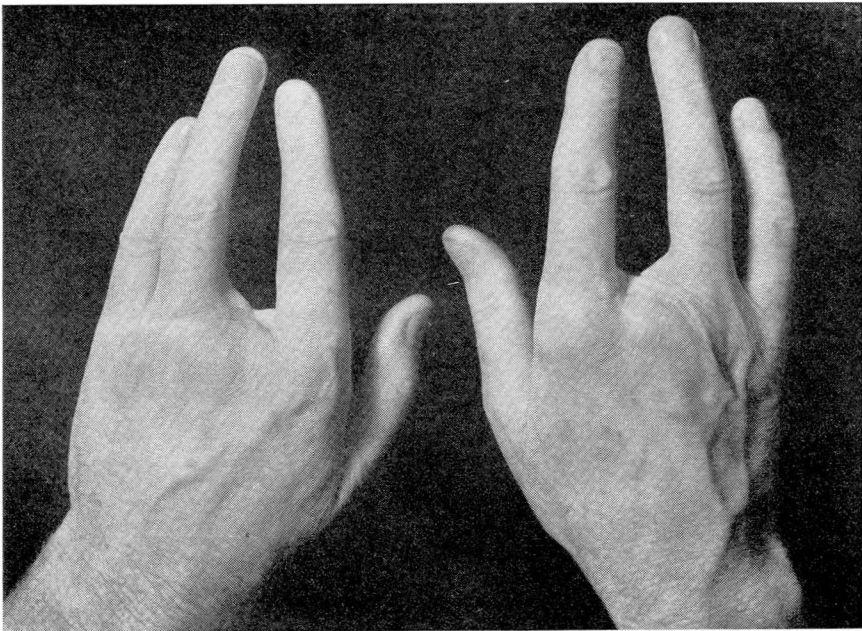


FIGURE 1: Photograph of patient's hands showing amputations.

time he stated that since the operations he no longer felt any pain nor any sensation of coldness in the extremities. A complete physical examination revealed the patient to be in good physical condition with normal radial pulsations, normal skin texture and a warm dry skin.

Dr. W. J. Zeiter, who measured the skin temperatures, reports that readings taken at the time of this recent follow-up continued to be two degrees higher than the average when the patient was first seen, indicative of the return of normal circulation to the extremities.

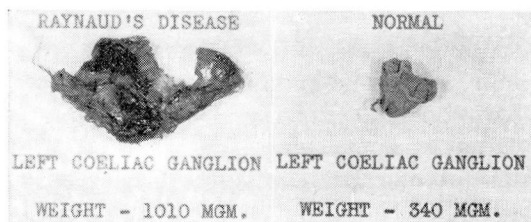


FIGURE 2: Celiac ganglion in case of Raynaud's disease compared with normal.

In the previous article we reported the abnormal size of the celiac ganglia in this case (Fig. 2): left, 1010 mg., and right, 535 mg. (normal being 340 mg.). This large size of the ganglia, which is comparable to the size in many cases of hypertension (Fig. 3), when considered together

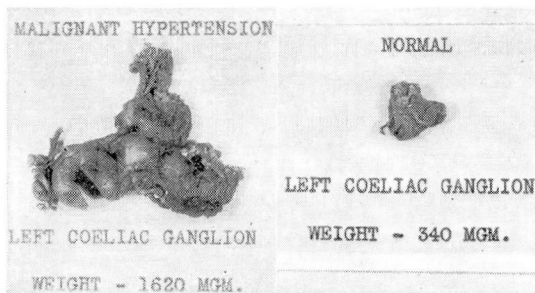


FIGURE 3: Celiac ganglion in case of essential hypertension compared with normal.

with the results of their removal, suggest that Raynaud's disease as well as hypertension is due to a pathologic physiology of the celiac ganglia, the size of which appears to be an inherited characteristic.

The personality background of this patient who suffered from Raynaud's disease is also similar to the personality background of the patient afflicted with hypertension. At school he made a good scholastic record, was active and tireless and engaged in strenuous athletics, for six years being a professional boxer. This individual history closely parallels that of the typical hypertensive history, in which a good scholastic record, an interest in athletic activities, and an active and tireless personality go hand in hand with the equipment which predisposes to hypertension and, similarly, to Raynaud's disease.

CELIAC GANGLIONECTOMY FOR RAYNAUD'S DISEASE

The results in this case, which have now continued for more than three years, and the fact that ganglionic tissue cannot be regenerated indicate that the celiac ganglion is the logical point of attack in the treatment of Raynaud's disease.

REFERENCE

1. Crile, G.: A case illustrating the analogy between essential hypertension and Raynaud's and Buerger's disease, *Cleveland Clin. Quart.*, 4:184-186, (July) 1937.