EFFECT OF VACCINIA VIRUS ON MALIGNANT MELANOMA OF HAMSTERS

WILLIAM A. HAWK, M.D.,
Division of Pathology
AND
KENNETH H. BURDICK, M.D.*
Department of Dermatology

IN 1960 one of us reported his observations on the ameliorative effects of vaccinia virus in the treatment of the cutaneous metastases of malignant melanoma.[1] Since that time, the observations have been substantiated by the studies of Belisario and Milton.[2] Because of the striking clinical improvement in some of the patients so treated, it seemed appropriate that elucidation of the mode of action and the effectiveness of vaccinia virus therapy be attempted experimentally. The results of the investigation are the basis of this report.

MATERIALS AND METHODS

Eighty-eight Golden Syrian hamsters, each weighing more than 100 gm., were inoculated with the viable neoplastic cells from a spontaneous malignant melanoma of hamsters.† The animals were separated into four groups: group 1—25 animals were inoculated with a suspension of neoplastic cells; group 2—25 were inoculated with a mixture of neoplastic cells and live vaccinia virus; group 3—28 were inoculated with a mixture of neoplastic cells and killed vaccinia virus; group 4—10 were vaccinated before inoculation with neoplastic cells.

The neoplastic inoculum was prepared by finely mincing fresh tumor removed from a donor animal, passing it through a cytosieve, and suspending the resultant minced tumor in Hanks' balanced salt solution. Approximately 1 gm. of wet neoplastic tissue suspended in 4 ml. of Hanks' balanced salt solution made a satisfactory inoculum. For those animals receiving either live or killed virus and neoplastic cells, neoplastic cells were immediately mixed with the fresh vaccinia virus from sealed capillary glass tubes; or with killed vaccinia virus prepared by sterilizing the ampules in ultraviolet light for at least three hours. Each group of animals was separated into smaller groups of five or six and was observed for periods ranging up

* *Formerly Member of the Staff, Department of Dermatology; present address: 2307 Casa Bona Avenue, Delmar, California 94002.*
† *Dr. Harry S. N. Green of Yale University, New Haven, Connecticut, kindly supplied the authors with the spontaneous malignant melanoma of hamsters.*

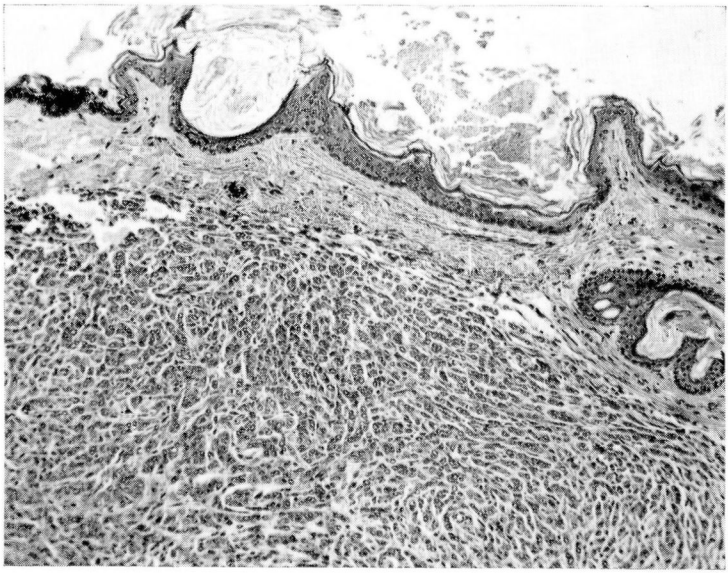

Fig. 1. Section showing typical experimental malignant melanoma of the Golden Syrian hamster. Note similarity to the human counterpart. Hematoxylin-eosin—methylene blue stain; magnification ×100.

to three months. In the early tests, tumors were implanted on the flanks of the animals; in the later tests, the right forepaws were used. All animals that died or were killed were autopsied, and appropriate histologic sections were made of the viscera. These histologic sections were prepared in the usual manner and were stained with hematoxylin, eosin, and methylene blue (*Fig. 1*).

Tissue cultures were set up from fresh neoplastic tissue obtained from the cytosieved preparations, as well as from trypsinized portions of fresh neoplastic tissue. The cultures were planted in a medium composed of 80 percent Hanks' balanced salt solution and 20 percent pooled human serum, or Parker's medium 199 and 10 percent pooled human serum. Plastic flasks were used as culture containers. All cultures were maintained and were observed for periods up to one week.

Ten Golden Syrian hamsters were kept under standard living conditions during the experiments to serve as control animals.

The vaccinia virus used was obtained from the National Drug Company who obtained the original vaccinia virus from the New York City Department of Health in 1932. This virus has been maintained in their laboratories by periodic passage in the skin of calves and storage at temperatures below −15 C. The virus titer for rabbit renal tissue cells is approximately 10^8TCID/50 per milliliter, so that a capillary tube containing 0.025 ml. of

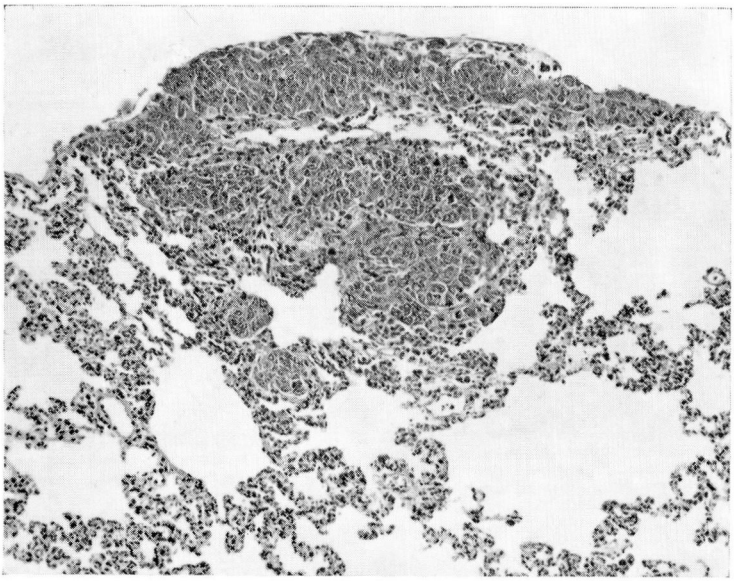

Fig. 2. Section showing microfoci of experimental malignant melanoma in a hamster lung. Hematoxylin-eosin—methylene blue stain; magnification ×110.

virus suspension has 10^2TCID/50 virus particles. One capillary tube of virus was employed in the inoculation of each animal and in the preparation of the tumor cell–virus mixtures. Similarly, this amount of virus was placed in the tissue cultures, the volume of medium being 2.5 ml., and the area of monolayer growth approximately 3.0 by 5.0 cm.

RESULTS

Animal culture

Group 1. Twenty-five animals, divided into small groups, were inoculated with 0.1-ml. cell suspensions of spontaneous melanoma of hamsters. Neoplasms developed in from 6 to 21 days (average, 10 days) after inoculation. In four animals no neoplasms developed, probably, because of faulty inoculation. Most of the animals steadily deteriorated and succumbed to the neoplasm within nine weeks. Four died from other, principally septic, causes. Autopsies performed on these four animals showed a pattern of metastasis strikingly similar to that observed in humans (*Fig. 2*). Metastatic deposits were noted in the draining regional lymph nodes, liver, lungs, and occasionally serosa of the gastrointestinal tract. Metastases were most often present in the liver when the tumor had been inoculated on the animal's flank, and were most often in the lungs when the right forepaw was the site of inoculation.

Group 2. Twenty-five animals were inoculated on their right forepaws with a mixture of neoplastic cells and live vaccinia virus. No neoplastic lesions developed at the site of inoculation within the three-week interval observed in group 1 that had been inoculated only with neoplastic cells. Seventeen of these animals were observed for periods up to 12 weeks after inoculation with the mixture of neoplastic cells and live vaccinia virus. No neoplasms developed. In many of these animals, however, small nodules developed at the inoculation sites in from 4 to 7 days after injection, but all of these nodules had disappeared spontaneously by the end of three weeks. To test further the protective effect of live vaccinia virus, four animals were reinoculated with neoplastic cells and live vaccinia virus at the end of three weeks. Within four weeks after this second inoculation, tumors developed in all of the hamsters. Four other animals were reinoculated only with neoplastic cells. Tumors in the forepaws developed in all in less than two weeks. The results observed with the four animals that received the inoculation both of live virus and of neoplastic cells are at variance with the anticipated outcome as demonstrated in the groups of animals that had single inoculations. This might be explained either as a result from attenuated virus, or as a result of alteration of immune response of the animals.

Group 3. Twenty-eight animals were inoculated with killed vaccinia virus and malignant melanoma cells. In 20, tumors developed in the forepaws within 14 days, in most of them at the end of 12 days. In eight of these animals, however, tumors developed within from 25 days to 39 days after inoculation. Four of them each had received a live vaccinia virus inoculation 25 days after the initial inoculation, which apparently had no effect on the time of appearance of the tumors.

Ten animals were first vaccinated weekly for four weeks. None showed a primary reaction to vaccination at any time during the course of the experiment. They were then injected only with neoplastic cells. In 8 of these 10 animals, tumors in the forepaws developed within two weeks. The two animals that had no tumors pursued a curious course characterized by rather precipitous loss in weight for eight weeks. At the end of this time they apparently recovered but still showed no evidence of tumor. This general loss in weight was interpreted as a possible viremia, and the lack of tumors may have been due to nonspecific factors.

The average duration of life after the development of tumors ranged from 8 to 10 weeks. To assess the possible palliative effect of vaccinia virus injected directly into the tumors, 12 animals were so treated. During the period of observation, the tumors became largely necrotic, but the hamsters steadily deteriorated and died within approximately the same length of time as those that had not been treated. Because of an inoculation error in

one experimental animal, two tumors developed. One tumor was treated with live vaccinia virus injected directly into it; the other tumor was observed as a control. The injected tumor became necrotic; the uninjected tumor flourished.

Group 4. In none of the 10 hamsters serving as controls did spontaneous malignant melanomas develop.

Tissue culture

Tissue cultures were prepared five times from portions of the neoplastic tissue that was being used to inoculate the various experimental animal groups as described. All cultures grew. However, when either live or killed vaccinia virus was mixed with neoplastic cells in tissue cultures, there was no growth of neoplastic cells in culture. Some cultures of malignant melanoma cells of hamster not containing a virus were grown for approximately 72 hours and were then placed in a medium containing live vaccinia virus. Within 24 hours, all of these cultures were dead. On stained preparations of cells recovered from these cultures no virus inclusion bodies were seen within the dead melanoma cells. Likewise, in histologic preparations of the metastases from animals treated with live vaccinia virus, neither intranuclear nor intracytoplasmic viral inclusions were observed.

DISCUSSION

Theoretically, a live virus could destroy a tumor in many ways; the three most probable mechanisms are: (1) the virus kills the neoplastic cells with specific immunologic interference by the healthy host cells and antibodies; (2) the virus acts as a hapten with the proteins of the infected neoplastic cells, and elicits a specific antibody response from the host; (3) on the basis of a possible viral origin for such tumors, the reaction to the introduction of viral material such as vaccinia virus into the neoplastic cells precipitates an immune response by the host, which reinforces the host's resistance to the tumor.

In clinical studies, specific resistance apparently has been enhanced by a number of viral agents, including west Nilo virus, rabies vaccine, and vaccinia with human melanomas. Since this readily transplantable spontaneous melanoma of hamsters behaves in its growth and metastatic pattern much as the human melanoma does, it was worthwhile to test the effect of the vaccinia virus. Unfortunately for interpretation in regard to human melanomas, the response of the hamster in terms of forming antibodies to the vaccinia virus is quite different from that of humans. Repeated vaccinations of some of the hamsters produced no vaccination reactions typical of human, either in control animals or in animals repeatedly inoculated with virus directly into the neoplastic tissues. However, in all hamsters

treated with live vaccinia virus after the appearance of tumors, the tumors became necrotic, their growth slowed, and the tumors often ulcerated. Regional metastases and the ultimate clinical course of the animal did not seem to be affected by such treatment. Ten animals were vaccinated four times before the tumors were transplanted. Treatment of the tumors by vaccinia virus in these animals produced the same results as in those vaccinated only after the tumors were growing. In all cases, mixing live virus with the tumor inoculum before injection prevented the development of such tumors. It is most interesting that in these animals, BB-sized, firm nodules developed in approximately from four to seven days after injection. These nodules rapidly disappeared. Their formation represented a distinct variation from the course of those animals inoculated with killed vaccinia virus in the tumor inoculum, and of those that received either neoplastic cells or live virus alone. The addition of killed vaccinia virus to the neoplastic inoculum delayed the development of the nodules of melanoma, compared with those in the animals that received only the tumor cells. However, addition of killed vaccinia virus to the neoplastic inoculum did not modify the pattern of metastases and the ultimately fatal course.

While the healthy untreated neoplastic cells grew rather readily in tissue culture, the addition of foreign material to the delicately balanced artificial environment could well be expected to upset growth. Both the killed virus and the live virus prevented tissue culture growth. The addition of live virus to tissue cultures after growth was established, resulted in death of all neoplastic cells within 24 hours.

SUMMARY

The spontaneous malignant melanoma of the Golden Syrian hamster is readily transplanted from hamster to hamster. When a neoplastic inoculum was mixed with live vaccinia virus, transplantation always failed, except in the animals that had received a prior inoculation. When a neoplastic inoculum was mixed with killed vaccinia virus, no protective effect was noted in the recipient. Injection of live vaccinia virus into growing tumors produced early neoplastic necrosis and slough, but failed to alter the inexorable course of the neoplasm. Prior vaccination of the animals with live vaccinia virus also gave no protection. Viral inclusions within the tumor could not be demonstrated after vaccinia viral therapy.

REFERENCES

1. Burdick, K. H.: Malignant melanoma treated with vaccinia injections. (Abs.) Society Transactions. Arch. Dermat. **82:** 438, 1960.

2. Belisario, J. C., and Milton, G. W.: The experimental local therapy of cutaneous metastases of malignant melanoblastomas with cow pox vaccine or colcemid (demecolcine or omaine). Australian J. Dermat. **6:** 113–118, 1961.