

NEEDLE BIOPSY OF THE LIVER

H. R. ROSSMILLER, M. D., CHARLES H. BROWN, M. D. and
JOHN F. WHITMAN, M. D.

Department of Gastroenterology

Introduction

NEEDLE puncture of the liver was first performed by Stanley¹ in 1833 to drain an abscess, and was first employed as a diagnostic procedure by Lucatello² in 1895. A few investigators in Europe have given accounts of diagnostic liver biopsies prior to 1939, but this technic did not come into widespread use until the report of Iversen and Roholm³ in 1939 on liver biopsy in 160 cases. With the advent of the war and increased incidence of hepatitis, general use gradually was made of liver biopsy as a diagnostic technic. Needle biopsy was utilized during the war chiefly as a means of studying the pathology of infectious hepatitis. Since then it has proved valuable in other conditions as well.

The first method of liver biopsy consisted of simple aspiration of a few liver cells with a smear made of the material obtained. Iversen and Roholm used a similar aspiration technic, but removed a plug of tissue which proved to be more satisfactory. A number of investigators have taken a specimen for biopsy at operation^{4,5} or have used small incisions to obtain one. Biopsy specimens also have been obtained during peritoneoscopic examination.⁶ A refinement of the early technic has been the "Vim" Silverman needle used to secure a plug of tissue satisfactory for pathologic study.

Investigators have used the intercostal approach, the subxyphoid, and the subcostal. Many have been concerned over possible tears in the liver capsule that might be caused by respiratory movement with the intercostal approach. Others, fearing possible perforation of other viscera with the subxyphoid approach in the patient who does not have a palpable liver, have limited the use of this technic to patients with palpable livers. Ricketts⁷ has used the intercostal approach in some 300 cases, and Schiff⁸ in 700 cases; both feel that this is the method of choice and both have had no complications using this method. Hoffbauer⁹ has used the subcostal approach in patients with palpable livers, and biopsy under peritoneoscopic visual control in patients without hepatomegaly.

For any diagnostic procedure to be worth-while, there must be a minimum of resultant mortality. Prior to the Iversen and Roholm report there were 6 deaths in 403 cases. Iversen and Roholm reported 160 cases in 1939 without a single death. Other investigators have also reported large series without any mortality. Among others, Gilman and Gilman¹⁰ had no deaths in 906 biopsies, Van Beek¹¹ had no deaths in 200 biopsies, Hatieganu¹² none in 45, Hoffbauer⁹ none in 65, Davis et al¹³ none in 79, Schiff⁸ none in 700,

Dickinson¹⁴ none in 119, Webb and Werthammer¹⁵ none in 70. Sherlock¹⁶ records 2 deaths in 264 biopsies, Volwiler, and Jones¹⁷ 1 in 234 biopsies, Dible et al¹⁸ 1 in 126 biopsies. These figures indicate that with the necessary precautions, diagnostic needle biopsy of the liver is a relatively safe procedure.

Liver biopsy has been of great value in furthering our understanding of infectious (epidemic) hepatitis and serum hepatitis. The contributions of Iversen and Roholm,³ Sherlock,¹⁶ Dibble, McMichael and Sherlock¹⁸ have been outstanding and have clarified the pathology of infectious hepatitis which had not been well understood previously. It also has been helpful in our knowledge of other liver conditions such as cirrhosis, brucellosis,¹⁹ and phosphorus poisoning.²⁰ Liver biopsy has been used in estimating the prognosis in patients with cirrhosis, and in evaluating the therapeutic program for cirrhosis.^{17,21} Liver biopsy has been used to evaluate and correlate liver function tests with pathologic alterations^{5,22,23} and has indicated further the use and limitations of liver function tests. As indicated by Volwiler and Jones,¹⁷ liver function tests merely show impaired liver function and are not a measure of exact diagnosis. Liver function tests do not disclose whether the impaired function is due to cirrhosis, metastatic malignancy, primary hepatoma, or other pathologic conditions. The multiplicity of functions of the liver, and the vast number of tests employed indicate that an exact diagnosis of liver disease is frequently difficult on the basis of liver function tests alone. Frequently it is much simpler and more satisfactory to do a liver biopsy than to run a gamut of liver function tests that do not give an exact diagnosis. Some conditions such as primary and metastatic cancer, hemochromatosis, amyloid disease, and Gaucher's disease may

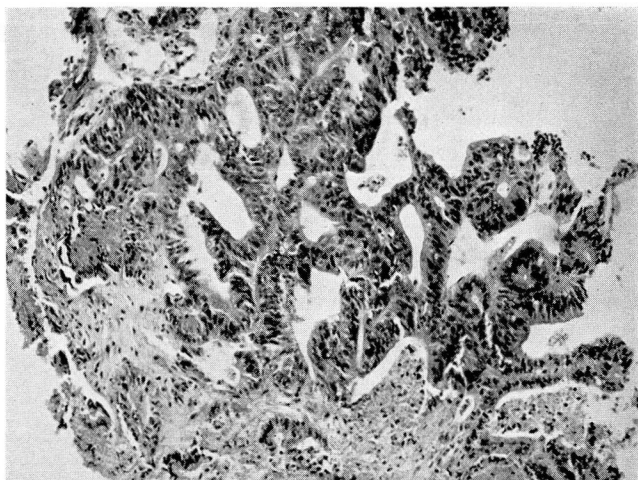


Fig. 1. Adenocarcinoma, metastatic in liver, obtained by needle biopsy. Primary site unknown (x-70).

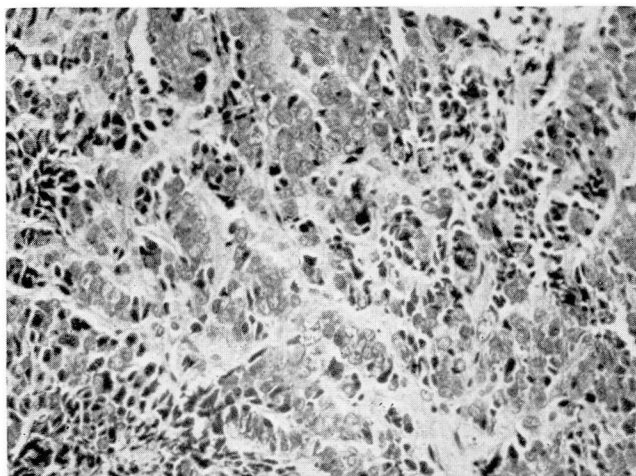


Fig. 2. Metastatic carcinoma, probably bronchogenic (x-200).

be diagnosed ante mortem only by liver biopsy or an exploratory laparotomy.

Many of the difficulties that have complicated needle biopsy of the liver have arisen because of the moribund condition of the patient or because certain precautions were not followed. The exact technic and method used appears not to have made much difference in the published mortality figures, whether the subcostal, subxyphoid, or intercostal approach was used. The contraindications to needle biopsy of the liver are: 1. presence

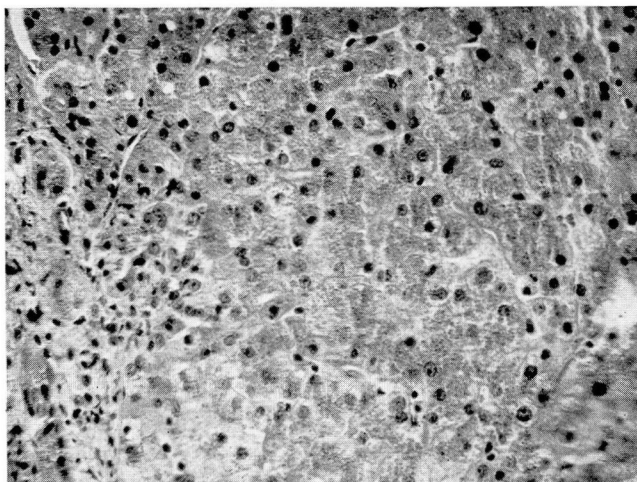


Fig. 3. Hemochromatosis of liver (x-200).

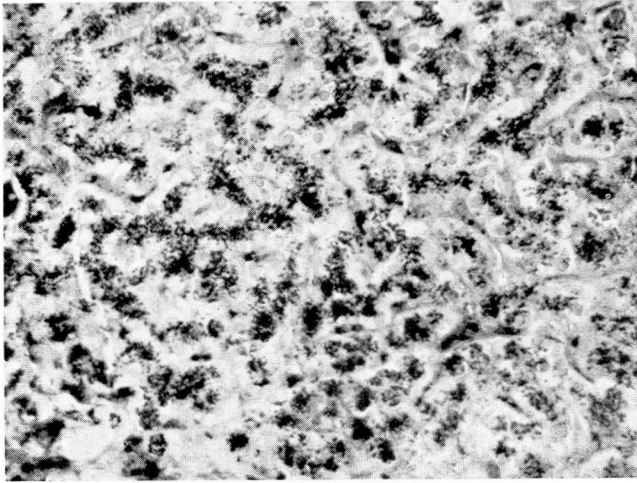


Fig. 4. Hemochromatosis of liver with "Berlin Blue" stain²⁴ to show hemosiderin deposits (x-200).

of pyogenic infection in the liver; 2. increased bleeding tendency; 3. increased prothrombin time.

The approach to liver biopsy at the Cleveland Clinic has been entirely similar to that reported by Hoffbauer.⁹ Biopsy has not been attempted in cases of pyogenic infection, in patients with a bleeding tendency, or unless the prothrombin time was at least 75 per cent. The "Vim" Silverman needle has been used with a subcostal approach in patients with palpable livers. When a large nodule was present in the liver, an attempt was made to obtain a specimen from the nodule. In the patient who did not have palpable liver, biopsy was obtained with the "Vim" Silverman needle under peritoneoscopic visual control. We have been hesitant in using the intercostal approach because of possible tears in the liver capsule. We have also been reluctant to use the subxyphoid approach in the absence of a palpable liver because of the possible perforation of other viscera. The actual technic of the "Vim" Silverman needle has been adequately described by others.

Results

TABLE I
ADEQUACY OF BIOPSY

	Silverman Needle	With Peritoneoscopy	Total
Satisfactory specimen	46	21	67
Unsatisfactory specimen	4	4	8
			—
			75

The results obtained in 75 liver biopsies are recorded in Table 1. A specimen adequate for pathologic diagnosis was obtained in 67 out of 75 biopsies. Fifty of the biopsies were done in patients with hepatomegaly, using the subcostal approach. Twenty-five biopsies were obtained in patients without an enlarged liver by use of the "Vim" Silverman needle under peritoneoscopic control.

TABLE 2
DIAGNOSES FROM LIVER BIOPSY

Diagnosis	Number of Patients
Cirrhosis	26
Metastatic malignancy	18
Fatty metamorphosis	9
Primary liver cell carcinoma	3
Bile stasis	3
Hemosiderosis	3
Malignant melanoma	2
Hemochromatosis	2
Hepatitis	2
Amebic abscess	1
Gaucher's disease	1
Biliary cirrhosis	1

The diagnoses established by liver biopsy are presented in Table 2. Although the most common condition found by biopsy was cirrhosis, only a small number of patients with cirrhosis were subjected to liver biopsy. However, biopsy may be of value in some patients with moderately advanced cirrhosis, who show little change in liver function. In addition, the presence of impaired liver function may be due to causes other than cirrhosis which may be discovered by biopsy. Liver biopsy also may help in the diagnosis of cirrhosis and in evaluating the prognosis and therapeutic program the patient has been following.

Nine patients were found to have fatty metamorphosis of the liver, a condition that is considered precirrhotic, and a condition that is usually amenable to treatment.

Eighteen patients were found to have metastatic cancer. A positive diagnosis in these cases seems of value from a prognostic point of view. Liver biopsy is practicable and may save the patient the expense and discomfort of a needless laparotomy. In addition there are many patients in whom there is evidence of metastatic malignancy, but in whom the primary site remains obscure. Liver biopsy may be the simplest diagnostic procedure in these cases, and may yield the most information.

It must be stressed that a negative biopsy is worthless in suspected cancer. The metastatic nodule may easily be missed by the biopsy needle. We have made every attempt to biopsy a nodule when present. A repeat biopsy when

the first one is negative and when there is a strong suspicion of metastatic malignancy is clearly indicated.

Primary liver cell carcinoma was found in 3 cases. The first biopsy in one of these cases showed only cirrhosis; a second biopsy showed a primary hepatoma to be the cause of the patients tremendous hepatomegaly.

Bile stasis, strongly suggestive of an obstructive biliary tract lesion such as neoplasm of the pancreas, was found in 3 patients. Volwiler and Jones¹⁷ and Webb and Werthammer¹⁵ have stressed the value of liver biopsy in the diagnosis of jaundice.

Metastatic malignant melanoma was diagnosed ante mortem in 2 cases, hemochromatosis in 2 cases, and Gaucher's disease in 1 case. It is unlikely that a positive diagnosis could have been established ante mortem without a liver biopsy unless the more hazardous procedure – exploratory laparotomy – was done.

Hepatitis was found in only 2 cases. This is not an index of the frequency of hepatitis, but an indication that the newer liver function tests are usually accurate in diagnosing this condition. Liver biopsy was seldom necessary to establish the diagnosis.

Various complications of needle biopsy of the liver have been reported. The relative safety of the present procedure, following the precautions already cited, has been discussed. The most frequent complication of liver biopsy has been bleeding following the biopsy. Other writers have reported finding duodenal¹³ and colonic mucosa in the biopsy specimen. The patients in whom this occurred, however, survived the procedure. Using the precautions and technic already mentioned, we have had no deaths in the 75 biopsies performed. There has been no appreciable bleeding in these patients, and none required transfusions. Biopsy in 3 patients yielded clear bile, but no difficulty ensued. The patients suffered little if any discomfort following the simple needle biopsy. A few patients had some discomfort for several hours after the procedure with pain in the right upper quadrant, referred to the right shoulder; however none had fever, leukocytosis, or other complications. Somewhat more discomfort was experienced for 24 hours after the peritoneoscopic examinations.

Liver biopsy by the Silverman needle is preferable to exploratory laparotomy with a small incision as advocated by some⁴ as biopsy entails less risk of morbidity and death.

Establishing a diagnosis in the cases cited was important and would not have been possible without a liver biopsy or an exploratory laparotomy.

Case Reports

Case 1. Metastatic Adenocarcinoma. A 50 year old man came to the Cleveland Clinic with a history of anorexia and gradual loss of 26 pounds in the past 4 months. He had been constipated for 3 months and had had a dull pain in the right flank for 1 month. Physical examination revealed a large nodular mass in the right upper quadrant, presumably in the liver. This mass was biopsied with a Silverman needle and a pathologic diagnosis of adenocarcinoma was made (fig. 1).

This case illustrates the point that frequently a liver biopsy will elicit more information concerning the patient than any other method of study with the exception of exploratory laparotomy.

Case 2. Metastatic Carcinoma. A 47 year old man complained of severe abdominal pain for 2 weeks, mild dyspnea for 2 years, severe dyspnea for 2 months, cough productive of blood streaked sputum for 2 months, and clotted blood in vomitus on one occasion. He had lost 28 pounds in weight. Physical examination revealed an enlarged lymph node above the right clavicle, fleeting fine rales in the chest, and a tender liver descending 7 cm. below the costal margin. Laboratory tests were noncontributory. Roentgenograms of the chest showed an irregular nodular mass involving chiefly the anterior mediastinum. Liver biopsy with the Silverman needle showed undifferentiated carcinoma (fig. 2).

The primary site of carcinoma in this patient was not evident, and might have required considerable searching to determine, although it probably was bronchogenic.

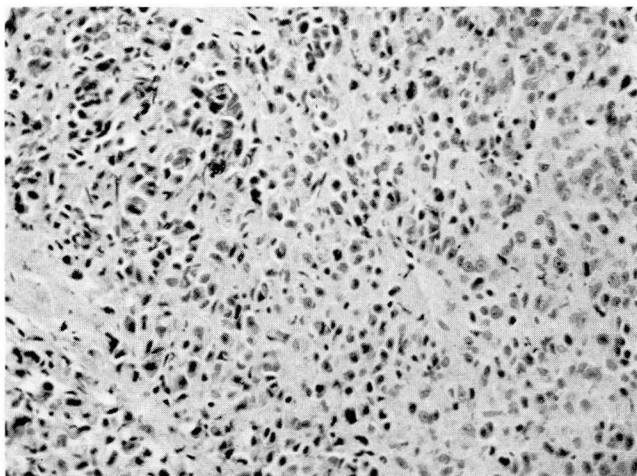


Fig. 5. Melanosarcoma of liver (x-200).

Extensive studies, and possibly even thoracotomy, might have been necessary to have established the diagnosis of metastatic malignancy if liver biopsy had not revealed the disease.

Case 3. Hemochromatosis. A 40 year old woman complained of pain in the right flank, backache, and excessive thirst for approximately 6 months. There was a past history of excessive wine consumption. During the examination, the patient had a sudden onset of generalized weakness, headache, nausea and vomiting. Positive findings on physical examination were: Kussmaul breathing, acetone odor of the breath, dehydration, dark gray color of the skin, and severe hepatomegaly. The liver descended 11 cm. from the costal margin in the right midclavicular line. Blood sugar was 588 mg. per 100 ml. and CO_2 combining power was 14.4 volumes per cent. Prothrombin time, and bromsulfalein liver function tests were normal. She was treated in a routine manner for her diabetic acidosis. Liver biopsy with the Silverman needle revealed many refractile brownish pigment granules which reacted positively to iron stains in both liver cells and connective tissue. She subsequently died, and severe hemochromatosis of liver, spleen and pancreas was found (figs. 3 and 4).

NEEDLE BIOPSY

Hemochromatosis is often suspected before death, but usually a positive diagnosis of this condition is not ascertained. Liver biopsy readily disclosed the nature of this patient's diabetes and hepatomegaly.

Case 4. Malignant Melanoma. A 41 year old man complained of frequent nausea, gaseous dyspepsia, and distention for 8 months. He had had an enucleation of his left eye 5 years previously. The surgeon was contacted and reported that the eye had been removed because of separation of the retina and atrophy of the globe, and that there had been no evidence of malignancy in the pathologic specimen. On examination, the left lobe of the liver descended 6 cm. below the costal margin, and the right lobe 9 cm. below the costal margin. One definite nodule was palpated. Roentgenogram of the chest, intravenous urogram, and barium enema examination were essentially negative. Routine blood count and laboratory studies were normal. Liver function tests (prothrombin time, bromsulphalein, and albumin/globulin ratio) were normal. Liver biopsy with the Silverman needle was done over the nodule palpated. The pathologic specimen showed round and polyhedral epithelial cells occurring in solid groups. The nuclei were prominent and many cells contained brownish nonrefractile pigment. An iron stain showed no bluing of the pigment granules. The pathologic diagnosis was malignant melanoma (fig. 5).

In view of the negative history of malignancy in the enucleated eye, a positive diagnosis of malignant melanoma could not have been made without liver biopsy.

Case 5. Primary Hepatoma. A 71 year old Chinese man complained of right upper quadrant pain, anorexia, weakness and swelling of the ankles for approximately 2 months. His diet was questionably deficient and there had been some excess alcoholic intake. Positive physical findings included the presence of a large firm smooth liver that extended below the iliac crest. Roentgenographic examinations were all negative except for indications of an enlarged liver shadow. Complete laboratory examinations were also negative except for severe impairment of liver function. The prothrombin concentration was 72 per cent of normal. There was 45 per cent bromsulphalein retention in 30 minutes, using 5 mg. of dye per kg. body weight. Cephalin cholesterol was 2 plus, and thymol turbidity was 8 units. There was a reversal of the albumin-globulin ratio, the albumin 2.7 Gm. per 100 ml. and the globulin 5.4 Gm. per 100 ml. A needle biopsy was done which showed only moderate cirrhosis. Because of the definite enlargement of the liver and the strong suspicion of a primary hepatoma, a second liver biopsy specimen was obtained. The latter showed neoplasm formed by atypical epithelial cells which were growing as single cells without attempt at duct formation. The cells were of moderate size and there were many mitotic figures. The pathologic specimen was thought to be compatible with a primary liver cell hepatoma.

The true nature of the patient's disease could not have been diagnosed by the liver function tests alone, since they indicated impaired liver function but did not disclose the underlying malignancy. The diagnosis could have been accomplished only by post-mortem examination, exploratory laparotomy which was contraindicated in view of his liver function, or by simple needle biopsy of the liver. This case illustrates the point that a needle biopsy of the liver may miss a neoplastic lesion. The first biopsy was negative for carcinoma; only after the second biopsy was the neoplasm found. If there is a strong suspicion of carcinoma, a second liver biopsy should be done even though the first is nondiagnostic.

Summary

"Vim" Silverman needle biopsies of the liver have been done in 75 patients at the Clinic. They were not performed on patients with evidence of: 1. pyogenic infection, 2. increased bleeding tendency or 3. increased prothrombin time. Biopsy with the Silverman needle alone was done on 50

patients with hepatomegaly, and biopsy with the needle under peritoneoscopic control in 25 patients without an enlarged liver. Satisfactory specimens were obtained in 67 of the 75 cases. The only complications of the biopsies were the aspiration of bile in 3 cases; none manifested postbiopsy bleeding, fever, or leukocytosis.

Needle biopsy using the necessary precautions is a safe diagnostic procedure and was helpful in 26 cirrhotic cases in which liver function tests and the clinical picture failed to give an accurate diagnosis. It also confirmed the diagnosis in 18 patients with metastatic malignancy. The simple procedure of liver biopsy saved many of these patients the expense and discomfort of an exploratory operation.

Biopsy was indicated in the diagnosis of obstructive jaundice in 3 cases. Primary liver cell carcinoma, a condition in which a positive diagnosis is seldom made ante mortem, was discovered in 3 patients. Other conditions in which liver biopsy was of paramount importance in arriving at a diagnosis were malignant melanoma, hemochromatosis, and Gaucher's disease.

Liver biopsy with the "Vim" Silverman needle has proved to be an important procedure in the diagnosis of obscure liver disease.

References

1. Stanley: Cited by Davis, Scott, and Lund.¹³
2. Lucatello: Cited by Iversen and Roholm³.
3. Iversen, P., and Roholm, K.: On aspiration biopsy of liver, with remarks on its diagnostic significance. *Acta med. Scandinav.* **102**:1, 1939.
4. Womack, N. A.: Biopsy of liver. *North Carolina M. J.* **8**:300 (May) 1947.
5. Mateer, J. G., Hartman, F. W., et al: Combined liver biopsy and liver function study in 132 cases of cholelithiasis and 31 cases of peptic ulcer, operated cases. *Gastroenterol.* **11**:284 (Sept.) 1948.
6. Kalk, H., Bruhl, W., and Sieke, W.: Die gezielte Leberpunktion. *Deutsche med. Wchnschr.* **69**:693 (Oct. 1) 1943.
7. Ricketts, W. E.: Personal communication.
8. Schiff, L.: Personal communication.
9. Hoffbauer, F. W.: Needle biopsy of liver. *J. A. M. A.* **134**:666 (June 21) 1947.
10. Gilman, T., and Gilman, J.: Modified liver aspiration biopsy apparatus and technique, with special reference to its clinical application as assessed by 500 biopsies. *South African J. M. Sc.* **10**:53 (June) 1945.
11. Van Beek, C., and Haex, A. J. C.: Aspiration biopsy of liver in mononucleosis infectiosa and in Besnier-Bocck-Schaumann's disease. *Acta med. Scandinav.*, **113**:125, 1943.
12. Hatieganu, I., Sparchez, T., Radu, P., and Macavei, I.: cited by Sherlock¹⁶.
13. Davis, W. D., Scott, R. W., and Lund, H. Z.: Needle biopsy of liver. *Am. J. M. Sc.* **212**:449 (July) 1946.
14. Dickinson, L.: Needle biopsy in diagnoses of liver disease; preliminary report. *Kentucky M. J.* **46**:182 (May) 1948.
15. Webb, J. P., and Werthammer, S.: Needle biopsy of the liver in the diagnosis of surgical jaundice. *South. Surgeon* **15**:393 (June) 1949.

NEEDLE BIOPSY

16. Sherlock, S.: Aspiration liver biopsy; technique and diagnostic application. *Lancet* 2:397 (Sept. 29) 1945.
17. Volwiler, W., and Jones, C. M.: Diagnostic and therapeutic value of liver biopsies. *New England J. Med.* 237:651 (Oct. 30) 1947.
18. Dible, J. H., McMichael, J. and Sherlock, S. P. V.: Pathology of acute hepatitis; aspiration biopsy studies of epidemic, arsenotherapy and serum jaundice. *Lancet* 2:402 (Oct. 2) 1943.
19. Hoffbauer, F. W., and Spink, W. W.: Biopsy of liver in patients with active brucellosis; description of hepatic lesions. *J. Lab. and Clin. Med.* 32:315 (March) 1947.
20. LaDue, J. S., Schenken, J. R., and Kuker, L. H.: Phosphorus poisoning, report of 16 cases with repeated liver biopsies in recovered case. *Am. J. M. Sc.* 208:223 (Aug.) 1944.
21. Davis, W. D.: Prognostic value of biopsy. *J. Lab. and Clin. Med.* 32:1526 (Dec.) 1947.
22. Hoffbauer, F. W., Evans, G. T., and Watson, C. J.: Cirrhosis of liver, with particular reference to correlation of composite liver function studies with liver biopsy. *M. Clin. North America* 29:363 (March) 1945.
23. Hoffbauer, F. W.: Correlation of composite liver function studies with histologic changes in liver as noted in biopsy material. *J. Lab. and Clin. Med.* 30:381 (April) 1945.
24. Berlin Blue Stain—Pathologic Technic, U. S. Naval Medical School, National Naval Medical Center, Bethesda, Md. p. 67.