

## GASTROSCOPY

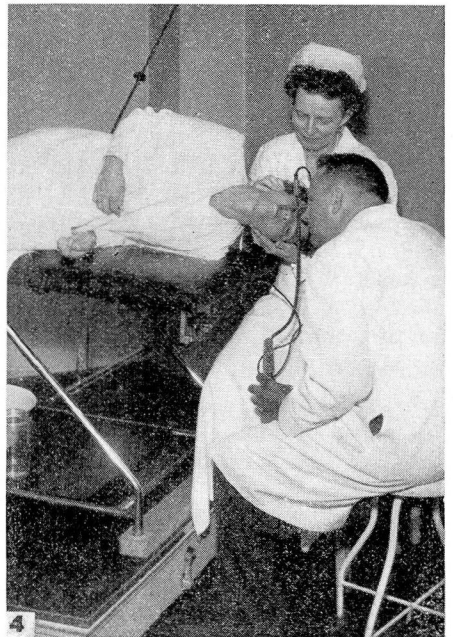
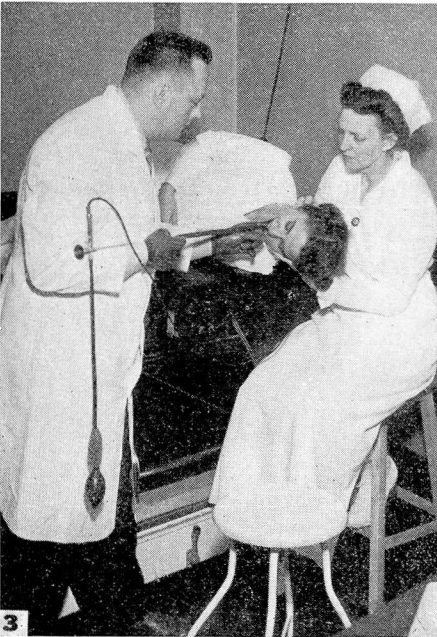
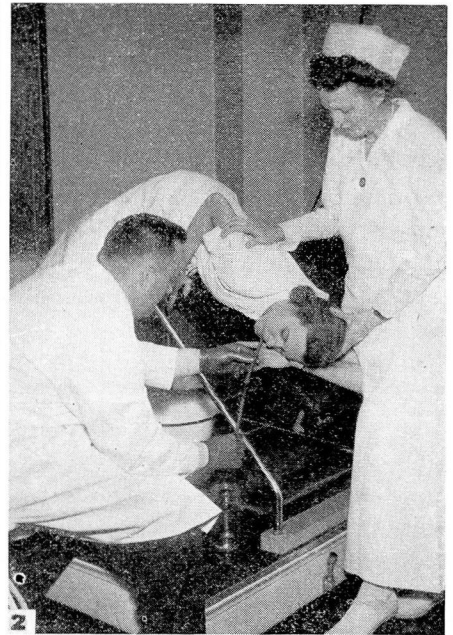
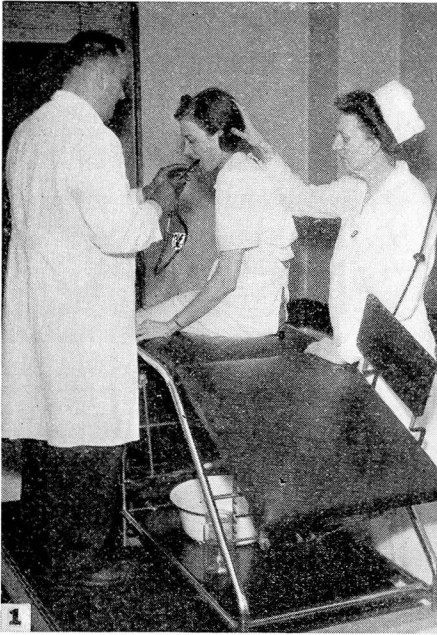
R. J. F. RENSHAW, M.D.

Three endoscopic procedures for study of the gastrointestinal tract, esophagoscopy, gastroscopy, and proctoscopy, are used unhesitatingly by the internist specializing in gastroenterology when indicated. The clinician is well aware of the limitations and values of esophagoscopy and proctoscopy, but gastroscopy being the newest procedure has but recently been established as a valuable diagnostic aid. Bockus<sup>1</sup> states, "unquestionably the flexible gastroscope is opening up new diagnostic channels. The method has already justified itself in the study of some patients with a suspicion of stomach disease . . . gastroscopy should be called upon in any case in which the diagnosis remains obscure after the application of roentgenography and other diagnostic aids. Every gastroenterologic clinic should be equipped with a flexible gastroscope and its personnel should include someone trained in its use."

It is agreed that gastroscopy is an office procedure. The examination need not be made formidable to the patient by using an operating room or an elaborate set-up. The examination is best performed in a gastroenterologic clinic, where results can be correlated by the gastroenterologist with those of other common gastroenterologic tests.

The examination is done in the morning on a fasting stomach. In general, the technic is that advanced by Schindler<sup>2</sup> with minor modifications according to the needs or desires of the examiner (figure).

I have found it advantageous to reduce the preparatory time to a minimum to prevent the patient from becoming unduly anxious. Whereas preparation used to take nearly an hour, I now complete the entire examination within thirty minutes, of which only fifteen or twenty are used in preparation. The patient first receives a hypodermic injection of 1/100 gr. of atropine and 1 gr. of sodium phenobarbital. Two or three minutes later he is given a gargle of a few cubic centimeters of 2 per cent pontocaine. Five cubic centimeters of the solution is then sprayed into the throat with a Schindler anesthetic tube.<sup>2</sup> Five minutes later this is repeated. Although the preparation time is short, the desired effect of atropine upon salivary secretion is obtained in at least 95 per cent of the cases. Sodium phenobarbital is not used for sedation but to counteract any idiosyncrasy to pontocaine. With this technic I have not had a serious pontocaine reaction in over six years.



FIGURE

1—Introduction of Ewald Tube. 2—Aspiration of gastric content without suction.  
3—Introduction of Gastroscope. 4—Gastroscope at full depth of insertion.

## GASTROSCOPY

Contraindications to the use of the flexible gastroscope are few.

1. Gastroscopic examination of the stomach should always be preceded by roentgenologic examination to exclude the principal contraindication, disease of the esophagus. Open tube esophagoscopy should be used in questionable cases. Although esophageal varices do not always contraindicate gastroscopy, this finding must be given special consideration before undertaking examination.

2. Diseases of the mediastinum, such as tumor or aneurysm, contraindicate passage of the gastroscope.

3. Acute febrile conditions, especially those designated "acute abdomen," and acute conditions of the stomach, such as acute or phlegmonous gastritis, contraindicate the examination.

4. Conditions which may make the examination undesirable, difficult, or impossible to complete include severe kyphosis or deformity of the dorsal spine, congestive heart failure, dyspnea or orthopnea from causes other than congestive heart failure, and lack of cooperation from the patient.

Age is not necessarily a contraindication. Successful examinations have been performed on patients in the eighth and ninth decades. On the other hand, I have not found it necessary to examine children under fifteen years of age and hence do not have a special small gastroscope.

The chief limitation of gastroscopy is the inability to visualize the entire stomach.<sup>3</sup> Blind spots include an area on the greater curvature at the tip of the instrument, a strip of the posterior wall underlying the instrument, the uppermost part of the lesser curvature, and a part of the fornix above the cardia. At times the lesser curvature of the antrum and the pylorus cannot be seen. These blind areas vary in incidence and size with every subject, and there is no way to predict from the roentgenogram or other observations whether an area will be seen through the gastroscope.

The chief indications for gastroscopy are (1) negative roentgenologic examination when gastric disease is suspected and (2) abnormal but indeterminate or inconclusive roentgenologic findings. Gastroscopy is also of value in the study of (3) gastric ulcer, (4) malignant lesions, and (5) obscure symptoms or uncommon diseases of the stomach.

The principal value of gastroscopy is in the diagnosis of gastritis. With rare exceptions gastroscopy is the only clinical means for establishing this diagnosis. Although the true significance of the mucosal

changes noted gastroscopically has not been definitely settled, chronic gastritis undoubtedly is a definite entity, which at times produces severe symptoms. A small percentage of cases of unexplained massive hemorrhage from the upper gastrointestinal tract have been shown to be chronic gastritis. Many publications have dealt with the incidence and symptomatology of gastritis, but the preliminary report of Montgomery and others<sup>4</sup> appears to be the beginning of one of the most comprehensive studies yet attempted. In a small series they found that 50 per cent of the patients without demonstrable evidence of peptic ulcer suffered from some degree of gastritis.

My experience at the Clinic indicates that gastroscopy is of major clinical value as the only or principal means of establishing the diagnosis in 25 per cent of all cases examined. The diagnosis in most of the cases comprising this 25 per cent was chronic gastritis. However, a significant number of gastric ulcers which had not been detected roentgenologically were found by gastroscopy. Also the diagnosis of a significant number of doubtful cases of benign and malignant ulcers and tumors was definitely established by gastroscopy.

In the study of gastric ulcer adequate roentgenologic examination usually reveals conclusive evidence of the benignancy or malignancy of the lesion and the progress or healing of the ulcer. However, in a fair number of questionable cases of gastric ulcer the gastroenterologist by means of gastroscopy is able to establish the true diagnosis or lend invaluable aid. Gastroscopy has a similar value in the study and diagnosis of gastric tumor. The operability of a malignant neoplasm often can be better determined by a combination of roentgenoscopy and gastroscopy than by the former alone.

The study of obscure symptoms is greatly aided by gastroscopy. As shown by Montgomery and others<sup>4</sup> a diagnosis of psychoneurosis is not justified without the use of gastroscopy in the differential diagnosis. The relation of obscure symptoms to gastrointestinal allergy and chronic dermatoses is being studied.

#### SUMMARY

Gastroscopy is an office procedure. Contraindications for examination are chiefly diseases of the esophagus or mediastinum. Limitations are few, the main one being the "blind areas," which vary in size. Gastroscopy is of value and is indicated (1) in further study of patients

## GASTROSCOPY

with negative roentgenologic findings in whom gastric disease is suspected, (2) for classification of many cases with indeterminate, suspicious, or inconclusive roentgenologic findings, and (3) for elucidation of certain obscure conditions such as unexplained gross hemorrhage and gastrointestinal allergy.

Gastroscopy in combination with roentgenoscopy and study of gastric content removed by fractional method of gastric analysis has made the diagnosis of organic disease of the stomach comparatively simple. The diagnostic study of many patients cannot be considered adequate and complete without gastroscopy. When indicated, gastroscopy provides convincing evidence of its diagnostic value.

### REFERENCES

1. Bockus, Henry L.: *Gastroenterology* (Philadelphia: Saunders, 1943) vol. 1, p. 235.
2. Schindler, Rudolf: *Gastroscopy* (Chicago: University of Chicago Press, 1937).
3. Renshaw, R. J. F., Clark, G. E., and Forsythe, J. R.: Critical analysis of 938 gastroscopic examinations. *Am. J. Digest. Dis.* 9:401 (December) 1942.
4. Montgomery, H., Schindler, R., Underdahl, L. O., Butt, H. R., and Waters, Waltman: Peptic ulcer, gastritis, and psychoneurosis among naval personnel suffering from dyspepsia. *J.A.M.A.* 125:890 (July 29) 1944.

## CYSTOSCOPY

CHARLES C. HIGGINS, M.D.

In 1805 Bozzani of Frankfort devised an instrument that for the first time permitted visualization of the male urethra. This was the first of three contributions that established principles upon which all later cystoscopes were constructed. In 1883, three years after the invention of the incandescent light by Edison, Newman of Glasgow applied this new source of light to the cystoscope. Boisseau du Rocher, however, is credited with inventing the incandescent light cystoscope with the direct view and megaloscopic optical arrangement.

At the beginning of the twentieth century American workers directed their attention to improvement of the cystoscope. The Kelly indirect endoscope was perfected by Reinhold Wappler and Otis. In 1904 Lewis introduced the operating cystoscope, which permitted transurethral treatment of various pathologic lesions in the bladder. Accessory instruments included forceps, scissors, dilators, and extractors.

The classification of cystoscopes is according to the lens system. Nontelescopic instruments are based on the principle of direct vision through a simple tube, and magnification by lenses is not used. Tele-