

THE CLINICAL PICTURE

PAUL J. WIRTH

Department of Dermatopathology,
Buffalo Medical Group,
Williamsville, NY

THOMAS N. HELM, MD

Department of Dermatopathology,
Buffalo Medical Group,
Williamsville, NY

The Clinical Picture

A rapidly growing crusted nodule on the lip

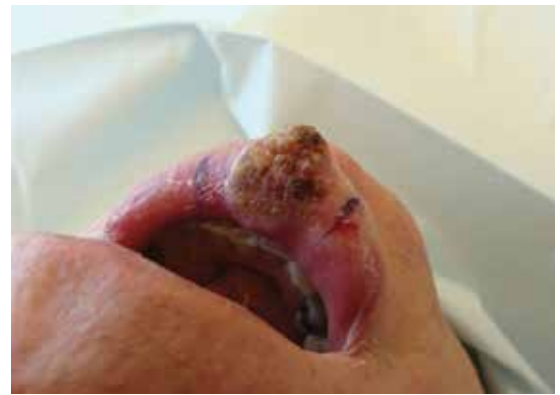
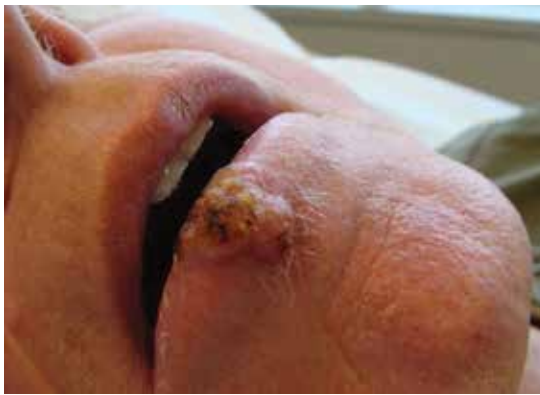
FIGURE 1. The lesion was crusted and indurated. The view on the right shows the markings for the planned surgical removal.

The patient chose Mohs surgery, which resulted in excellent cosmetic and functional outcome

A 76-YEAR-OLD MAN presented with a rapidly growing, indurated, crusted nodule on his lower lip (**FIGURE 1**). This combination—a rapidly growing nodule on a sun-exposed surface in an older patient—pointed to a diagnosis of squamous cell carcinoma, and biopsy study of the affected area confirmed this diagnosis (**FIGURE 2**). Clinical examination, computed tomography, and ultrasonography of the neck revealed no lymph node involvement; the tumor was staged as T2N0M0. Mohs microscopically controlled surgery was performed to remove the tumor with clear margins, and the patient has done well.

DIFFERENTIAL DIAGNOSIS

Malignant melanoma, Merkel cell carcinoma, and deep fungal infection can also cause a rapidly growing crusted nodule on the lower lip, but this typically is not an initial presentation for these conditions.

doi:10.3949/ccjm.80a.12050

Malignant melanoma

Malignant melanoma should be considered for any rapidly growing cutaneous tumor, especially on sun-damaged skin. Most melanoma lesions have variations in pigment and may contain shades of blue, brown, red, pink, and white. Amelanotic melanomas may mimic squamous cell carcinomas, but the histologic features of atypical keratinocytes in this patient ruled out that diagnosis. Biopsy of amelanotic melanoma reveals nests of melanocytes, usually associated with an in situ component in the overlying epithelium.

Merkel cell carcinoma

Merkel cell carcinoma can mimic squamous cell carcinoma or can even arise in association with squamous cell carcinoma. Histologic examination allows for differentiation. In difficult cases, cytokeratin staining with cytokeratin 20 and CAM 5.2 can clarify the diagnosis, because Merkel cell carcinomas exhibit a characteristic paranuclear dot-like pattern not evident in squamous cell carcinoma.

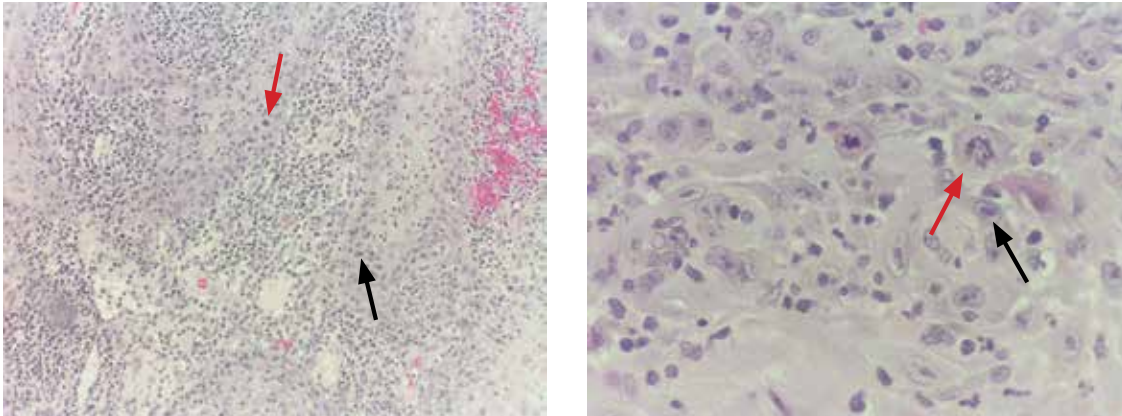


FIGURE 2. Histologic examination (left) revealed keratinocytes with enlarged and pleomorphic nuclei (black arrow). Atypical mitotic figures were also noted (red arrow) (hematoxylin and eosin, $\times 200$). The high-power view (right) also shows enlarged and pleomorphic nuclei (black arrow) and atypical mitotic figures (red arrow) (hematoxylin and eosin, $\times 400$).

Deep fungal infection

Colonization by *Candida* organisms was noted within the overlying crust in this patient's lesion, but fungal organisms were not noted in the epidermis or dermis. Pseudoepitheliomatous hyperplasia can be prominent in deep fungal infection, but the marked cytologic atypia in this case excluded deep fungal infection.

Mucosal neuroma

Mucosal neuromas are typically smooth-surfaced, soft lesions on the lip. They may be associated with multiple endocrine neoplasia syndromes. Biopsy study reveals that they are composed of delicate spindle cells that lack atypia.

■ SQUAMOUS CELL CARCINOMA

Squamous cell carcinoma is one of the most common types of nonmelanoma skin cancer and is associated with increased sun exposure and light skin pigmentation.¹ Unlike basal cell carcinoma, squamous cell carcinoma has a considerable potential to metastasize.²⁻⁴ The current cancer staging manual of the American Joint Commission on Cancer reflects recent evidence-based information on staging and prognosis.⁵⁻⁷ Squamous cell carcinoma of the lip carries an increased risk of metastasis,⁸ and an increase in the number or the size of involved lymph nodes carries a worse prognosis.⁹

The lower lip is most commonly involved because of increased sun exposure. The most common route for the spread of squamous cell

carcinoma of the head and neck is via lymphatics, so careful evaluation of the head and neck is indicated.¹⁰

■ STAGING OUR PATIENT'S LESION

Current staging of cutaneous squamous cell carcinoma takes into account a variety of different features. Our patient's tumor was not associated with invasion of the maxilla, mandible, orbit, or temporal bone. This alone would have qualified the tumor as a T1 lesion, but its size of 3 cm indicated a higher risk and qualified it as a T2 lesion.

The histologic features of our patient's lesion also indicate higher risk according to the current staging system.⁵ The Breslow thickness on histologic examination (measured from the granular cell layer of the epidermis to the deepest portion of the tumor) was 4 mm and the Clark's level was IV (extension to the reticular dermis). The high-risk features and the location on the lip warrant a classification as T2 and carry a worse prognosis.

Wedge excision of the lower lip and Mohs surgery are accepted treatment options. The patient chose Mohs surgery and has done well, with excellent cosmetic and functional outcome. Radiation therapy can be useful as an adjuvant when lymph nodes are involved,¹¹ but this was not necessary in our patient. Careful long-term follow up is warranted, as these patients are at higher risk of developing other, separate tumors. ■

Squamous cell carcinoma has a considerable potential to metastasize

REFERENCES

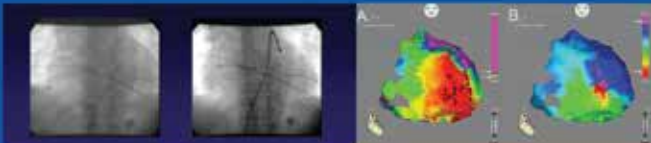
1. **Schwartz RA.** Squamous cell carcinoma. In: Schwartz RA, editor. *Skin Cancer: Recognition and Management*, 2nd ed. Malden, MA: Blackwell Publishing; 2008:47–65.
2. **D'Souza J, Clark J.** Management of the neck in metastatic cutaneous squamous cell carcinoma of the head and neck. *Curr Opin Otolaryngol Head Neck Surg* 2011; 19:99–105.
3. **Zbar RI, Canady JW.** MOC-PSSM CME article: Nonmelanoma facial skin malignancy. *Plast Reconstr Surg* 2008; 121(suppl 1):1–9.
4. **Morselli P, Masciotra L, Pinto V, Zollino I, Brunelli G, Carinci F.** Clinical parameters in T1N0M0 lower lip squamous cell carcinoma. *J Craniofac Surg* 2007; 18:1079–1082.
5. **American Joint Commission on Cancer.** *Cancer Staging Manual*. 7th ed. <http://www.cancerstaging.org>. Accessed February 3, 2013.
6. **Lardaro T, Shea SM, Sharfman W, Liégeois N, Sober AJ.** Improvements in the staging of cutaneous squamous-cell carcinoma in the 7th edition of the AJCC Cancer Staging Manual. *Ann Surg Oncol* 2010; 17:1979–1980.
7. **Cutaneous squamous cell carcinoma and other cutaneous carcinomas.** In: Edge SB, Byrd DR, Compton CC, Fritz AG, Greene FL, Trotti A, editors. *AJCC Cancer Staging Manual*. 7th ed. New York, NY: Springer; 2010:301–314.
8. **Frierson HF Jr, Cooper PH.** Prognostic factors in squamous cell carcinoma of the lower lip. *Hum Pathol* 1986; 17:346–354.
9. **Civantos FJ, Moffat FL, Goodwin WJ.** Lymphatic mapping and sentinel lymphadenectomy for 106 head and neck lesions: contrasts between oral cavity and cutaneous malignancy. *Laryngoscope* 2006; 112(3 Pt 2 suppl 109):1–15.
10. **Rowe DE, Carroll RJ, Day CL Jr.** Prognostic factors for local recurrence, metastasis, and survival rates in squamous cell carcinoma of the skin, ear, and lip. Implications for treatment modality selection. *J Am Acad Dermatol* 1992; 26:976–990.
11. **Veness MJ, Palme CE, Smith M, Cakir B, Morgan GJ, Kalnins I.** Cutaneous head and neck squamous cell carcinoma metastatic to cervical lymph nodes (nonparotid): a better outcome with surgery and adjuvant radiotherapy. *Laryngoscope* 2003; 113:1827–1833.

ADDRESS: Thomas N. Helm MD, Department of Dermatopathology, Buffalo Medical Group, 6225 Sheridan Drive, Suite 208, Building B, Williamsville, NY 14221; e-mail: thelm@buffalomedicalgroup.com.



Heart Rhythm Society 2013 – Satellite Symposium
4th Annual Symposium on
Interventional Pericardiology

Tuesday, May 7, 2013 • 1:30 – 7:00 pm
Hyatt Regency Denver at Colorado Convention Center
Centennial Ballroom, A, B • Denver, CO



Register Today! ccfcme.org/3pericardio13
Registration is Complimentary – Reception Included

Plan to attend this symposium that will focus on current approaches to pericardial interventions as they pertain to cardiac electrophysiology.

Featuring these presentations:

- Anatomy and Fluoroscopic Landmarks Relevant to the Pericardial Space
- Pericardial Access and Complications
- Ablation in the Pericardium: How is it Different and How Can Collateral Damage Be Prevented?
- Epicardial Ablation in Nonischemic Cardiomyopathy
- Case Presentation on Epicardial VT in Ischemic Cardiomyopathy
- Unusual Utility of the Pericardial Space in Electrophysiology Procedures
- Case Presentations on My Best and Worst Experience in the Epicardial Space

This program is not part of the Heart Rhythm 2013, 34th Annual Scientific Sessions, as planned by the Heart Rhythm Society Scientific Sessions Program Committee. This event is neither sponsored by nor endorsed by the Heart Rhythm Society.