GROSS INTRAVENOUS EXTENSION OF CARCINOMA OF THE LUNG

A Preliminary Report

LAWRENCE J. McCORMACK, M.D.,
Department of Anatomic Pathology

GEORGE L. HOFFMANN, M.D.,*
Department of General Surgery

LAURENCE K. GROVES, M.D., and DONALD B. EFFLER, M.D.
Department of Thoracic Surgery

THE search for findings of prognostic significance at the time of operation for neoplastic disease is a continuous one. One such finding is that of venous invasion by a malignant tumor. In specimens of cancer of the colon such a demonstration is limited to microscopic evidence, as the invaded veins are too small for gross dissection. Conversely, in specimens of renal carcinoma, the large size of the veins facilitates gross examination for neoplastic invasion. The veins in specimens of carcinoma of the lung also are of a size to permit gross examination, yet no record of such an examination has been found, although the possibility of carcinoma of the lung invading the veins has often been mentioned.

Initially, one of us (L. J. M.), while making a survey of the occurrence of neoplastic cells in blood draining from pulmonary neoplasms, noted a frequency of venous invasion by such tumors.[1] Although our case material is too recent for us to be able to make an adequate statistical evaluation in regard to survival of patients, we have sufficient pathologic data to report the immediate findings.

Material and Methods

Between January 1, 1953, and October 1, 1955, 345 patients with bronchogenic carcinoma were examined at the Cleveland Clinic. Some form of pulmonary resection was later performed in 79 of those patients, 48 of whom underwent pneumonectomy and 31 of whom were treated with lobectomy.

The unfixed surgical specimens were examined using a technic different from the usual pathologic procedure. Instead of initially opening the bronchi to expose the neoplasm, the major pulmonary veins first were longitudinally opened. The surgeon had left long ligatures on the veins to facilitate their positive identification. This was necessary, as carcinoma of the lung occasionally also invades the large pulmonary arteries, as had occurred in two of the 79 specimens in this series. After the veins were opened they were carefully

Formerly Chief Surgical Fellow; present address: Mesa, Arizona.

searched for a protruding thrombus (Fig. 1). This evidence of neoplastic invasion was noted in the region of the tumor, often recurring at points of union of the smaller venous tributaries. Those specimens showing only narrowing of the lumen of a vein by impingement of extraluminal tumor were not included in the group considered to be positively invaded.

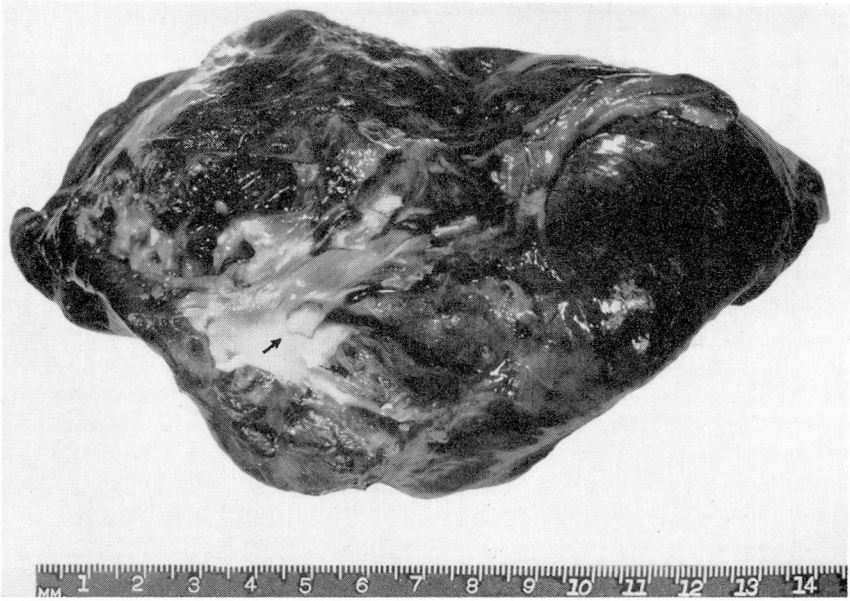

Fig. 1. Gross neoplastic invasion of pulmonary vein. The pulmonary vein has been opened longitudinally to show the protuberant mass (arrow).

The size of the intravascular neoplasm ranged from a mass 0.3 cm. long to one that completely occluded the major vein and extended into the left atrium. A microscopic section of every neoplastic thrombus was made to establish positively whether the tumor had or had not actually invaded the venous wall and formed the intravascular mass (Fig. 2).

Findings

Demonstrable gross intravascular extension was present in the surgical specimens of 19 of the 79 patients. Seventeen of these patients were available for survival studies; one patient died in the early postoperative period and one patient was lost to follow-up. The cell types of neoplasm in this group were squamous-cell carcinoma, 12 specimens; adenocarcinoma, two specimens; and undifferentiated carcinoma, three specimens. An associated hilar lymph-node involvement was present in seven patients. Postoperatively, eight of the 17 patients were still living and well for periods of from 17 to 48 months; the others

Fig. 2. Photomicrograph showing mass of neoplasm protruding into lumen of vein. Hematoxylin-eosin and methylene blue stain; x 9.

had died. A postoperative follow-up of three or more years was possible for 10 of these 17 patients. Only two of these 10 patients survived for three or more years; one of these survivors had intravenous extension en masse into the left atrium.

The surgical specimens of 60 patients showed no evidence of gross intravenous extension; 53 of these patients were followed, as six died in the immediately postoperative period and one was lost to follow-up. The neoplastic cell types in this group were squamous-cell carcinoma, 23 specimens; adenocarcinoma, 20 specimens; undifferentiated carcinoma, eight specimens; and small-cell carcinoma, two specimens. There was an associated lymph-node involvement in 30 of the 53 patients. Of the 53 patients, 23 were living and well for periods from 17 to 49 months after operation; 14 of the 22 survived three or more years postoperatively. This is in contrast to two of 10 patients so surviving who had intravenous extension of tumor.

Although the series at this time is too limited for statistical evaluation, it may be noted that among the 17 patients with squamous-cell carcinoma traced three years or more, six of nine having no gross intravenous extension survived in comparison with two of eight who had venous neoplastic invasion.

Summary

1. Evidence of gross intravenous extension was found on pathologic examination of 19 of 79 surgically resected specimens of carcinoma of the lung.

2. Only two of 10 patients with intravenous extension survived three years or more in contrast to 14 surviving among 22 patients without such venous invasion by tumor.

3. The data suggest that in the absence of gross neoplastic invasion of the pulmonary veins, the survival rate is higher than when such invasion is demonstrable.

Reference

1. McCormack, L. J.; Hazard, J. B.; Turnbull, R. B., Jr., and Belovich, Doris: Tumor cells in venous drainage of malignant neoplasms. Trans. Intersociety Cytology Council, Third Annual Meeting, Cleveland, Ohio, Nov. 11-12, 1955, pp. 111-115.