

Abstract 4

Brain MRI Correlates of Atrial Fibrillation

Stephen E. Jones, MD, PhD;¹ Thomas Callahan, MD;² Kamal Chémali, MD;³ Michael Phillips, MD;¹ David Van Wagoner, PhD;² and Walid Saliba, MD²

¹Department of Neuroradiology, ²Department of Cardiovascular Medicine, and ³Department of Neurology, Cleveland Clinic, Cleveland, OH

While the influence of the central nervous system on cardiac rhythm and function is well accepted, the mechanisms of this control are poorly understood. A preponderance of data implicates the autonomic nervous system in the development of many cases of atrial fibrillation (AF), for which new therapies are needed since both surgical and minimally invasive ablative techniques have substantial failure rates and complications. Efforts to better understand the role of the central nervous system in AF may lead to new treatment strategies that improve outcomes and reduce complications associated with available therapies.

Recently developed functional magnetic resonance imaging (fMRI) techniques make it possible to simultaneously image brain

anatomy and assess patterns of regional activation and function. By using specific tasks to cause autonomic activation in subjects and recording heart rate variation, blood pressure variation, and galvanic skin response as independent measures of autonomic arousal, studies have compared these measures to fMRI to determine regions of the brain that are active during sympathetic or parasympathetic arousal (Figure 1, previous page). These studies have identified activation within the anterior cingulate region and insular cortex during sympathetic activation, and in the insular cortex during parasympathetic activation.

Our long-range goal is to determine the relationship between levels of autonomic activation and the development of AF. The central hypothesis of this study is that patients with AF will have diminished central autonomic activation as assessed by fMRI and pupillometry that will persist despite cardioversion to sinus rhythm.

The techniques to measure autonomic tone on subjects while acquiring fMRI data are difficult and subject to patient movements, paradigm selection, and noise pickups. We will present initial results from these techniques on healthy subjects, prior to initiating imaging on AF patients both before and after ablation.

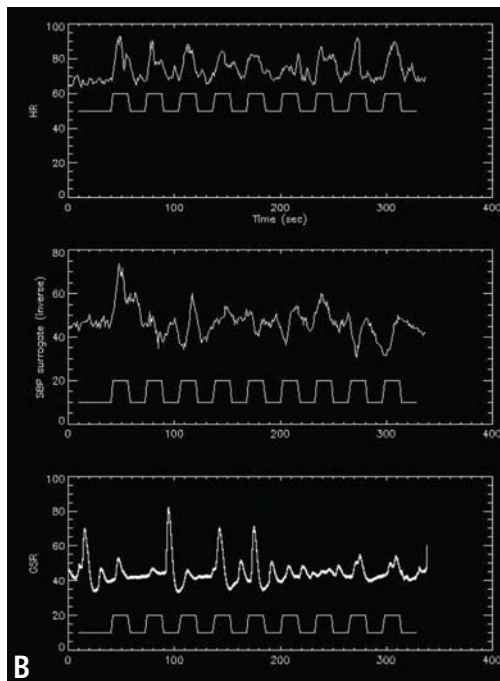
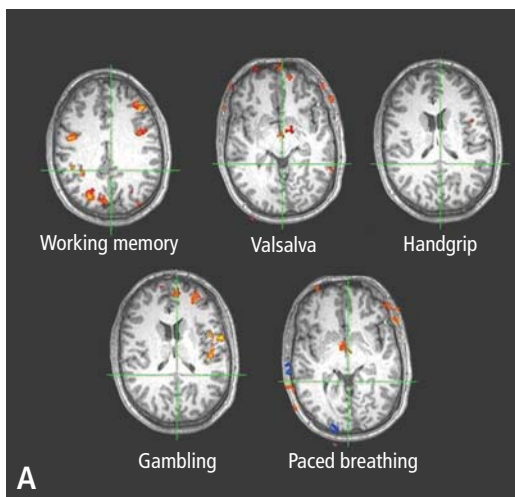


FIGURE 1. (A) Examples of functional magnetic resonance imaging (fMRI) activation obtained in a healthy subject performing five task paradigms designed to alter autonomic tone. **(B)** Example of noninvasive autonomic recordings obtained from a healthy subject while performing a handgrip task during MRI. Measures are heart rate, systolic blood pressure surrogate, and galvanic skin response.

* BHBI = Bakken Heart-Brain Institute