

# Evaluation of acute right upper quadrant pain<sup>1</sup>

Edward Buonocore, M.D.  
James O'Donnell, M.D.  
Jerome A. Adell, B.S., R.T., R.D.M.S.

Sudden onset of pain in the right upper quadrant of the abdomen requires rapid medical decision-making and prompt care. Recent innovations in diagnostic imaging offer new means of making accurate and rapid diagnoses as illustrated in the following case report.

A 51-year-old white man was admitted to The Cleveland Clinic Hospital with a complex array of clinical findings including right-sided paresis, cough, and hypotension. Maxillary sinusitis and parenchymal pulmonary abnormalities were identified and eventually diagnosed as Wegener's granulomatosis by histologic examination. He was given immunosuppressant and steroid therapy.

Several months after the start of therapy, the patient became desperately ill and experienced nausea and pain in the right upper quadrant of the abdomen. Tenderness and guarding were elicited by palpation over the right hypochondrium and epigastrium. Preliminary clinical impression was acute cholecystitis, and an ultrasonic examination of the gallbladder was obtained (*Fig. 1*). An unusual 12 × 6 × 5-cm dense echogenic mass was seen within a dilated gallbladder lumen. The gallbladder wall had thickened to 5 mm. The echogenic density layered along the inferior gallbladder lumen, and no acoustic shadowing was identified. Ultrasonic diagnosis was empyema of the gallbladder. Other diagnoses considered were gallbladder neoplasm,

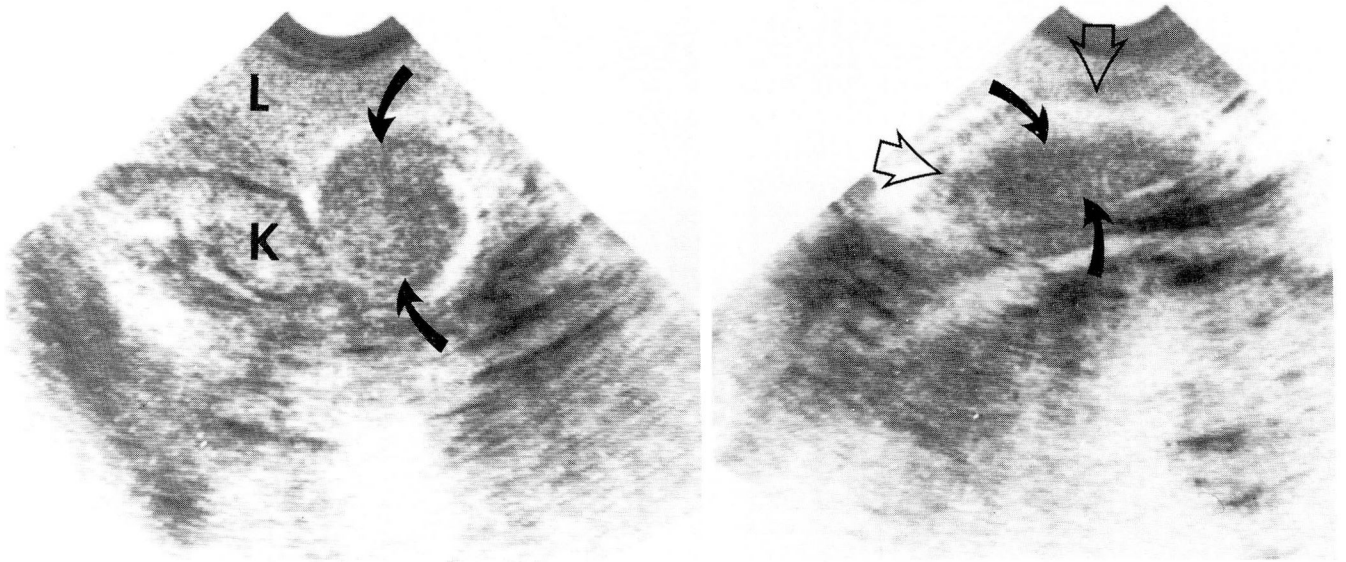
infarction, and hemorrhage. The patient was promptly transferred to the Nuclear Medicine Department for functional evaluation of the hepatobiliary system.

After intravenous injection of 5 mCi of <sup>99m</sup>Tc-labeled diisopropyl IDA (DISIDA), serial anterior images were obtained. There was good hepatic uptake, visualization of the intrahepatic and extrahepatic biliary systems, and excretion into the small bowel within one hour. The gallbladder was not visualized at any time (*Fig. 2*). In the acute clinical setting, this scintigraphic pattern correlates highly (97% accuracy) with an acute obstruction of the cystic duct.<sup>1</sup> Besides acute cholecystitis, however, the differential diagnosis could include atypical chronic cholecystitis or a false-positive reading due to hyperalimentation or non-fasting state.

At this point in the course of this medical problem: (1) Would you do any further diagnostic testing? (2) What therapeutic measure would you next employ?

No further diagnostic tests were considered necessary. Because of the findings from ultrasonic and nuclear scans, the patient was taken to surgery the next day for cholecystectomy with a provisional diagnosis of acute cholecystitis and possible empyema of the gallbladder. At surgery, the gallbladder and portions of the cecum and ascending colon were resected. The gallbladder mucosa was hemorrhagic and ulcerated; the gallbladder contained hemorrhagic fluid and a 7 × 5 × 5 × 1.5-cm reddish mass. On microscopic examination, the mass was found to be a fungus

<sup>1</sup> Departments of Radiology (E. B., J. A. A.), and Nuclear Medicine (J. O.), The Cleveland Clinic Foundation. Submitted for publication 7 March 1983; accepted 23 March 1983.



**Figure 1. A.** Transverse sector ultrasonogram, right upper quadrant of the abdomen. A large echogenic mass is seen in the center of the gallbladder (curved arrows) (*L* = left lobe of liver; *K* = kidney).  
**B.** Sagittal section demonstrating echogenic mass within the gallbladder with a thickened wall. Open arrows indicate thick wall of the gallbladder and the curved arrows delineate the echogenic mass settling in the dependent portion of the gallbladder.

ball containing *Candida* mycelia. Sections of the gallbladder and colonic wall were found to have invasive candidiasis.

**Discussion**

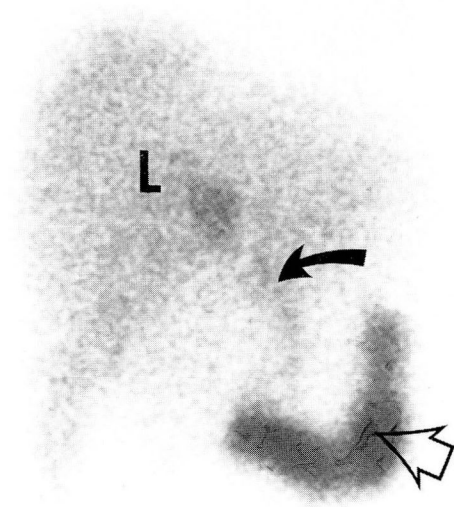
Ultrasonography and nuclear imaging are currently the most direct methods of diagnosing

gallbladder disease. These techniques have virtually displaced the older radiographic methods utilizing oral cholographic contrast media.

Cholelithiasis and intrahepatic and extrahepatic duct size calculations are ideally suited to ultrasonic techniques. When proper criteria are employed, the detection of gallstones by ultrasonography is virtually 100%. These diagnostic findings include the presence of an echogenic density, acoustical shadowing of the ultrasonic beam, and motion of the density when the patient's position is changed.<sup>2,3</sup>

Diagnosis of extrabiliary tract obstruction is 90% accurate, whereas the exact cause of biliary tract obstruction is determined in only approximately 50% of cases.<sup>4</sup> Despite these claims, the glaring deficiency of ultrasonography is its inability to diagnose acute cholecystitis. There are no specific ultrasonic criteria for this diagnosis. Thickness of the gallbladder wall, lumen size, and elicitation of tenderness when compressing the gallbladder by the ultrasonic transducer are nonspecific findings for acute cholecystitis and are inadequate for its diagnosis.

On the other hand, radionuclide cholescintigraphy does provide a rapid and accurate method for the detection of acute cystic duct obstruction. If delayed images are obtained up to 4 hours after tracer injection to allow for late gallbladder visualization in some patients with chronic cho-



**Figure 2.** Scan of the right upper quadrant, one hour after intravenous injection of DISIDA. Curved arrow indicates common bile duct, and the open arrow the isotopic activity within the small intestine (*L* = liver).

lecystitis, biliary tract patency studies with  $^{99m}\text{Tc}$  DISIDA are 97% sensitive and 95% specific for acute calculous cholecystitis.<sup>5</sup>

Additional applications of this tracer technique include postoperative evaluation for bile leaks or postcholecystectomy syndrome, detection of enterogastric reflux, and the differentiation of medical versus surgical cholestasis. Studies employing  $^{99m}\text{Tc}$  DISIDA remain diagnostic despite serum bilirubin levels up to 30 mg/100 ml.<sup>6</sup>

In summary, in the medical management of the patient complaining of right upper quadrant pain, the preliminary evaluation should include ultrasonography for the detection of cholelithiasis and the evaluation of ductal size, and radionuclide scans for the diagnosis of cystic duct obstruction and acute cholecystitis. Together these modalities, in the proper clinical setting, are diagnostic of acute and chronic gallbladder disease.

The colonization of the gallbladder and colon by *Candida* is explained by the altered immune state in this patient. Fungus infestation, although frequently reported in pulmonary cavities, is exceedingly rare in the gallbladder. The rapid pro-

gression and invasiveness of *Candida* are attributed to the debilitated medical status of this patient. The echogenic character of the gallbladder contents without acoustic shadowing was sufficient to discount the diagnosis of calculi. Gallbladder neoplasms, abscess, and hemorrhage are more likely to present with this ultrasonic pattern. The patient's clinical status and these laboratory findings warranted immediate surgical attention.

## References

1. Freitas JE: Cholescintigraphy in acute and chronic cholecystitis. *Semin Nucl Med* 1982; **12**:18-25.
2. Leopold GR, Amberg J, Gosink BB, Mittelstaedt C. Gray scale ultrasonic cholecystography: a comparison with conventional radiographic techniques. *Radiology* 1976; **121**:445-448.
3. Krook PM, Allen FH, Bush WH Jr, Malmer G, MacLean MD: Comparison of real-time cholecystosonography and oral cholecystography. *Radiology* 1980; **135**:145-148.
4. Goldberg BB, Harris K, Broecker W. Ultrasonic and radiographic cholecystography. *Radiology* 1974; **111**:405-409.
5. Weissmann HS, Badia J, Sugarman LA, Klüger L, Rosenblatt R, Freeman LM. Spectrum of  $^{99m}\text{Tc}$ -IDA cholescintigraphic patterns in acute cholecystitis. *Radiology* 1981; **138**:167-175.
6. Weissmann HS, Rosenblatt R, Sugarman LA, Freeman LM. An update in radionuclide imaging in the diagnosis of cholecystitis. *JAMA* 1981; **246**:1354-1357.