THE MESENTERIC VASCULAR PEDICLE

Review of Its Clinical Uses and Report of Experiments in Dogs

JAMES G. DILLER, M.D.,* SHATTUCK W. HARTWELL, JR., M.D.,

AND

ROBIN ANDERSON, M.D.

Department of Plastic Surgery

SEGMENTS of small intestine have been used in humans for reconstruction or replacement of other organs both intra- and extra-abdominal in location. This paper presents a résumé of the various ways in which such segments have been employed and reports our own experimental use of them in dogs.

Bowel Segment as a Pedicled Graft

The mesenteric vascular pedicle has been used intraabdominally in the urologic, the gastrointestinal, the gynecologic, and the plastic branches of surgery. Von Mikulicz, in 1898, used a segment of intestine to enlarge the urinary bladder, and in 1909 Shoemaker reported the use of an ileal pouch as a substitute for a tuberculous bladder.[1] Intestinal segments have been used to enlarge a contracted bladder such as Scheele's loop anastomosis (1922) and Tasker's patch (1953).[1] This type of procedure was termed ileocystoplasty. Replacement of a ureter by an ileal segment was reported by Longuet[2] in 1948. Bricker[3] in 1950 reported the satisfactory use of the ileal segment as a total substitute for the bladder, implanting ureters as an end-to-side procedure with the open end of the ileum as an abdominal cutaneous ileostomy. Bricker[3] refined the technics conceived and carried out by Verhoogen in 1908.

As a replacement for the stomach after total gastrectomy Lee[4] interposed terminal ileum and a segment of the right colon on its vascular pedicle between the distal portion of the esophagus and the duodenum. The ileocecal valve served as a replacement of the esophagogastric sphincter.

An ileal segment within the abdomen has been used for the absorption of ascites. In a procedure called ileo-entectropy, Neumann and Richman[5] maintained the ileal segment on its vascular pedicle and opened the intestine. With the serosal surface attached to the parietal peritoneum, the exposed mucosal surface was bathed by ascitic fluid. This operation was ef-

* *Formerly member of the associate staff, Department of Plastic Surgery; present address: Toledo Clinic, 2001 Collingwood Boulevard, Toledo, Ohio 43620.*

fective in removing ascitic fluid from a few cirrhotic patients. Construction of a vagina with a transplanted ileal segment was reported by Baldwin[6] in 1904.

The experience of removing ascites by ileo-entectropy led Neumann, Hoen, and Davis[7] to consider its application to congenital communicating hydrocephalus. They moved the ileal segment on its vascular pedicle through the lumbar musculature to a dorsolateral subcutaneous position. After repeated confirmation of sterility within the lumen of the isolated segment, they established a fistula between the subarachnoid space at the level of the fourth lumbar vertebra and the blind ileal pouch. This procedure proved effective in relieving the increased cerebrospinal fluid pressure in a seven-month-old infant. This work does not seem to have been repeated.

A portion of the right colon is used to replace esophagus[8] in a construction similar to that in Lee's[4] procedure for replacement of the stomach. The length of the vascular arcade along the mesenteric border of this portion of the colon is adequate for full thoracic esophageal substitution.

The mesenteric pedicle has also been used in bringing about myocardial revascularization in dogs. Key, Kergin, Martineau, and Leckey[9] employed jejunum on a mesenteric pedicle to augment the coronary artery circulation. The intestinal segment was opened, stripped of the mucosa, and placed flat against the abraded myocardium. In dogs, the survival rate after ligation of the anterior descending coronary artery rose from 26.7 percent in the control animals to 93.1 percent in dogs in whom the myocardium had an additional blood supply from the cardioenteropexy. Direct communication was demonstrated between the superior mesenteric branch and the coronary artery vessels in 18 of 30 hearts.

EXPERIMENTAL STUDY AT CLEVELAND CLINIC

Material and method

(A) *Experiment employing the pedicled bowel as a carrier of a composite graft of skin and subcutaneum.* In each of 10 mongrel dogs weighing less than 18 kg., a short segment of distal ileum was resected, but kept attached to the mesentery and blood supply. Intestinal continuity was reestablished by end-to-end anastomosis, excluding the ileal segment.

A laterally based pedicle flap of skin and subcutaneous tissue was elevated on the abdomen and the excluded ileal segment brought through a small opening in the center of the defect created by lifting the pedicled skin flap from the underlying abdominal wall. The intestinal segment was opened along the antimesenteric border, and the muscularis mucosa and mucosa were removed. The seromuscular layers of the opened intestine were fixed to the abdominal wall and the skin flap was replaced upon the opened bowel



Fig. 1. A mesenteric vascular pedicle courses through an opening on a dog's abdomen. It supplies a composite flap of abdominal skin and subcutis shown here suspended by traction sutures. The abdominal opening is made large enough to permit transfer of the pedicle flap to a new location by reentry to and then reexit from the peritoneal cavity. (See *Figure 3*.) A loop of ileum is also shown lifted from the wound. The mesenteric pedicle came from near this portion of the ileum.

musculature. Two weeks later the fourth side of the rectangular flap was incised—a "delay procedure" before total elevation and transfer of the skin flap on the mesenteric pedicle at three weeks (*Fig. 1*).

(B) *Experiment employing the pedicled bowel as a transplantable blood supply*. In each of seven dogs, the terminal ileum was used to augment coronary artery circulation. In each animal the mucosal tube of an ileal segment was removed intact and the epicardium abraded from the surface of the heart. The flattened, opened, bowel muscle was then opposed to the denuded myocardium (*Fig. 2*). One month later, ligation of the anterior descending coronary artery was performed.

Results

(A) In the 10 dogs, transposition of areas of skin three times the surface of the intestinal vehicle was effected without loss of skin (*Fig. 3*). Hair growth was equal to that of the adjacent skin. Microscopic studies showed the un-

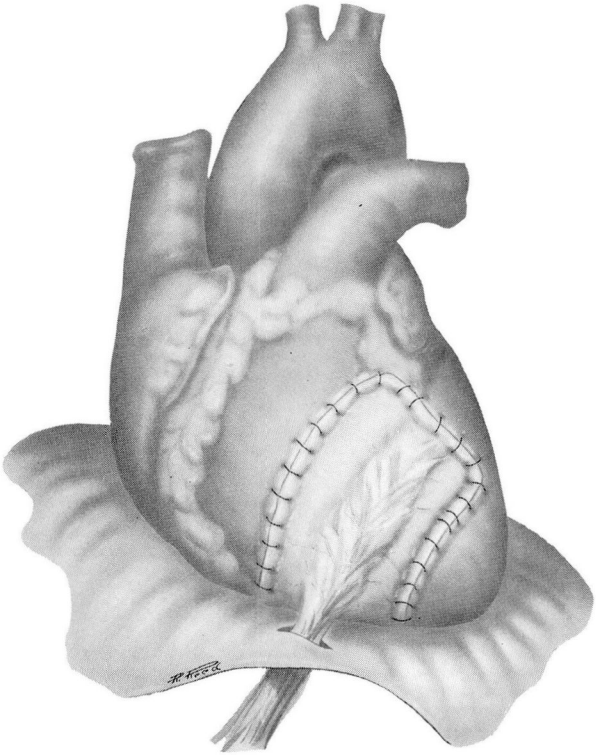

Fig. 2. A drawing of the appearance of the cardioenteropexy. Before suture of the bowel segment to the heart, a nylon bottle brush abraded the epicardial surface.

changed character of the skin appendages, and angiography demonstrated the vascular pattern from mesentery to skin.

(B) In the seven dogs, angiograms confirmed the perfusion of the myocardium by the circumflex and the right coronary arteries.

Eight months later the use of an ameroid,* for closure of the circumflex artery in two dogs, led to death. However, injection of contrast medium in the superior mesenteric artery demonstrated clearly the interarterial communication established between the superior mesenteric artery and the circumflex artery of the coronary arterial system (*Fig. 4*).

COMMENT

The experiments just described employed the transplanted bowel for two purposes: (a) as a carrier of a composite graft of skin and subcutis, and (b)

* *This is a tubular steel semicircle lined with a hydrophilic organic compound that slowly expands in vivo. When placed around a blood vessel, gradual occlusion will occur.* (*See* Figure 4.)

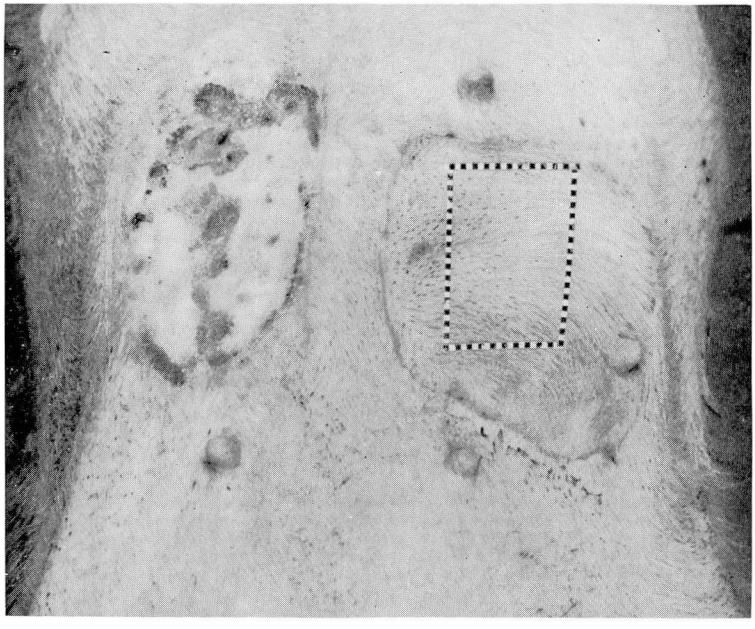

Fig. 3. A composite flap of abdominal skin and subcutis has been transferred on an abdominal pedicle from one side of the dog's belly to the other. Note the nipple in the graft. Dottled lines approximate the area of the underlying bowel surface. The donor site is only partially healed with a split-thickness skin graft.

as a transplantable blood supply. The clinical application of these principles appears to be as extensive as the need for augmented blood supply and new or replacement tissue in medical practice.

With regard to the first purpose, it is clear that if small (less than 2-mm. diameter) blood vessels can be sewn together effectively there will exist a dependable method for transplanting large composite free grafts on a vascular pedicle that is then attached to a vascular system at a new site. Nakayama and associates[10] and Roberts and Douglass[11] have replaced with free ileal segments the cervical esophagus of patients, these small-bowel segments having been nourished in their new location through their proper vascular systems attached by anastomosis to regional arteries and veins. Similarly, in dogs, Krisek, Tani, DesPrez, and Kiehn[12] transplanted abdominal skin and subcutaneous tissue nourished by the inferior superficial epigastric artery. By severing the vascular pedicle the transplantation has become a large free composite graft; but immediate restoration of blood supply that is essential to the life of the graft has been achieved by anastomosis of the pedicle blood supply to a regional artery in a new site. These investigators successfully transplanted abdominal skin on vascular pedicles into the neck.

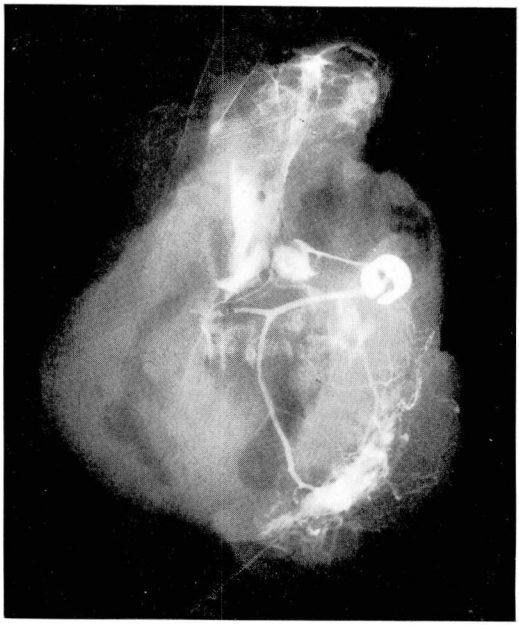

Fig. 4. The postmortem injection (visible beneath the heart shadow) of the mesenteric pedicle of the cardioenteropexy shows distribution of contrast medium into the coronary arterial system. Note the split-ring shadow of the ameroid.

As a carrier of composite skin and subcutis with an isolated vascular system, the preparation we have made allows further study of skin metabolism, wound healing, and of tumoricidal drugs. It is, in essence, a perfusion model in a laboratory animal.

With regard to the second purpose of the experiments, namely to investigate a transplantable blood supply, there is an important consideration. The clinical application, for example, of using a mesenteric pedicle to carry more blood to an ischemic heart, may be hampered by ischemia in the pedicle. Coronary artery disease is often a companion to generalized arterial disease, and the defective arteries in a mesenteric pedicle may scarcely help an ischemic heart. It is clear, however, that an effective blood supply can be transplanted through a mesenteric pedicle.

SUMMARY

A short review of the adaptations of pedicled ileal segments is given. Experiments in dogs show that opened segments of ileum, excluded from the intestinal tract, can serve as carriers of large composite grafts of skin and subcutaneous tissue. Cardiac blood supply may be augmented by attaching the pedicled segment of ileum to the heart.

REFERENCES

1. Pyrah, L. N., and Raper, F. P.: Some uses of an isolated loop of ileum in genito-urinary surgery. Brit. J. Surg. **42:** 337–357, 1955.
2. Longuet, Y. J.: On possibility of replacing segment of pelvic ureter by pedunculated graft of excluded small intestine; (uretero-ileo-cystoplasty). Urol. & Cutan. Rev. **52:** 322–326, 1948.
3. Bricker, E. M.: Bladder substitution after pelvic evisceration. S. Clin. North America **30:** 1511–1521, 1950.
4. Lee, C. M., Jr.: Transposition of a colon segment as a gastric reservoir after total gastrectomy. Surg. Gynec. & Obst. **92:** 456–465, 1951.
5. Neumann, C. G., and Richman, H.: Studies on the mechanisms of the control of ascites by means of ileo-entectropy. Plast. & Reconstruc. Surg. **20:** 379–382, 1957.
6. Baldwin, J. F.: The formation of an artificial vagina by intestinal transplantation. Ann. Surg. **11:** 398–403, 1904.
7. Neumann, C. G.; Hoen, T. I., and Davis, D. A.: The treatment of communicating hydrocephalus by the absorption of cerebrospinal fluid by the mucosa of an isolated segment of ileum (modified ileoentectropy). S. Forum **9:** 705–707, 1959.
8. Groves, L. K., and Turnbull, R. B., Jr.: Right colon used as an esophageal prosthesis; report of five cases. Cleveland Clin. Quart. **28:** 90–104, 1961.
9. Key, J. A.; Kergin, F. G.; Martineau, Y., and Leckey, R. G.: A method of supplementing the coronary circulation by a jejunal pedicle graft. J. Thoracic Surg. **28:** 320–329; discussion 330, 1954.
10. Nakayama, K.; Yamamoto, K.; Tamiya, T.; Makino, H.; Odaka, M.; Ohwada, M., and Takahashi, H.: Experience with free autografts of the bowel with a new venous anastomosis apparatus. Surgery **55:** 796–802, 1964.
11. Roberts, R. E., and Douglass, F. M.: Replacement of the cervical esophagus and hypopharynx by a revascularized free jejunal autograft; report of a case successfully treated. New England J. Med. **264:** 342–344, 1961.
12. Krizek, T. J.; Tani, T.; DesPrez, J. D., and Kiehn, C. L.: Experimental transplantation of composite grafts by microsurgical vascular anastomoses. Plast. & Reconstruc. Surg. **36:** 538–546, 1965.