

THE DIFFERENTIATION OF NONINVASIVE AND INVASIVE CARCINOMA ARISING IN INTESTINAL POLYP

Desmoplastic Tumor Stroma

EDWIN R. FISHER, M.D.*

Department of Pathology

and

RUPERT B. TURNBULL, JR., M.D.

Department of Surgery

ONE of the most perplexing problems confronting the surgical pathologist is the diagnosis of carcinoma in intestinal polyp. It is important to the surgeon that the pathologist not only establish the presence of carcinoma but also the type. Therapy, as outlined in another article,¹ depends upon complete diagnosis, since certain carcinomas arising in polyp may be treated locally without minimizing the chances of cancer cure.

In designating the type of carcinoma arising in polyp, we have used descriptive terms rather than numerical grades (table). Three types are recog-

CARCINOMA ARISING IN POLYP (Colon)

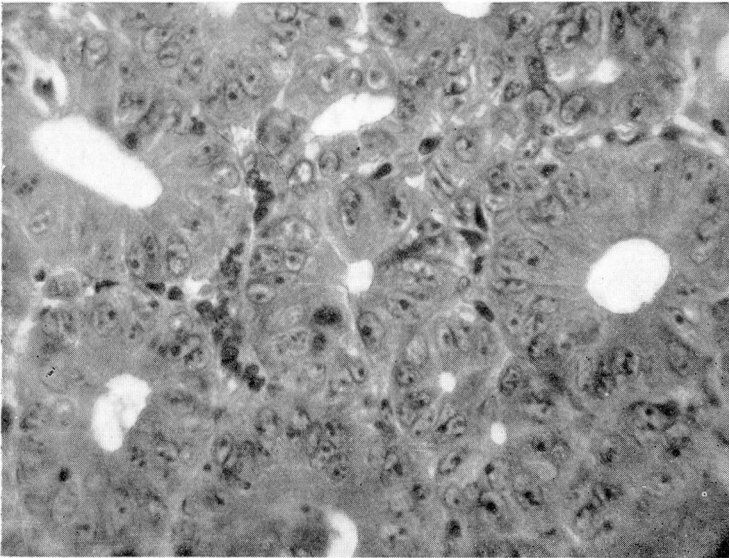
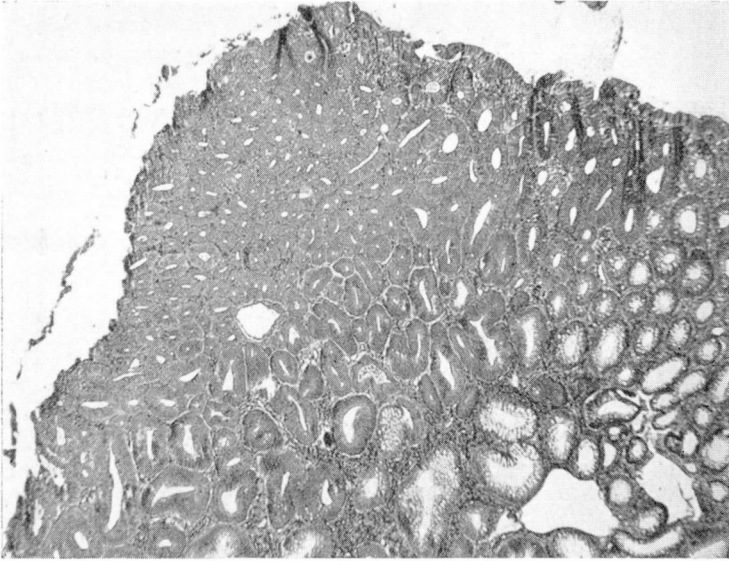
| Type of Carcinoma | Pathologic Characteristics |
|--------------------------------|---|
| Noninvasive | |
| (a) Carcinoma in situ | Cytologic carcinoma without invasion of basement membrane. |
| (b) Superficial adenocarcinoma | Carcinoma with reduplication of lumina and invasion of basement membrane and lamina propria. |
| Invasive | Carcinoma with invasion of <i>mucularis mucosa</i> and presence of desmoplastic tumor stroma. |

*Former member of Assistant Staff. Now located in Bethesda, Md., National Institute of Health.

CARCINOMA ARISING IN POLYP

nized: (1) carcinoma in situ in which there is anaplasia and irregularity of the glandular epithelium without disruption of the basement membrane or invasion of the lamina propria (figs. 1a and b); (2) superficial carcinoma char-

(a)



(b)

FIG. 1. (a) Low power of focus of carcinoma in situ arising at edge of polyp (x50). (b) High power from same area as in 1a. Note atypical cells, macronucleoli, atypical mitoses (x450).

acterized by the changes mentioned previously as well as noticeable reduplication of lumina and the presence of tumor masses lying free in the lamina propria but without invasion of the muscularis mucosa (fig. 2); (3) invasive carcinoma which reveals, in addition, invasion of the muscularis mucosa with access of malignant cells to the lymphatics and vessels of the submucosa of the bowel (fig. 3a). Carcinomas without evidence of benign polyp in their structure are classified as polypoid carcinoma and do not appear in this classification. The differentiation of superficial or noninvasive carcinoma from the invasive type is, at times, difficult since the demonstration of invasion of the muscularis mucosa may be overlooked or misinterpreted because of incomplete sectioning or poor orientation of the sections or because the muscularis mucosa does not appear in the biopsy specimen. The decision for conservative or radical surgery rests upon this differentiation.

A helpful histologic aid in establishing the presence of invasion has been a desmoplastic tumor stroma associated with the invasive carcinoma arising in polyp (fig. 3b). Pathologists have long been familiar with the stromal reaction associated with epithelial neoplasms, especially of intestinal origin. However, no mention of this stromal feature in invasive carcinoma arising in polyp has been found in the literature. In reviewing 35 instances of carcinoma, the source of which is in polyp, it was noted that those tumors demonstrating invasion of the muscularis mucosa were accompanied by a desmoplastic tumor stroma. On the other hand, neoplasms classified as carcinoma in situ or superficial carcinoma arising in polyp failed to demonstrate such a stromal change.

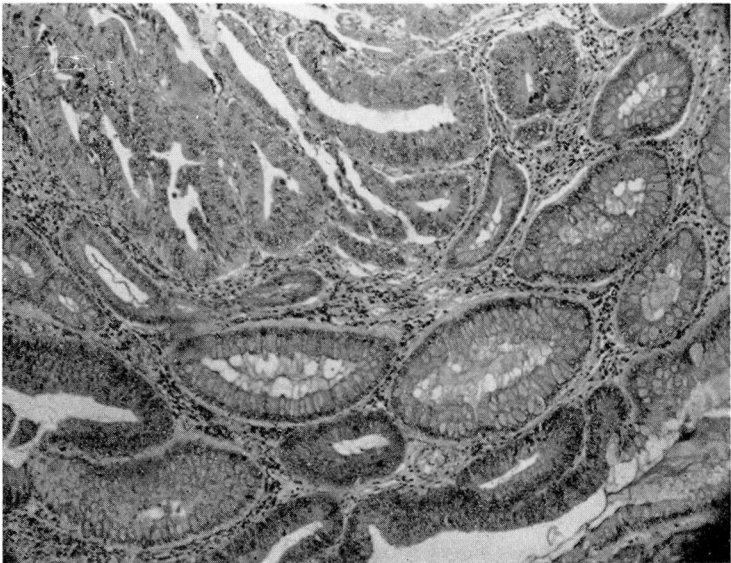
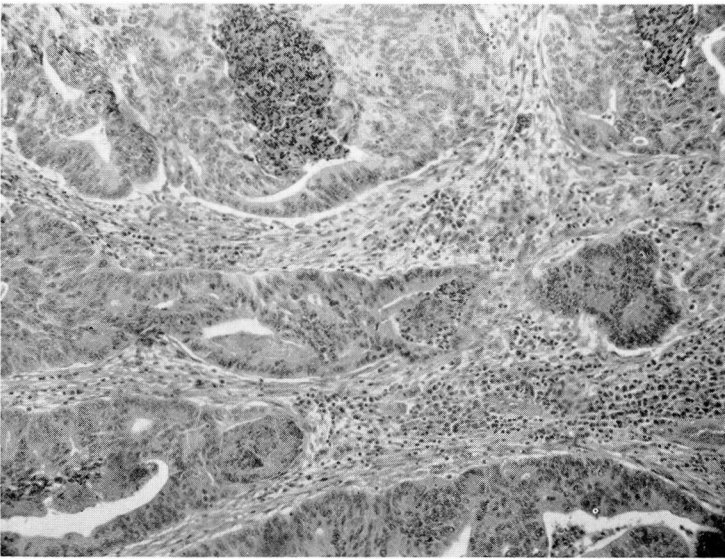
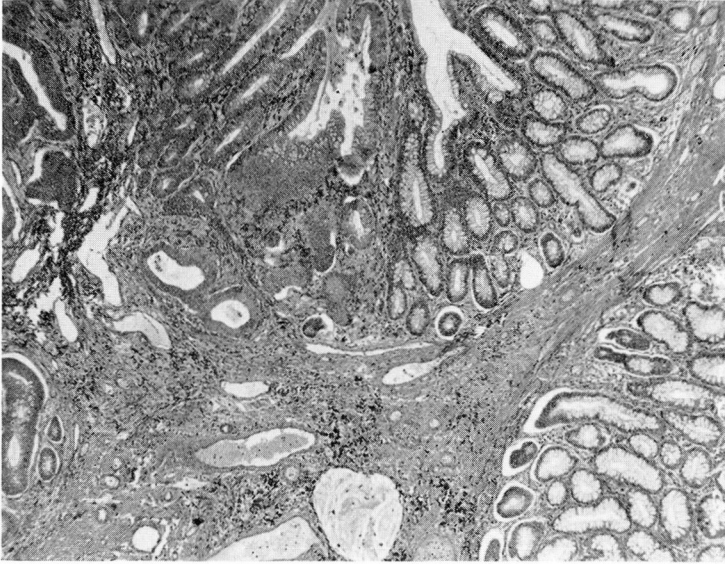


FIG. 2. Superficial carcinoma arising in polyp at upper left. Notice glandular budding. No evidence of desmoplastic tumor stroma (x70).

CARCINOMA ARISING IN POLYP

Although hemorrhage and reactive changes may produce a rather dense stroma in polyp, the presence of abundant inflammatory cells and hemosiderin as well as the absence of tumor cells are helpful in the differentiation of this

(a)



(b)

FIG. 3. (a) Carcinoma invading muscularis mucosa at left (x70). (b) Another area from same tumor as in 3a with desmoplastic tumor stroma (x70).

stroma from that of invasive carcinoma. Occasionally, an inflammatory infiltrate as well as hemosiderin may be present in the desmoplastic carcinoma stroma, however tumor cells will be apparent in adjoining stromal elements.

It is admitted that the frozen section diagnosis of carcinoma arising in polyp may be difficult and somewhat inaccurate, due to technical difficulties and comparatively poor staining differential. Nevertheless, this procedure is occasionally resorted to in the diagnosis of polyps located 5 inches above the dentate line. Polypoid and sessile lesions are oftentimes removed by colonic resection but because of complicating disease, old age, or senility, a minimal surgical procedure is occasionally desired. Using the frozen section technic described by Hazard and Stevenson,² we have found the results satisfactory in establishing immediate diagnosis at the time of colotomy. The polyp is oriented for the pathologist by the surgeon at the operating table; it is then sectioned through the stalk into two portions with a long, sharp razor blade. One of these is used for frozen section and the other processed for permanent study. For frozen section, one portion is fixed in toto on bibulous paper by bringing the fixing fluid (alcohol 70 per cent, formalin 27 per cent, acetic acid 3 per cent) to its boiling point, and then sectioned into thin slices and once again placed in the fixing fluid and re-heated so as to insure adequate fixation. The tissue block, which has a tendency to curl, may be flattened on the freezer head by applying pressure with a glass slide during the freezing process. By this routine, the difficulties of orientation and adequate fixation and sectioning are minimized. Although cellular detail is less distinct than in permanent sections, the detection of a desmoplastic stroma associated with suspicious glandular elements has proved invaluable in the frozen section diagnosis in such lesions and has been helpful to the surgeon in his method of treatment. One of the disadvantages of such a procedure is that all areas of the polyp are not examined immediately. If the diagnosis is equivocal, the previously fixed portion, as well as the portion of tissue submitted for frozen section diagnosis, is available for permanent study. Only rarely has the frozen section diagnosis been equivocal, and under this condition the surgeon must rely upon his clinical judgment as to the most effective procedure. We favor resection under most circumstances where there is doubt.

The surgeon's cooperation with the pathologist is essential for the successful histologic study of carcinoma arising in polyp. The surgeon must supply adequate, well oriented tissue for histologic study. The entire lesion is preferable for examination, although when this is not feasible (in instances of high rectal lesions) multiple fragments from all areas have proved satisfactory.

References

1. Fisher, E. R. and Turnbull, R. B.: Malignant polyps of rectum and sigmoid; therapy based upon pathologic considerations. *Surg., Gynec. and Obst.* (To be published).
2. Hazard, J. B. and Stevenson, G. F.: Frozen section technic. *Am. J. Clin. Path.* 19:873 (Sept.) 1949.