PULMONARY BLASTOMYCOSIS: A REPORT OF A CASE TREATED WITH 2-HYDROXYSTILBAMIDINE

WILLIAM J. STAAB, JR., M.D.,*
Division of Medicine

and

HOWARD S. VAN ORDSTRAND, M.D.
Department of Pulmonary Disease

NORTH American blastomycosis may exist as a cutaneous or a systemic disease. In the systemic form the organs most frequently affected are the lungs and the bones; however, other organs are affected in a significant number of cases.[1] The disease may have many and bizarre manifestations and has even been reported as having simulated multiple myeloma, with an increase of plasma cells in the bone marrow.[2] The epidemiology is poorly understood and no definite conclusions as to the reservoir or mode of transmission have been established. It is believed that the causal organism, a fungus, resides in moist soil and that humans contract the systemic type of blastomycosis by inhalation, and the cutaneous type by primary inoculation of exposed surfaces.[3-5]

It was previously thought that the cutaneous form was more prevalent, but in a recent series of 40 patients only four had isolated skin lesions.[2] The most frequent symptoms were cough, hemoptysis, expectoration, and fever. Our report is of a case of pulmonary blastomycosis in which the primary symptom was fever, and which was complicated by chest pain and hemoptysis secondary to a pulmonary embolus.

Report of a Case

History. A 46-year-old man, an office worker from southwestern Ohio, was admitted to the Cleveland Clinic Hospital on January 21, 1957, with a chief complaint of fever of about one month's duration. In November, 1956, he had a fever of short duration associated with a sore throat, which responded to penicillin. He again had a sore throat and fever in mid-December, and was hospitalized; he stated that he had "virus pneumonia." While in the hospital he had a daily temperature of 101 to 102°F. He stated that he had had no cough, hemoptysis, or chest pain. During the hospitalization a diagnosis of diabetes was made and he was given insulin.

For three years he had "arthritis," which started with pain in the jaws, and in the last year had consisted of pain and stiffness in the hands and wrists. For the past year he had taken prednisone four times daily, and previous to that he received corticotropin (ACTH), cortisone, and gold salts. The administration of prednisone had been discontinued at the time he was hospitalized for pneumonia, and his joint symptoms then became worse.

**Chief Medical Resident.*

Physical findings. The temperature was 101.8°F.; the pulse rate was 100; and the blood pressure was 130/70 mm. of Hg. The patient had a Cushingoid facies and phlebitis near a recent cut-down site on the left ankle. Examination of the lungs disclosed a few moist rales and decreased breath sounds at the base of the right lung. The joints were tender and a sensation of heat was present over the wrists, elbows, and left shoulder. There was minimal swelling of soft tissue over the left knee and ankle. There was moderate limitation of motion of the above-mentioned joints, and he had a weak grasp.

Clinical findings. The hemoglobin was 13.5 gm. per 100 ml.; leukocyte count was 13,300 per cu. mm. with 66 segmented cells, 7 stab cells, 21 lymphocytes, and 6 monocytes. Urinalysis showed a pH of 7.5, a trace of albumin, no sugar, occasional erythrocytes, and from 4 to 6 pus cells. The erythrocyte sedimentation rate (Rourke-Ernstene method*) was 2.05 mm. per min.; blood urea nitrogen was 21 mg. per 100 ml.; a fasting blood sugar was 135 mg. per 100 ml.; transaminase was 21 units; serum protein was 6.6 gm. per 100 ml., with 3.45 gm. of albumin and 3.15 gm. of globulin; serum polysaccharides were 236 mg. per 100 ml. Results of a blood test for lupus erythematosus were negative. Two blood cultures were sterile. Sputum smears and cultures were negative for acid-fast bacilli and fungi. Results of histoplasmin and blastomycin skin tests were negative, and an intermediate strength PPD** was positive. Results of complement fixation tests for blastomycosis, histoplasmosis, and coccidioidomycosis were negative. Biopsy specimens of skin and muscle tissue showed no evidence of pathologic changes. A chest roentgenogram showed an infiltration in the right lower lobe (Fig. 1).

Hospital course. The patient's diabetes was well controlled with 15 units of NPH† insulin daily. He was started on a program of ACTH, chloroquine phosphate, and prednisone for the arthritis. His daily afternoon temperature was from 101 to 102° F. throughout his stay in the hospital.

Two days after admission the patient experienced a sudden onset of left pleuritic pain; the following day he coughed up bloody sputum. Examination of the lungs showed decreased breath sounds and rales at both bases, and a left pleural rub; the patient was splinting the left side of the chest. Another roentgenogram of the chest at this time showed evidence of a pulmonary infarction in the left lower lobe of the lung. The area of infiltration in the right lower lobe was thought to be indicative of a neoplasm; bronchoscopic findings and bronchial washings were essentially normal. The right middle lobe could not be visualized by bronchography.

A right thoracotomy was performed on February 11, 1957, and the process was found to be inflammatory. The biopsy specimen showed caseous necrosis, and organisms suggestive of *Histoplasma capsulatum* or *Blastomyces dermatitidis* were

---

**Normal is 0.65 mm. or less per minute.*

***Purified protein derivative.*

†*Neutral protamine Hagedorn.*

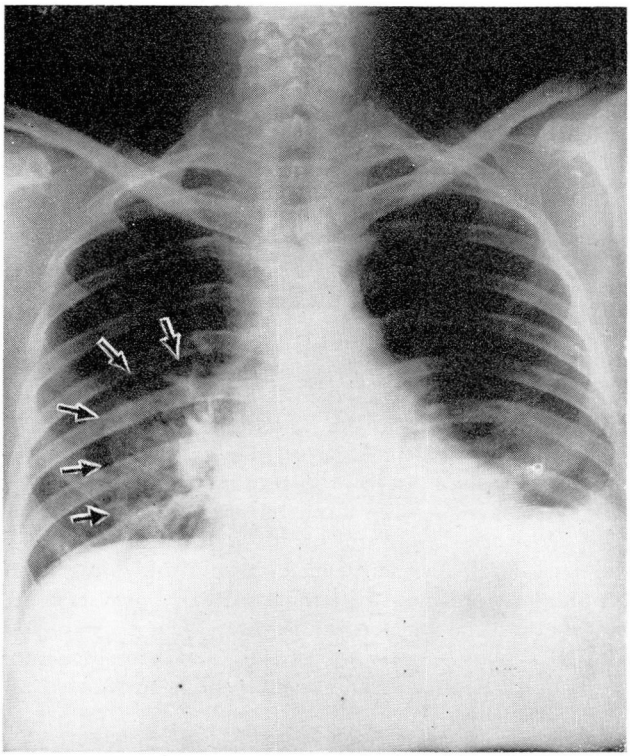

Fig. 1. Photograph of the first roentgenogram showing the discrete, faintly outlined lesion in the right lower lung field.

demonstrated by the Gridley stain (Fig. 2). Cultures of the specimen from the pulmonary biopsy produced *B. dermatitidis.**

The administration of steroids was stopped and the patient was given a low-purine, low-protein diet. He received potassium iodide drops orally, and was given a 10-day course of 2-hydroxystilbamidine, 225 mg. intravenously. He was discharged on February 24, 1957, still febrile and unimproved. He returned on March 8, 1957, for a second 10-day course of 2-hydroxystilbamidine, 150 mg. per day for the first five days, and 225 mg. per day for the last five days. The patient did not accept a longer course of intravenous therapy and he was discharged and advised to take potassium iodide, 60 drops per day.

On May 25, 1957, about two months after the patient had received the last dose of 2-hydroxystilbamidine, he was slightly improved with less fever. On August 1, 1957, he was afebrile; findings of an examination of the chest were normal, and a roentgenogram of the chest showed slight improvement. By December, 1957, he had gained 25 pounds, was asymptomatic, and a roent-

**Culture confirmed through the courtesy of Norman F. Conant, Ph.D., Duke University School of Medicine, Durham, North Carolina*

genogram of the chest showed only residual scarring. He had a few minor pains in the hands, which were easily controlled with small doses of salicylates. At this time he returned to work.

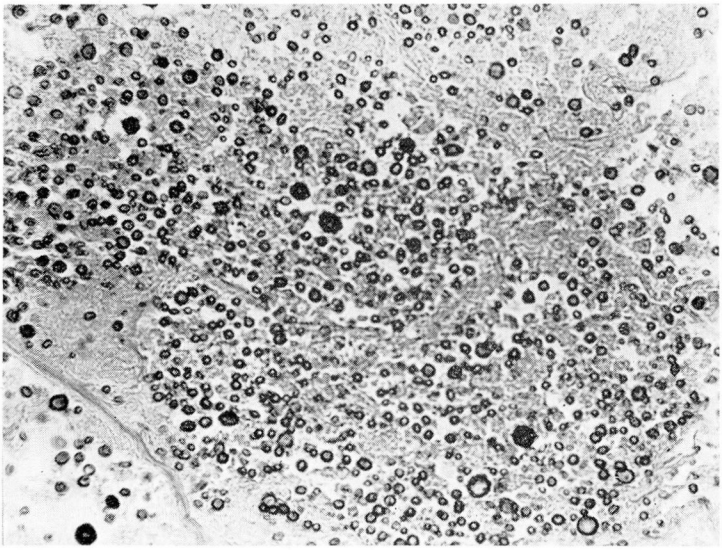

Fig. 2. Photomicrograph of the biopsy specimen of the lung showing *Blastomyces dermatitidis*. Gridley stain; x 280.

Comment

This case illustrates some of the diagnostic difficulties presented by pulmonary blastomycosis. The negative results of the skin test and the complement fixation test are not unusual findings. Martin[6] found a positive skin test in only 56 per cent of patients, and positive serologic evidence in only 53 per cent. It frequently is difficult to make a diagnosis on a tissue examination alone.[3] Our case was strongly suspected to be a bronchogenic carcinoma, which can be mimicked by blastomycosis even to the extent of rib destruction.

Prior to the use of stilbamidine, the two-year survival of patients having blastomycosis was only 8 per cent.[1] Treatment with stilbamidine or 2-hydroxystilbamidine may produce a dramatic response within a few weeks or, the full therapeutic benefit may not be noted for several months.[7,8] The delayed and prolonged response is attributed to the storage of the drug in the tissues; the drug may be found in the urine for about four months after administration has been discontinued. The recommended dosage is 150 mg. of stilbamidine, or 225 mg. of 2-hydroxystilbamidine, given intravenously. The drug usually is given daily for 30 days or in three 10-day courses with a 10-day rest between each course.[9] Toxicity to stilbamidine may be manifested by hepatic or renal necrosis, or by neuropathy most commonly affecting the trigeminal nerve. The

toxic properties of the drug are enhanced by exposure of it to sunlight, which should be avoided before and during administration. The neuropathy may also be precipitated by exposure of the patient to intense sunlight as long as three months after the last dose has been taken. Though troublesome, the neuropathy subsides within several months. The therapeutic effect of 2-hydroxystilbamidine is about one half, and its toxic effect about one sixth, that of stilbamidine, and it has not been noted to cause neuropathy.[9]

Although 2-hydroxystilbamidine has lowered the mortality in cases of blastomycosis, long-term studies have not been recorded in a sufficient number of cases for it to be properly evaluated. Harrel, Bocobo, and Curtis[8] suggest that the drug leaves much to be desired as far as a permanent cure without recurrences is concerned.

Acknowledgment

The authors express their thanks to Dr. W. T. Wilkins, Jr., of Piqua, Ohio, for his referral of this patient and for the follow-up reports.

References

1. Martin, D. S., and Smith, D. T.: Blastomycosis (American blastomycosis, Gilchrist's disease); review of literature. Am. Rev. Tuberc. **39**: 275-304, 1939.

2. Cherniss, E. I., and Waisbren, B. A.: North American blastomycosis: Clinical study of 40 cases. Ann. Int. Med. **44**: 105-123, 1956.

3. Weed, L. A.: North American blastomycosis. Am. J. Clin. Path. **25**: 37-45, 1955.

4. Smith, J. G., Jr.; Harris, J. S.; Conant, N. F., and Smith D. T.: Epidemic of North American blastomycosis. J.A.M.A. **158**: 641-646, 1955.

5. Conant, N. F., and others: Manual of Clinical Mycology. Ed. 2. Philadelphia: W. B. Saunders Co., 1954, pp. 45-74.

6. Martin, D. S.: Practical application of some immunologic principles to diagnosis and treatment of certain fungus infections. J. Invest. Dermat. **4**: 471-481, 1941.

7. Sutliff, W. D.; Kyle, J. W., and Hobson, J. L.: North American blastomycosis: clinical forms of disease and treatment with stilbamidine and 2-hydroxystilbamidine. Ann. Int. Med. **41**: 89-107, 1954.

8. Harrel, E. R.; Bocobo, F. C., and Curtis, A. C.: Study of North American blastomycosis and its treatment with stilbamidine and 2-hydroxystilbamidine. Ann. Int. Med. **43**: 1076-1091, 1955.

9. Smith, D. T.: Stilbamidine therapy for blastomycosis. GP **8**: 69-76, 1953.