

ECHINOCOCCUS CYST OF THE LIVER

Report of 4 Cases

WILLIAM G. McPHERON, M.D., and C. ROBERT HUGHES, M.D.

Department of Roentgenology

ECHINOCOCCUS disease is a parasitic disorder seldom encountered in the United States. The condition is also known as echinococcus cyst, hydatid cyst, echinococcosis, and hydatidosis. It is characterized by cystic lesions in the liver and lungs resulting from the infestation of *Taenia echinococcus*, and by lesions which are not truly cystic in some other organs, such as the bone and the brain. For this reason, many writers prefer the name echinococcosis or hydatidosis.

The etiologic agent is *Taenia echinococcus*, or the dog tapeworm.¹ It is a cestode morphologically similar to other tapeworms, having a head with suckers and hooklets and segments of its body called proglottids (usually three, sometimes four or five). The terminal proglottid contains the ova. The eggs, which resemble those of *T. saginata*, the beef tapeworm, are emptied into the bowel lumen of the definitive host by the adult taenia which is present in the small bowel. The definitive host for this parasite is usually a dog but may be a wolf, cat, or some other carnivorous animal. The ova are deposited with the feces of the host. The fecal material containing the ova contaminates grass, vegetables, or water, and by ingesting such substances, the intermediate host is infested. The intermediate host is usually a sheep or other mammal, such as man. Human beings are believed to become infested principally by contact with dogs.

Upon ingestion the parasite ovum proceeds down the digestive tract of the intermediate host and loses its membrane in the alkaline medium of the small bowel. The hexacanth embryo thereby liberated then attaches to the villi of the small bowel, penetrating the wall and entering a capillary vessel. The embryo is then carried to the liver directly by the blood stream, where it is filtered out by a hepatic lobule, setting up a focus in the liver. However, the embryo may pass through the liver and lodge in a capillary bed elsewhere, such as in the lungs, spleen, kidneys, bone, or brain. A second route of transmission to the lungs is by direct boring through the tissues, which would account for the high percentage of involvement in the right lower lobe of the lung.²

Involvement of various parts of the body by *T. echinococcus* is roughly as follows (Arce):³

Liver	70%	Kidneys	2%
Lungs	15%	Brain	2%
Muscles	4%	Connective Tissue	2%
Spleen	3%	Bone	2%

The embryo grows into a larva by a process of vacuolation, forming a vesicle full of fluid with a surrounding germinal epithelium and outer cuticular membrane. By a process of invagination and sometimes evagination from the germinal epithelium of the mother cyst, daughter cysts and eventually grand-daughter cysts are formed, having characteristic scolices with a double row of hooklets. As these scolices grow they detach themselves from the vesicle and drop free into the sac of the mother cyst. These larvae are commonly known as "hydatid sand."

The cysts in the liver are usually single and unilocular, but in some instances may become multilocular due to evagination of the germinal epithelium and development of daughter cysts. These may pinch off and become separated. When cysts do not separate completely from the growth the vesicles frequently look like a bunch of grapes projecting from the main mass (fig. 2a).

With increasing age and growth of the cyst (which is generally slow), there is degeneration of the parasite, rendering it more susceptible to infection. The infection may be either blood-borne or derived from a bile passage into which the cyst may have eroded. These conditions are uncommon. There may be deposition of calcium in the parasite also, but this is usually minimal and not enough for demonstration by roentgenologic examination, at least until late in the process.^{4,5}

The mother cyst or sac has two layers, an inner germinal layer and an outer chitinous or cuticular membrane. The outer membrane has a characteristic laminated structure. The cyst causes a foreign body reaction in the organ (especially true in the liver) and thereby causes the production of a connective tissue layer (or adventitia) around the sac. With the growth of the cyst there is atrophy of the surrounding organ, aiding in the production of the connective tissue capsule. Obliteration of the small vessels by this increase in size leads to endarteritis and diminished blood supply to the capsule.

This relatively avascular fibrous capsule may become necrotic in areas and frequently shows hyaline degeneration. As in degenerated tissue anywhere in the body there may be a deposition of calcium in it. This deposition of calcium in the fibrous capsule is a late manifestation and is indicative of senility of the cyst.⁴

Complications which occur with this disease are trauma and infection.^{4,6} If the cyst wall is broken the larvae may be released into the peritoneal cavity and encyst on the omentum, peritoneum, pelvis, or elsewhere. There may be extension in such a manner through the diaphragm into the lung.² Infection usually causes death of the cyst, and the resulting symptoms are similar to other infections of the liver.

Location of cysts in the liver are, according to Arce,⁶ 85 per cent in the right lobe and 15 per cent in the left lobe. Central or peripheral location within a lobe is of great importance in both diagnosis and treatment. Those which are immediately subphrenic often give rise to few or no signs readily accessible on physical examination. They may, however, cause elevation and diminished excursion of the right leaf of the diaphragm and even diminished aeration of the right base of the lung.

Classical areas in which echinococcosis is to be found are Iceland, Australia, New Zealand, Argentina, and Uruguay.^{4,7} In Iceland 50 cases were reported in 1925; in Argentina one man reported 128 cases from his clinic in three years; in Uruguay incidence is reported as 1 case in every 187 persons. Other endemic areas are Southern Germany, Russia, the Balkan states, and Mediterranean countries, such as Spain and parts of Italy, Greece, Syria, and North Africa. India is an endemic area, and some cases have been reported from Japan. Until recently North America was considered the site of echinococcosis only by virtue of immigration from endemic areas.^{8,9} Magath⁷ reported that 482 cases were recorded in the North American literature from 1880 to 1936 and of these only 22 were natives of the United States or Canada. Hudson¹⁰ reports a cyst in a 67-year-old woman who had been born in Atlanta, Ga., and lived in that city all of her life. She supposedly had not had contact with farm animals but had intermittently kept pet dogs and cats in her home. Hudson found a high incidence of infected livers among the animals at a local slaughter house.

Diagnosis

Diagnosis is based on clinical, roentgenologic, serologic, and blood findings.

The most common symptom is pain. There may be only a feeling of discomfort, or the pain may be sharp and similar to that of gallbladder colic. Radiation of the pain to the back or to the right shoulder occurs frequently and was observed in 2 of our cases. All of the patients reported in this paper had pain as a major symptom. Jaundice occurs frequently (seen in 3 of these 4 cases) and is similar to that produced by a stone in the common duct. The stools may become light-colored and the urine dark. Evidence of a mass in the upper abdomen may be present. Diminished aeration of the right lung is noted in some cases when the cyst is located near the diaphragm or when the liver-cyst mass is quite large. Intolerance to fatty foods and belching are frequent symptoms. When there is rupture through the diaphragm, evidence of pleuritis, coughing, hemoptysis, and expectoration may be present. Scolices may be expectorated and in such cases a definite diagnosis may be established by sputum examination.

Blood and serologic findings include eosinophilia, positive complement fixation test, and positive skin test. Eosinophilia is least constant (about 25 per cent of cases), is present in the early stages, and diminishes or disappears when the cyst becomes senile. Complement fixation test (Imaz-Lorentz) is similar in type to the Kolmer-Wassermann test and is generally positive in about 60 per cent of cases, according to Arce.⁶ The cutaneous reaction test of Casoni is considered most reliable and is positive in about 90 per cent of the cases.^{6,11}

Roentgenologic evidence of hydatid or echinococcus disease of the liver is based on the demonstration of abnormal changes in the right upper abdomen. Direct roentgenologic evidence is present when calcification within the liver shadow or a soft tissue mass attached to the liver can be observed.^{8,12} Calcification of the capsule is usually not homogeneous or symmetrical, and the mass may appear quite irregular. The calcification may be a massive solid-appearing

concrement, as reported in one of the cases of G. Claessen⁴ from Iceland. Because of this variation early diagnosis based on calcification of the fibrous capsule is not easy. The calcific shadow may extend beyond the liver shadow, or a soft tissue shadow produced by a cyst may extend beyond the liver border.

Indirect roentgenologic evidences of an echinococcus cyst of the liver are hepatomegaly, elevation of the right leaf of the diaphragm, and calcification of a cyst in the abdomen extrinsic to the liver. Though a cyst in the liver may be quite small, there may be an associated hepatomegaly. Some believe that liver enlargement is a compensatory phenomenon. One patient in our group had an enormously enlarged liver with a fairly large cyst in the left lobe and some small cysts in the right lobe.

When the cyst is subphrenic the diaphragm is frequently elevated, and there may be suggestive evidence of some atelectasis at the right base. If the cyst has ruptured through the diaphragm, pleural change, evidence of fistulous tracts, and later calcific infiltration in the thorax may occur.

Calcification of a cyst elsewhere in the abdomen or evidence of an echinococcus cyst in other organs of the body suggests the possibility of the same disease in the liver.^{13,14} G. Claessen⁴ reports a case in which there was a large cyst in the pelvis with infestation also present in the liver.

Four cases of echinococcus disease of the liver have been seen at the Cleveland Clinic. The important diagnostic features of these will be briefly summarized.

Case Reports

Case 1. A woman, aged 42, had had pain in the right shoulder for six weeks. This pain radiated into the neck and was aggravated by deep breathing, coughing, and by torsion of the trunk. Slight nausea and some vomiting had been present. There was no history of jaundice or of intolerance to fatty foods. The patient had been born in Italy and resided there for thirty-nine years before coming to the United States.

On examination the liver was palpable 3 fingers' breadth below the right costal margin. It was rounded, somewhat nodular, and interpreted as an enlarged gallbladder with a Riedel's lobe. Pressure over the mass produced typical pain in the shoulder. Diminished breath sounds and dullness on percussion were noted in the right lower thorax. Routine blood studies were normal; eosinophil count was 4 per cent. Urine studies were normal. Complement fixation and skin tests for echinococcosis were not done. Roentgenologic examination demonstrated elevation of the right diaphragm, nonvisualization of the gallbladder, and normal gastrointestinal tract. The patient was placed on a course of anti-amebic therapy without relief. At operation a large cyst in the posterior portion of the right lower lobe of the liver was evacuated. Typical echinococcus larvae with scolices and double rows of hooks were found, and the characteristic cyst wall was demonstrated on pathologic examination. The cyst cavity was packed. Symptoms diminished but did not disappear completely.

Case 2. A woman, aged 41, whose birthplace and residence prior to entering the United States are not known, had complained of a "sour stomach" and nonradiating pain in the right upper abdomen for many years. These attacks of pain were associated with a sense of fullness in the epigastrium and were aggravated or initiated by eating fatty foods. On occasions jaundice was present.

The liver was palpable 3 fingers' breadth below the costal margin. Blood studies were normal, with eosinophil counts of 1 and 3 per cent. Routine urine studies were normal. Liver function test showed no evidence of dysfunction. Complement fixation test was not done, but the skin test was positive at five and thirty minutes. Roentgenologic examination demonstrated a large mass containing calcium in the right upper quadrant. The mass was

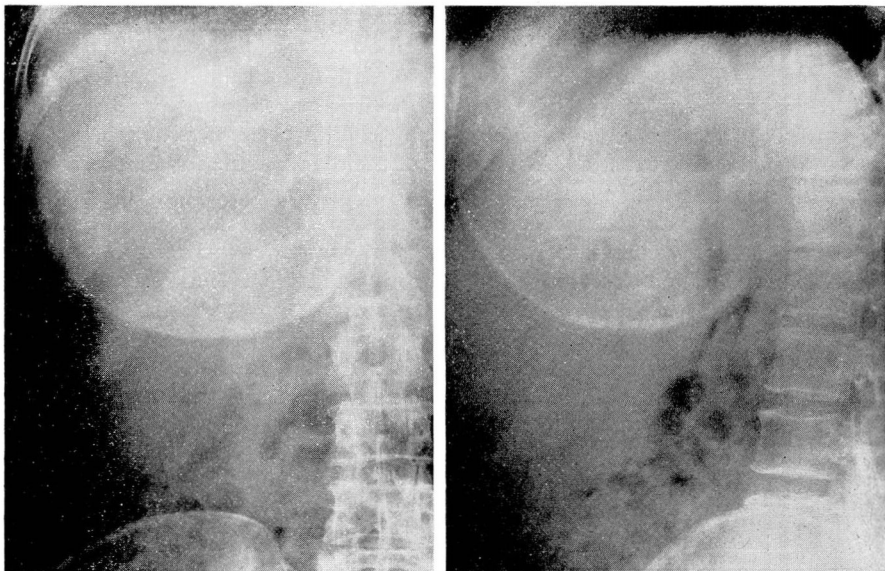


FIG. 1. Postero-anterior and lateral roentgenograms demonstrating irregularly calcified mass in liver. Mass measured approximately 19 cm. in diameter on film.

round, and its diameter measured approximately 19 cm. (fig. 1). The gallbladder was visualized on cholecystographic examination. At operation a large cyst in the inferior portion of the right lobe was evacuated and packed with formalin gauze. Diagnosis of echinococcus cyst was confirmed by pathologic examination. Follow-up showed that the patient had diminished pain and had had no recurrence of jaundice.

Case 3. A boy, aged 16, had had attacks of epigastric pain with occasional vomiting and occasional pain in the right shoulder for two years. On at least two occasions he was jaundiced and noted light-colored stools and dark urine at the time of the attacks. Intolerance to fatty foods was present. He had had no chills or fever. The patient had been born in Italy and had lived there for three and one-half years before coming to the United States.

The liver edge was palpable, and fullness in the epigastrium was noted on examination. Blood studies showed a white blood count of 7250 with 19 per cent eosinophils. Liver function tests were not done. Routine urine studies were normal. Complement fixation tests and skin tests were not made. Roentgenologic examination showed no calcification in the right upper quadrant. On gastrointestinal study there was displacement of the barium-filled first and second portions of the duodenum to the left by the enlarged liver. The gallbladder was not visualized on cholecystographic examination. At operation the right lobe of the liver was found to be tremendously enlarged, and the left lobe was slightly enlarged. Small cysts were present in the right lobe, and a large cyst was present in the central portion of the left lobe. Diagnosis of echinococcus cyst was confirmed by pathologic examination. The cyst was marsupialized and the cavity filled with formalin packs. Since the cyst has filled in there has been no recurrence of symptoms.

Case 4. A man, aged 56, complained of "gallbladder trouble," having had attacks of severe nonradiating epigastric pain for several years. Jaundice was associated with these attacks, but no nausea or vomiting had been noted. There was no intolerance to fatty foods. The patient had been born in Italy and came to this country at the age of 5 or 6.

The patient had had an operation, evidently a cholecystostomy, four years previously, at which time some stones were said to have been removed. Relief of symptoms followed for

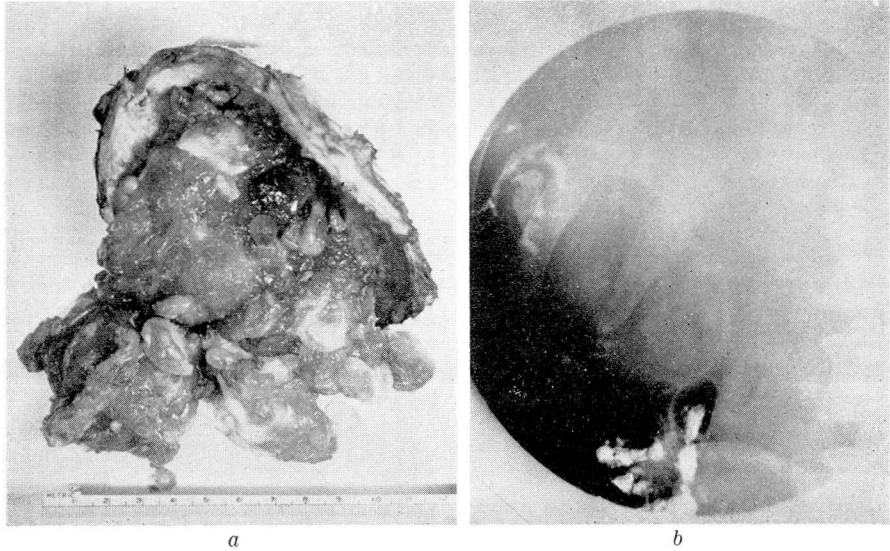


FIG. 2. (a) Surgical specimen, demonstrating thickened adventitia and grape-like vesicles. (b) Roentgenogram showing partially calcified mass extending beyond liver shadow.

about two years, after which they recurred. One year before his visit to the Clinic he was told that x-ray examination showed some "crystals in the liver." On examination the liver was barely palpable. Blood studies were within normal limits except for an eosinophil count of 6 per cent. Routine urine studies were normal. Complement fixation and skin tests were not made. Roentgenologic examination demonstrated a large soft tissue mass in the right lobe of the liver which extended beyond the liver border (fig. 2). Most of the mass was outlined by flecks of calcium around its periphery. The gallbladder was not visualized on cholecystographic study. At operation a large cyst encountered in the right lobe of the liver was evacuated and its wall cauterized. Pathologic studies confirmed the diagnosis of echinococcus cyst. The postoperative period has been too brief for follow-up.

Summary

Four cases of echinococcus cyst of the liver seen at the Cleveland Clinic are reported. All of these patients had pain referable to the right upper quadrant and other symptoms similar to those of gallbladder disease. Three had been jaundiced, and 2 of these were intolerant to fatty foods. All of these patients had hepatomegaly but no evidence of liver damage. Only 1 had significant eosinophilia. Eosinophilia would not be expected in the other cases since the infestation was most likely of quite long standing. Two of the cases showed calcification of the adventitia indicative of an old infestation. The skin test is the most accurate diagnostic test available but was performed in only 1 of the 4 cases reported.

Surgical evacuation at least partially relieved the symptoms in the patients we have been able to follow.

References

1. Stitt, E. R., Clough, P. W., and Clough, M. C.: Practical Bacteriology, Haematology, and Animal Perisitology, ed. 9 (Philadelphia: The Blakiston Co., 1943).
2. Fairley, K. D.: Hydatid disease of lung. *M. J. Australia* 1:346-355 (April 1) 1922.
3. Arce, J.: Hydatid disease (hydatidosis): pathology and treatment. *Arch. Surg.* 42:1-17 (Jan.) 1941.
4. Claessen, G.: The roentgen diagnosis of echinococcus tumors; a study. *Acta radiol. Supplement No. 6*, 1928.
5. Heilbrun, N.: Massive calcification of liver; case report with discussion of its etiology on basis of alveolar hydatid disease. *Am. J. Roentgenol.* 55:189-192 (Feb.) 1946.
6. Arce, J.: Hydatid cyst of liver. *Arch. Surg.* 42:973-987 (June) 1941.
7. Magath, T. B.: Hydatid (Echinococcus) disease in Canada and United States. *Am. J. Hyg.* 25:107-134 (Jan.) 1937.
8. Smith, H. L., and Magath, T. B.: Calcified echinococcus cysts in liver; report of case. *Proc. Staff Meet. Mayo Clin.* 12:405-408 (June 30) 1936.
9. Smyth, M. J.: Calcified hydatid cyst of liver. *Brit. J. Surg.* 27:604 (Jan.) 1940.
10. Hudson, P. L.: Echinococcus disease; report of 3 cases of calcified cysts of liver. *South. M. J.* 38:584-589 (Sept.) 1945.
11. Ferris, D. O.: Echinococcus cysts of liver; report of 2 cases. *Proc. Staff Meet. Mayo Clin.* 15:345-349 (May 29) 1940.
12. Leader, L. O., and Goldberg, G.: Echinococcus cyst of left lobe of liver; report of case. *Am. J. Roentgenol.* 44:207-208 (Aug.) 1940.
13. Cunniffe, E. R.: Double echinococcus cyst of liver treated by marsupialization. *Ann. Surg.* 101:1442-1447 (June) 1935.
14. Steinke, C. R.: Echinococcal cyst (hydatid) of spleen and liver; report of 2 cases. *Am. J. Surg.* 57:544-547 (Sept.) 1942.