

REVIEW

KRZYSZTOF SIEMIONOW, MD

Department of Orthopaedic Surgery,
Cleveland Clinic

MICHAEL STEINMETZ, MD

Department of Neurosurgery, and Cleveland
Clinic Center for Spine Health,
Cleveland Clinic

GORDON BELL, MD

Vice-Chairman, Department of Orthopaedic
Surgery, and Associate Director, Cleveland
Clinic Center for Spine Health, Cleveland Clinic

HAKAN ILASLAN, MD

Department of Radiology, Cleveland Clinic

ROBERT F. MCLAIN, MD

Professor, Cleveland Clinic Lerner College of
Medicine of Case Western Reserve University;
Director of Spine Fellowship Program, Depart-
ment of Orthopaedic Surgery and Cleveland
Clinic Center for Spine Health, Cleveland Clinic

Identifying serious causes of back pain: Cancer, infection, fracture

■ ABSTRACT

Most patients with back pain have a benign condition, but tumors, infections, and fractures must be considered during an initial evaluation because overlooking them can have serious consequences. This article discusses the presentation and diagnostic strategies of these serious causes of back pain.

■ KEY POINTS

A primary tumor or metastasis to the spine tends to cause unremitting back pain that worsens at night and is accompanied by systemic disease and abnormal laboratory findings.

Infection typically causes focal pain, an elevated erythrocyte sedimentation rate (the most sensitive laboratory test) and C-reactive protein level, and sometimes neurologic signs and symptoms.

Fractures cause focal pain and should be suspected especially in older white women and patients who take corticosteroids or who have ankylosing spondylitis.

Plain radiography can help detect fractures, but magnetic resonance imaging is needed to evaluate spinal tumors, soft tissue infections, and epidural abscesses, and to further evaluate neural compression due to fractures.

BACK PAIN is one of the most common complaints that internists and primary care physicians encounter.¹ Although back pain is nonspecific, some hallmark signs and symptoms indicate that a patient is more likely to have a serious disorder. This article contrasts the presentation of cancer, infections, and fractures with the more common and benign conditions that cause back pain and provides guidance for diagnosis.

■ UNCOMMON, BUT MUST BE CONSIDERED

Although a variety of tissues can contribute to pain—intervertebral disks, vertebrae, ligaments, neural structures, muscles, and fascia—and many disorders can damage these tissues, most patients with back or neck pain have a benign condition. Back pain is typically caused by age-related degenerative changes or by minor repetitive trauma; with supportive care and physical therapy, up to 90% of patients with back pain of this nature improve substantially within 4 weeks.²

Serious, destructive diseases are uncommon causes of back pain: malignancy, infection, ankylosing spondylitis, and epidural abscess together account for fewer than 1% of cases of back pain in a typical primary care practice. But their clinical impact is out of proportion to their prevalence. The fear of overlooking a serious condition influences any practitioner's approach to back pain and is a common reason for ordering multiple imaging studies and consultations.³ Therefore, the time, effort, and resources invested in ruling out these disorders is considerable.

Whether a patient with back pain has an ominous disease can usually be determined with a careful history, physical examination,

TABLE 1

Features associated with degenerative disk disease and with neoplastic disease

Degenerative disk disease

- Pain that:
 - Developed after known injury
 - Increases with activity
 - Is aching
 - Subsides with rest, physical therapy, nonsteroidal anti-inflammatory drugs
- Laboratory studies are typically normal
- Patient may have a history of spine surgery

Neoplastic disease

- Age > 50 years
- Pain is not relieved by rest or recumbency
- Anemia
- Elevated erythrocyte sedimentation rate, C-reactive protein level
- Failure to improve with conservative therapy
- History of cancer
- Pain worsens at night

ADAPTED FROM INFORMATION PRESENTED IN DEYO RA, DIEHL AK. CANCER AS A CAUSE OF BACK PAIN: FREQUENCY, CLINICAL PRESENTATION, AND DIAGNOSTIC STRATEGIES. J GEN INTERN MED 1988; 3:230-238 AND PATEL RK, SLIPMAN CW. LUMBAR DEGENERATIVE DISK DISEASE. EMEDICINE. WWW.EMEDICINE.COM/PMR/TOPIC67.HTM.

The spine is one of the most common sites of metastasis

and appropriate diagnostic studies. Once a serious diagnosis is ruled out, attention can be focused on rehabilitation and back care.

Back pain can also be due to musculoskeletal disorders, peptic ulcers, pancreatitis, pyelonephritis, aortic aneurysms, and other serious conditions, which we have discussed in other articles in this journal.⁴⁻⁶

■ SPINAL CANCER AND METASTASES

Since back pain is the presenting symptom in 90% of patients with spinal tumors,⁷ neoplasia belongs in the differential diagnosis of any patient with persistent, unremitting back pain. However, it is also important to recognize atypical presentations of neoplasia, such as a painless neurologic deficit, which should prompt an urgent workup.

The spine is one of the most common sites of metastasis: about 20,000 cases arise each year.⁸ Brihaye et al⁹ reviewed 1,477 cases of spinal metastases with epidural involvement and found that 16.5% arose from primary tumors in the breast, 15.6% from the lung, 9.2% from the prostate, and 6.5% from the kidney.

Cancer pain is persistent and progressive

Pain from spinal cancer is often different from idiopathic back pain or degenerative disk disease (TABLE 1).

Benign back pain often arises from a known injury, is relieved by rest, and increases with activities that load the disk (eg, sitting, getting up from bed or a chair), lumbar flexion with or without rotation, lifting, vibration (eg, riding in a car), coughing, sneezing, laughing, and the Valsalva maneuver. It is most commonly focal to the lumbosacral junction, the lumbar muscles, and the buttocks. Pain due to injury or a flare-up of degenerative disease typically begins to subside after 4 to 6 weeks and responds to nonsteroidal anti-inflammatory drugs and physical therapy.¹⁰

In contrast, pain caused by spinal neoplasia is typically persistent and progressive and is not alleviated by rest. Often the pain is worse at night, waking the patient from sleep. Back pain is typically focal to the level of the lesion and may be associated with belt-like thoracic pain or radicular symptoms of pain or weakness in the legs. A spinal mass can cause neurologic signs or symptoms by directly compressing the spinal cord or nerve roots, mimicking disk herniation or stenosis.^{11,12}

Pathologic fractures resulting from vertebral destruction may be the first—and unfortunately a late—presentation of a tumor.

Ask about, look for, signs and symptoms of cancer

In taking the history, one should ask about possible signs and symptoms of systemic disease such as fatigue, weight loss, and changes in bowel habits. Hemoptysis, lymphadenopathy, subcutaneous or breast masses, nipple discharge, atypical vaginal bleeding, or blood in the stool suggest malignancy and should direct the specific diagnostic approach.¹³ A history of cancer, even if remote, should raise suspicion, as should major risk factors such as smoking.

Because most spinal tumors are metastases, a clinical examination of the breast, lungs, abdomen, thyroid, and prostate are appropriate starting points.¹⁴ The spine should be examined to identify sites of focal pain. A neurologic examination should be done to evaluate any signs of neurologic compromise or abnor-

Spinal metastasis: CT study

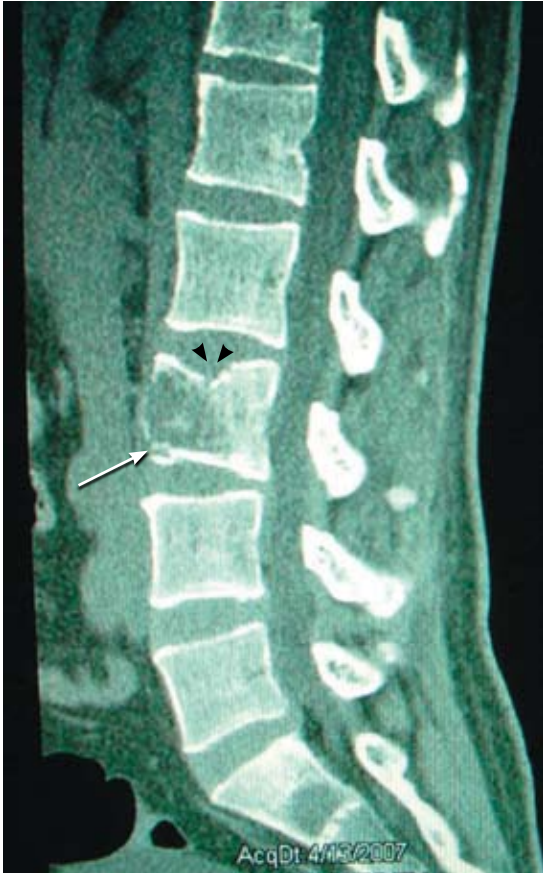

FIGURE 1. A 43-year-old man with a 2-week history of progressive back pain and an abdominal mass. Sagittal CT scan shows an osteolytic lesion of the L3 vertebral body (arrow). The primary tumor was renal. Fracture of the vertebral end plate (arrowheads) may cause first symptoms of pain.

mal reflexes. Signs or symptoms of spinal cord compression should be investigated immediately.

Cancer usually elevates the ESR, CRP

If cancer is suspected, initial tests should include a complete blood cell count, erythrocyte sedimentation rate, C-reactive protein level, urinalysis, prostate-specific antigen level, and fecal occult blood testing. Normal results can considerably relieve suspicion of cancer: the erythrocyte sedimentation rate and C-reactive protein level are almost always elevated with systemic neoplasia.

Other initial tests include a complete blood

Spinal metastasis: MRI study

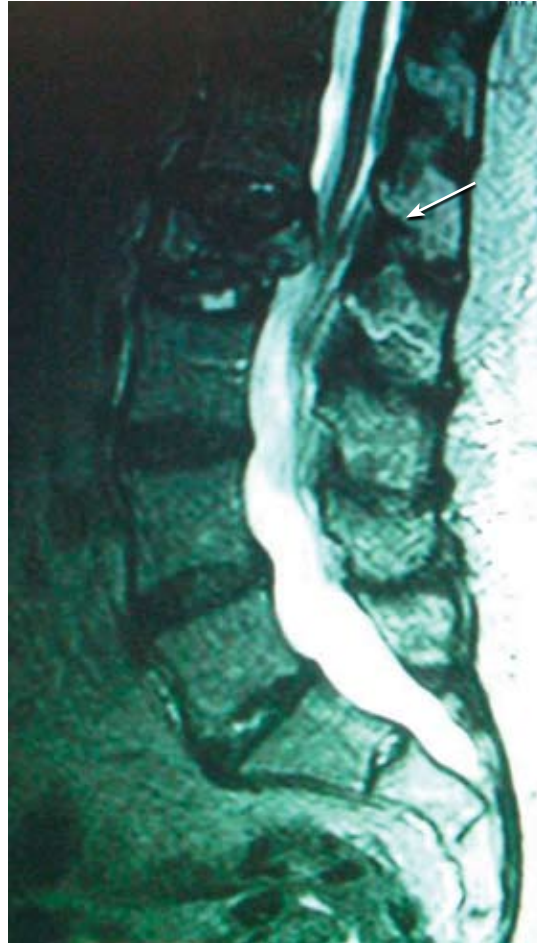

FIGURE 2. A 63-year-old woman with history of hepatocellular carcinoma who presented with bilateral leg weakness and debilitating back pain. T2-weighted MRI shows pathologic compression fracture of the L2 vertebral body with retropulsion of fracture fragments into the canal and severe central canal stenosis (arrow).

The ESR and CRP are almost always elevated with systemic neoplasia

cell count and chemistry panel. If laboratory studies reveal anemia, hypercalcemia, and elevated levels of alkaline phosphatase, concern should increase. Chest radiography, abdominal computed tomography (CT) (FIGURE 1), and mammography for women are needed if laboratory results are abnormal. Plain radiographs are the first imaging study of the spine to obtain. Compression fractures, soft tissue calcifications, or focal loss of bone mineralization suggests tumor. Abnormal results on serum and urine protein electrophoresis in-

crease the likelihood of multiple myeloma or plasmacytoma, but normal results do not rule out monoclonal gammopathy of uncertain significance.

Imaging tests

Unfortunately, spinal tumors cannot be well visualized on radiographs until significant destruction has occurred.¹⁵

A bone scan can usually detect tumors other than the purely lytic ones such as myeloma and has a sensitivity of 74%, a specificity of 81%, and a positive predictive value of 64% for vertebral metastasis in patients with back pain.¹⁶

Magnetic resonance imaging (MRI) is the best imaging study for evaluating spinal tumors because it can show the status of the bone marrow and has excellent contrast resolution in soft tissue (FIGURE 2).^{17,18} It can show vertebral bone marrow infiltration by tumor cells as well as soft tissue masses in and around the spinal column. Bone marrow invaded by a neoplasm is characterized by increased cellularity, resulting in a decreased signal on T1-weighted images and a high signal on T2-weighted images. Intravenous gadolinium further increases the contrast between a tumor and normal tissues and is important for characterizing and grading tumors.¹⁹

■ INFECTION CAN BE INDOLENT OR ACUTE

Spinal infection is a serious condition that can take an indolent, smoldering course or, alternatively, can erupt into sepsis or rapidly progressive vertebral destruction. Although the latter conditions are hard to miss, early diskitis and osteomyelitis can be difficult to differentiate from idiopathic back pain. In a series of 101 patients with vertebral osteomyelitis, misdiagnosis occurred in 33.7%, and the average delay from the onset of clinical manifestations to diagnosis was 2.6 months.²⁰ Tuberculosis can be even more elusive: in a series of 78 patients diagnosed with definite or probable tuberculous vertebral osteomyelitis, the mean delay to diagnosis was about 6 months.²¹

Acute spinal infections are most often pyogenic; chronic infections may be pyogenic, fungal, or granulomatous.

Vertebral osteomyelitis accounts for 2% to

7% of all cases of osteomyelitis and is an uncommon cause of back pain.²² Any source of infection (eg, dental abscess, pneumonia) can seed the spine; urinary tract infection is the most common. Patients with immunocompromise or diabetes are most at risk.²³ The onset is usually insidious with focal back pain at the level of involvement.

History and physical examination reveal localized pain

Spinal infections typically cause pain that is worsened with weight-bearing and activity and is relieved only when lying down. Chronic infection is usually associated with weight loss, fatigue, fevers, and night sweats.

Pain is usually well localized and reproduced by palpation or percussion over the involved level. Severe pain can sometimes be elicited by sitting the patient up or by changing the patient's position. Focal kyphosis may be detectable if the vertebra has collapsed.

In a series of 41 patients with pyogenic infectious spondylitis, 90% had localized back pain aggravated by percussion, 59% had radicular signs and symptoms, and 29% had neurologic signs of spinal cord compression, including hyperreflexia, clonus, the Babinski sign (extension of the toes upward when the sole of the foot is stroked upwards), or the Hoffmann sign (flexion of the thumb elicited by flicking the end of a middle finger).²⁴

■ LABORATORY RESULTS TYPICALLY INDICATE INFECTION

The erythrocyte sedimentation rate is the most sensitive test for infection, and an elevated rate may be the only abnormal laboratory finding: Digby and Kersley²⁵ found that the rate was increased in all of 30 patients with nontuberculous pyogenic osteomyelitis of the spine. The C-reactive protein level is also usually elevated, but 40% of patients have a normal white blood cell count.²⁵ Results of other laboratory tests are typically in the normal range. Tuberculin skin testing should be done for patients at high risk of the disease (eg, immigrants from areas of endemic disease, non-Hispanic blacks, immunocompromised patients, and those with known exposure to tuberculosis). Patients with high fever, chills,

Early infection can be hard to differentiate from idiopathic back pain

or rigors should have cultures taken of blood, urine, and sputum and from any intravenous lines.

Imaging changes may not appear for months

Radiographic findings characteristic of osteomyelitis are not apparent for at least 4 to 8 weeks after the onset of infection.²⁶ Narrowing of the disk space is the earliest and most consistent finding but is nonspecific.²⁷ Pyogenic infection is often heralded by rapid disk destruction and disk space narrowing. MRI is as accurate and sensitive as nuclear medicine scanning (sensitivity 96%, specificity 93%, accuracy 94%).²⁸ MRI can help differentiate degenerative and neoplastic disease from vertebral osteomyelitis²⁹ and provides better imaging than CT for soft-tissue infections (FIGURE 3).

CT, on the other hand, may be better for showing the extent of bone involvement. In cases of vertebral osteomyelitis and intervertebral disk space infection, simultaneous involvement of the adjacent vertebral end plates and the intervertebral disk are the major findings.³⁰

Signs of infection using T1-weighted MRI include low-signal marrow or disk spaces within the vertebral body, loss of definition of end plates (which appear hypointense compared with the bone marrow), and destruction of the cortical margins of the involved vertebral bodies. T2-weighted MRI typically discloses high signals of the affected areas of the vertebral body and disk. Contrast should be used to increase specificity; enhancement may be the first sign of an acute inflammatory process.³¹

CT and MRI can help identify sequestra, perilesional sclerosis, and epidural or soft tissue abscesses. Guided biopsy may be needed to differentiate between abscess, hematoma, tumor, and inflammation.

MRI findings:

Pyogenic vs tuberculous spondylitis

MRI can help differentiate pyogenic vertebral osteomyelitis from tubercular disease, although findings may be similar (eg, both conditions have a high signal on T2-weighted images).³² Jung et al,³³ in a retrospective study of 52 patients with spondylitis, found that compared with patients with pyogenic infec-

Vertebral osteomyelitis: MRI study

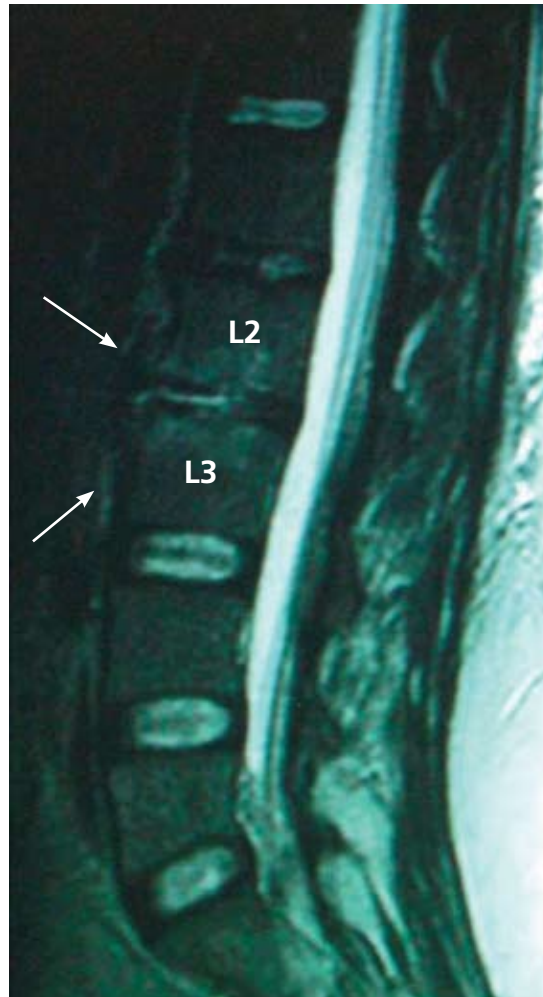


FIGURE 3. A 32-year-old woman with systemic lupus erythematosus who is on chronic steroid therapy and who has a 6-week history of back pain. T2-weighted sagittal MRI shows a disk space infection at L2–L3, with ventral paraspinal soft tissue enhancement consistent with early abscess formation (arrows).

Guided biopsy may be needed to differentiate abscess, hematoma, tumor, and inflammation

tions, patients with tuberculous spondylitis had a significantly higher incidence of a well-defined paraspinal abnormal signal on MRI, a thin and smooth abscess wall, a paraspinal or intraosseous abscess, subligamentous spread to three or more vertebral levels, involvement of multiple vertebral bodies, thoracic spine involvement, and a hyperintense signal on T2-weighted images. Other MRI features characteristically seen in patients with tuberculous spinal disease are anterior corner destruction,

a relative preservation of the intervertebral disk, and large soft-tissue abscesses with calcifications.³⁴

Prompt diagnosis and aggressive treatment needed

Pigrau et al³⁵ found that spinal osteomyelitis is highly associated with endocarditis: among 606 patients with infectious endocarditis, 28 (4.6%) had pyogenic vertebral osteomyelitis, and among 91 patients with pyogenic vertebral osteomyelitis, 28 (30.8%) had infectious endocarditis.

McHenry et al³⁶ retrospectively studied outcomes of 253 patients with vertebral osteomyelitis after a median of 6.5 years (range 2 days to 38 years): 11% died, more than one-third of survivors had residual disability, and 14% had a relapse. Surgery resulted in recovery or improvement in 86 (79%) of 109 patients. Independent risk factors for adverse outcome (death or incomplete recovery) were neurologic compromise, increased time to diagnosis, and having a hospital-acquired infection ($P \leq .004$). Relapse commonly developed in patients with severe vertebral destruction and abscesses, which appeared some time after surgical drainage or debridement. Recurrent bacteremia, paravertebral abscesses, and chronically draining sinuses were independently associated with relapse ($P \leq .001$). MRI, done in 110 patients, was often performed late in the course of infection and did not significantly affect outcome. The authors stressed that an optimal outcome of vertebral osteomyelitis requires heightened awareness, early diagnosis, prompt identification of pathogens, reversal of complications, and prolonged antimicrobial therapy.

Epidural abscess may also be present

Epidural abscess occurs in 10% of spine infections. About half of patients with an epidural abscess are misdiagnosed on their initial evaluation.^{37,38} Patients initially complain of local spine pain, followed by radicular pain, weakness, and finally paralysis. Between 12% and 30% of patients report a history of trauma, even as minor as a fall, preceding the infection.^{38,39}

Radiologic findings are frequently equivocal, and MRI is preferred; gadolinium enhance-

ment further increases sensitivity.^{39,40} Spinal canal abscesses usually appear hypointense on T1-weighted images and hyperintense on T2-weighted images, with ring enhancement surrounding the abscess area in contrast studies.⁴¹ MRI may give negative findings in the early stages of a spinal canal infection and so may need to be repeated.⁴¹ MRI may not help distinguish an epidural from a subdural abscess. However, primary spinal epidural abscesses without concomitant vertebral osteomyelitis are rare; therefore, the finding of associated vertebral osteomyelitis makes a spinal epidural abscess more likely.

■ FRACTURES

Fractures of the spine can be asymptomatic and may have no preceding trauma. They can be due to osteoporosis, malignancy, infection, or metabolic disorders such as renal osteodystrophy or hyperparathyroidism. Fractures in normal bone are almost always associated with trauma. Any suspicion of infection or malignancy should be investigated.

Corticosteroids increase risk

Any patient with back pain who is receiving corticosteroid therapy should be considered as having a compression fracture until proven otherwise.³ De Vries et al⁴² found that in a database of nearly 200,000 patients receiving glucocorticoids, risk increased substantially with increasing cumulative exposure. Those who intermittently received high doses (≥ 15 mg/day) and those who had no or little previous exposure to corticosteroids (cumulative exposure ≤ 1 g) had only a slightly increased risk of osteoporotic fracture, and their risk of fracture of the hip and femur was not increased. In contrast, patients who received a daily dose of at least 30 mg and whose cumulative exposure was more than 5 g had a relative risk of osteoporotic vertebral fracture of 14.42 (95% confidence interval 8.29–25.08).

Osteoporotic compression fractures are common in the elderly

Osteoporosis involves reduced bone density, disrupted trabecular architecture, and increased susceptibility to fractures. About 700,000 vertebral body compression fractures

Fractures in normal bone are almost always associated with trauma

TABLE 2

Imaging features of benign vs malignant compression fractures

BENIGN	MALIGNANT
Solitary lesion with smooth margins	Multiple lesions, heterogeneous enhancement in multiple vertebrae
Superior end plate fracture with abnormal band-like signal parallel to superior end plate	Inferior end plate fracture or abnormal signal only in lower portion of vertebral body
Normal fatty marrow	Normal fatty marrow absent
No pedicle involvement	Pedicle involvement
Fracture line	No fracture line
No convex cortical contour	Convex cortical contour
No extraosseous soft tissue mass	Extraosseous soft tissue mass
Intravertebral fluid	No intravertebral fluid
Fragmentation	No fragmentation

ADAPTED FROM TAHRANZADEH J, TAO C. ADVANCES IN MR IMAGING OF VERTEBRAL COLLAPSE. SEMIN ULTRASOUND CT MRI 2004; 25:440-460. WITH PERMISSION FROM ELSEVIER.

occur in the United States each year⁴³; about 10% result in hospitalization, involving an average stay of 8 days.⁴⁴ Osteoporotic compression fractures are highly associated with age older than 65, female sex, and European descent.^{45,46} The estimated lifetime risk of a clinically evident vertebral fracture after age 50 years is 16% among postmenopausal white women and 5% among white men.⁴⁷

A single osteoporotic vertebral compression fracture increases the risk of subsequent fractures by a factor of five, and up to 20% of patients with a vertebral compression fracture are likely to have another one within the same year if osteoporosis remains untreated.⁴⁸ Population studies suggest that the death rate among patients who have osteoporotic vertebral compression fractures increases with the number of involved vertebrae.⁴³

Unfortunately, osteoporotic vertebral compression fractures are not always easily amenable to treatment: up to 30% of patients who are symptomatic and seek treatment do not respond adequately to nonsurgical methods.^{49,50} However, new minimally invasive interventions such as vertebral augmentation make timely evaluation clinically relevant.

History, physical examination

Patients may present with a history of trauma with associated back pain or a neurologic deficit. In osteoporotic patients, the trauma may have been minimal, eg, a sneeze, a fall from a chair, or a slip and fall in the home. Pain tends to be worse when standing erect and occasionally when lying flat.

The patient is commonly visibly uncomfortable and may be limited to a wheelchair or stoop forward when standing. The spine may show an absence of the midline crease or an exaggerated thoracic kyphosis. Pain is typically reproduced by deep pressure over the spinous process at the involved level. Compression fractures rarely cause neurologic deficits but should always be considered.

Fractures commonly occur in the thoracolumbar region but may be anywhere in the spine. Fractures in the upper thoracic spine may indicate an underlying malignant tumor, and a thorough search for a possible primary lesion should always be carried out for fractures in this location.

Laboratory testing

Routine laboratory evaluation and thyroid function tests should be done, as well as a 24-

Fractures in the upper thoracic spine may indicate an underlying tumor

TABLE 3

Features of cauda equina compression vs spinal cord compression

FEATURES	CAUDA EQUINA COMPRESSION	SPINAL CORD COMPRESSION
Vertebral level	L2-sacrum	C1-L1
Spinal level	Injury to lumbosacral nerve roots	Injury to spinal cord
Symmetry of signs, symptoms	Usually asymmetric	Usually symmetric
Pain	Prominent, asymmetric, and radicular	Typically, bilateral extremity pain or painless
Motor	Weakness or flaccid paralysis	Weakness or spastic paralysis
Sensory	Saddle anesthesia, may be asymmetric	Loss of pinprick, temperature, position, and vibratory sensation may occur early
Reflexes	Areflexic lower extremities; bulbocavernosus reflex is absent in low (sacral) lesion	Hyperreflexia, Babinski sign, clonus

REPRINTED WITH PERMISSION FROM QURESHI NH. CAUDA EQUINA. EMEDICINE. WWW.EMEDICINE.COM/MED/TOPIC2904.HTM. ACCESSED 2/20/2008.

Ankylosing spondylitis predisposes to serious spinal injury

hour urine specimen for collagen breakdown products, calcium, phosphate, and creatinine levels. Serum and urine protein electrophoresis should be performed if myeloma is suspected. A white blood-cell count, erythrocyte sedimentation rate, and C-reactive protein level help determine if an underlying infection caused the fracture.

MRI needed if plain films reveal fracture or are equivocal

Anteroposterior and lateral roentgenograms should be taken first; they typically show osteopenia. A fracture in the vertebral body is characterized by loss of height and by wedging. Osseous fragments can occasionally be seen in the spinal canal.

If a fracture is diagnosed or the radiographs are equivocal, MRI of the spine should be done next, since it is probably best for determining fracture age, detecting a malignant tumor (TABLE 2), and helping select appropriate treatment. Shortly after a vertebral fracture, MRI shows a geographic pattern of low-intensity signal changes on T1-weighted images and high-intensity signal changes on T2-weighted images. As a fracture becomes chronic, a linear area of low-intensity signal change replaces the geographic area on T1-weighted images. As healing continues, the

linear pattern is replaced by restoration of fatty marrow.⁵¹

Sagittal short tau inversion recovery sequences, which use specifically timed pulse sequences to suppress fat signals, show high-intensity signal changes in areas of edema from acute or healing fractures. They provide a sensitive but nonspecific marker of abnormality.

Dual energy x-ray absorptiometry helps determine the extent of osteoporosis.

Bone scans should only be used for patients with suspected metastatic disease.

Patients with ankylosing spondylitis need thorough workup

Ankylosing spondylitis predisposes to serious spinal injury. Even after only minor trauma, patients with ankylosing spondylitis and acute, severe back pain should be thoroughly evaluated for fracture with CT and MRI of the entire spine. Plain radiography should not be relied on for these patients because of the risk of misinterpretation, delayed diagnosis, and poorer outcomes.^{52,53}

■ NEUROLOGIC COMPROMISE—A RED FLAG

Neural compromise can result from spinal cord or cauda equina compression (TABLE 3). Cauda equina compression usually results

from a fracture, tumor, epidural hematoma, or abscess, and occasionally from massive disk herniation. Paraplegia, quadriplegia, or cauda equina deficit should trigger an aggressive search for the cause.⁵⁴

Cauda equina compression classically presents with back pain, bilateral sciatica, saddle anesthesia, and lower extremity weakness progressing to paraplegia, but in practice these symptoms are variably present and diagnosing the condition often requires a high degree of suspicion. Hyporeflexia is typically a sign of cauda equina compression, while hyperreflexia, clonus, and the Babinski sign suggest spinal cord compression, requiring an evaluation of the cervical and thoracic spine. Cauda equina compression typically involves urinary retention; in contrast, cord compression typically causes incontinence.⁵⁵

If either cauda equina or spinal cord compression is detected during an initial examination, an immediate more extensive evaluation is warranted. MRI is the study of choice.

Spinal epidural hematoma

Spinal epidural hematoma is a rare but dramatic cause of paralysis in elderly patients. In most cases, there is no antecedent trauma. Lawton et al,⁵⁶ in a series of 30 patients treated surgically for spinal epidural hematoma, found that 73% resulted from spine surgery, epidural catheterization, or anticoagulation therapy. Other possible causes of epidural hematoma include vascular malformations, angiomas, aneurysms, hypertension, and aspirin therapy.⁵⁷

The same study⁵⁶ found that the time from

the first symptom to maximal neurologic deficit ranged from a few minutes to 4 days, with the average interval being nearly 13 hours.

Although painless onset has been reported,⁵⁸ spinal epidural hematoma typically presents with acute pain at the level of the lesion, which is often rapidly followed by paraplegia or quadriplegia, depending on the location of the hemorrhage. Sometimes the onset of pain is preceded by a sudden increase of venous pressure from coughing, sneezing, or straining at stool. Urinary retention often develops at an early stage.

Most lesions occur in the thoracic region and extend into the cervicothoracic or the thoracolumbar area. The pain distribution may be radicular, mimicking a ruptured intervertebral disk.

Evaluation should be with MRI. Acute hemorrhage is characterized by a marked decrease in signal intensity on T2-weighted images. Subacute hematoma has increased signal intensity on both T1- and T2-weighted images.⁵⁶

Early recognition, MRI confirmation, and treatment should be accomplished as soon as possible.⁵⁶ Recovery depends on the severity of the neurologic deficit and the duration of symptoms before treatment. Lawton et al⁵⁶ found that patients taken to surgery within 12 hours had better neurologic outcomes than patients with identical preoperative neurologic status whose surgery was delayed beyond 12 hours. Surgery should not be withheld because of advanced age or poor health: in 10 reported cases in which surgery was delayed, all patients died.⁵⁹ ■

REFERENCES

1. Deyo RA, Tsui-Wu YJ. Descriptive epidemiology of low-back pain and its related medical care in the United States. *Spine* 1987; 12:264-268.
2. Pengel LH, Herbert RD, Maher CG, Refshauge KM. Acute back pain: systematic review of its prognosis. *BMJ* 2003; 327:323-325.
3. Deyo RA, Rainville J, Kent DL. What can the history and physical examination tell us about back pain? *JAMA* 1992; 268:760-765.
4. Pateder DB, Brems J, Lieberman I, Bell GR, McLain RF. Masquerade: nonspinal musculoskeletal disorders that mimic spinal conditions. *Cleve Clin J Med* 2008; 75:50-56.
5. Klineberg E, Mazanec D, Orr D, Demicco R, Bell G, McLain R. Masquerade: medical causes of back pain. *Cleve Clin J Med* 2007; 74:905-913.
6. McLain RF, Bell G, Montgomery W. Masquerade: systemic causes of back pain. *Cleve Clin J Med*. In press.
7. Gilbert RW, Kim JH, Posner JB. Epidural spinal cord compression from metastatic tumor: diagnosis and treatment. *Ann Neurol* 1978; 3:40-51.
8. Black P. Spinal metastasis: current status and recommended guidelines for management. *Neurosurgery* 1979; 5:726-746.
9. Brihaye J, Ectors P, Lemort M, Van Houtte P. The management of spinal epidural metastases. *Adv Tech Stand Neurosurg* 1988; 16:121-176.
10. Patel RK, Slipman CW. Lumbar degenerative disk disease. *Emedicine*. Accessed March 25, 2008. <http://www.emedicine.com/pmr/topic67.htm>.
11. Deyo RA, Diehl AK. Cancer as a cause of back pain: frequency, clinical presentation, and diagnostic strategies. *J Gen Intern Med* 1988; 3:230-238.
12. Rosen P, Barkin RM, Danzl DF, et al. *Emergency Medicine: Concepts and Clinical Practice*. 4th ed. St Louis, MO: Mosby; 1998:2100-2102.
13. Abbruzzese JL, Abbruzzese MC, Lenzi R, Hess KR, Raber MN. Analysis of a diagnostic strategy for patients with suspected tumors of unknown origin. *J Clin Oncol* 1995; 13:2094-2103.
14. McCarthy EF, Frassica FJ. *Pathology of Bone and Joint Disorders: With Clinical and Radiographic Correlation*. Philadelphia: WB Saunders; 1998.
15. Edelstyn GA, Gillespie PJ, Grebbell FS. The radiological demonstra-

- tion of osseous metastases. Experimental observations. *Clin Radiol* 1967; 18:158–162.
16. Han LJ, Au-Yong TK, Tong WC, Chu KS, Szeto LT, Wong CP. Comparison of bone single-photon emission tomography and planar imaging in the detection of vertebral metastases in patients with back pain. *Eur J Nucl Med* 1998; 25:635–638.
 17. Feun LG, Savaraj N. Detection of occult bone metastasis by MRI scan. *J Fla Med Assoc* 1990; 77:881–883.
 18. Citrin DL, Bessent RG, Greig WR. A comparison of the sensitivity and accuracy of the 99TcM-phosphate bone scan and skeletal radiograph in the diagnosis of bone metastases. *Clin Radiol* 1977; 28:107–117.
 19. Runge VM, Lee C, Iten AL, Williams NM. Contrast-enhanced magnetic resonance imaging in a spinal epidural tumor model. *Invest Radiol* 1997; 32:589–595.
 20. Buranapanitkit B, Lim A, Geater A. Misdiagnosis in vertebral osteomyelitis: problems and factors. *J Med Assoc Thai* 2001; 84:1743–1750.
 21. Colmenero JD, Jiménez-Mejías ME, Reguera JM, et al. Tuberculous vertebral osteomyelitis in the new millennium: still a diagnostic and therapeutic challenge. *Eur J Clin Microbiol Infect Dis* 2004; 23:477–483.
 22. Waldvogel FA, Medoff G, Swartz MN. Osteomyelitis: a review of clinical features, therapeutic considerations and unusual aspects. 3. Osteomyelitis associated with vascular insufficiency. *N Engl J Med* 1970; 282:316–322.
 23. Carragee EJ. Pyogenic vertebral osteomyelitis. *J Bone Joint Surg Am* 1997; 79:874–880.
 24. Kapeller P, Fazekas F, Krametter D, et al. Pyogenic infectious spondylitis: clinical, laboratory and MRI features. *Eur Neurol* 1997; 38:94–98.
 25. Digby JM, Kersley JB. Pyogenic non-tuberculous spinal infection: an analysis of thirty cases. *J Bone Joint Surg Br* 1979; 61:47–55.
 26. Modic MT, Feiglin DH, Piraino DW, et al. Vertebral osteomyelitis: assessment using MR. *Radiology* 1985; 157:157–166.
 27. Szypryt EP, Hardy JG, Hinton CE, Worthington BS, Mulholland RC. A comparison between magnetic resonance imaging and scintigraphic bone imaging in the diagnosis of disk space infection in an animal model. *Spine* 1988; 13:1042–1048.
 28. Küker W, Mull M, Mayfrank L, Töpper R, Thron A. Epidural spinal infection. Variability of clinical and magnetic resonance imaging findings. *Spine* 1997; 22:544–551.
 29. Tung GA, Yim JW, Mermel LA, Philip L, Rogg JM. Spinal epidural abscess: correlation between MRI findings and outcome. *Neuroradiology* 1999; 41:904–909.
 30. Sapico FL, Montgomerie JZ. Vertebral osteomyelitis. *Infect Dis Clin North Am* 1990; 4:539–550.
 31. Tali ET. Spinal infections. *Eur J Radiol* 2004; 50:120–133.
 32. Smith AS, Weinstein MA, Mizushima A, et al. MR imaging characteristics of tuberculous spondylitis vs vertebral osteomyelitis. *AJR Am J Roentgenol* 1989; 153:399–405.
 33. Jung NY, Jee WH, Ha KY, Park CK, Byun JY. Discrimination of tuberculous spondylitis from pyogenic spondylitis on MRI. *AJR Am J Roentgenol* 2004; 182:1405–1410.
 34. Joseffer SS, Cooper PR. Modern imaging of spinal tuberculosis. *J Neurosurg Spine* 2005; 2:145–150.
 35. Pigrau C, Almirante B, Flores X, et al. Spontaneous pyogenic vertebral osteomyelitis and endocarditis: incidence, risk factors, and outcome. *Am J Med* 2005; 118:1287.
 36. McHenry MC, Easley KA, Locker GA. Vertebral osteomyelitis: long-term outcome for 253 patients from 7 Cleveland-area hospitals. *Clin Infect Dis* 2002; 34:1342–1350.
 37. Danner RL, Hartman BJ. Update on spinal epidural abscess: 35 cases and review of the literature. *Rev Infect Dis* 1987; 9:265–274.
 38. Kaufman DM, Kaplan JG, Litman N. Infectious agents in spinal epidural abscesses. *Neurology* 1980; 30:844–850.
 39. Rezaei AR, Woo HH, Errico TJ, Cooper PR. Contemporary management of spinal osteomyelitis. *Neurosurgery* 1999; 44:1018–1026.
 40. Bertino RE, Porter BA, Stimac GK, Tepper SJ. Imaging spinal osteomyelitis and epidural abscess with short TI inversion recovery (STIR). *AJNR Am J Neuroradiol* 1988; 9:563–564.
 41. Rigamonti D, Liem L, Sampath P, et al. Spinal epidural abscess: contemporary trends in etiology, evaluation, and management. *Surg Neurol* 1999; 52:189–197.
 42. De Vries F, Bracke M, Leufkens HG, Lammers JW, Cooper C, Van Staaij TP. Fracture risk with intermittent high-dose oral glucocorticoid therapy. *Arthritis Rheum* 2007; 56:208–214.
 43. Cooper C, Atkinson EJ, O'Fallon WM, Melton LJ 3rd. Incidence of clinically diagnosed vertebral fractures: a population-based study in Rochester, Minnesota, 1985–1989. *J Bone Miner Res* 1992; 7:221–227.
 44. Kim DH, Vaccaro AR. Osteoporotic compression fractures of the spine; current options and considerations for treatment. *Spine J* 2006; 6:479–487.
 45. Cohn SH, Abesamis C, Yasumura S, Aloia JF, Zanzi I, Ellis KJ. Comparative skeletal mass and radial bone mineral content in black and white women. *Metabolism* 1977; 26:171–178.
 46. Tobias JH, Hutchinson AP, Hunt LP, et al. Use of clinical risk factors to identify postmenopausal women with vertebral fractures. *Osteoporos Int* 2007; 18:35–43.
 47. Melton LJ 3rd, Kallmes DF. Epidemiology of vertebral fractures: implications for vertebral augmentation. *Acad Radiol* 2006; 13:538–545.
 48. Silverman SL. The clinical consequences of vertebral compression fracture. *Bone* 1992; 13:527–531.
 49. Melton LJ 3rd, Kan SH, Frye MA, Wahner HW, O'Fallon WM, Riggs BL. Epidemiology of vertebral fractures in women. *Am J Epidemiol* 1989; 129:1000–1011.
 50. Wasnich RD. Vertebral fracture epidemiology. *Bone* 1996; 18:179S–183S.
 51. Yamato M, Nishimura G, Kuramochi E, Saiki N, Fujioka M. MR appearance at different ages of osteoporotic compression fractures of the vertebrae. *Radiat Med* 1998; 16:329–334.
 52. Einsiedel T, Schmelz A, Arand M, et al. Injuries of the cervical spine in patients with ankylosing spondylitis: experience at two trauma centers. *J Neurosurg Spine* 2006; 5:33–45.
 53. Olerud C, Frost A, Bring J. Spinal fractures in patients with ankylosing spondylitis. *Eur Spine J* 1996; 5:51–55.
 54. Spangfort EV. The lumbar disk herniation. A computer-aided analysis of 2,504 operations. *Acta Orthop Scand Suppl* 1972; 142:1–95.
 55. Kostuik JP, Harrington I, Alexander D, Rand W, Evans D. Cauda equina syndrome and lumbar disk herniation. *J Bone Joint Surg Am* 1986; 68:386–391.
 56. Lawton MT, Porter RW, Heiserman JE, Jacobowitz R, Sonntag VK, Dickman CA. Surgical management of spinal epidural hematoma: relationship between surgical timing and neurological outcome. *J Neurosurg* 1995; 83:1–7.
 57. Simmons EH, Grobler LJ. Acute spinal epidural hematoma. *J Bone Joint Surg Am* 1978; 60:395–396.
 58. Senelick RC, Norwood CW, Cohen GH. "Painless" spinal epidural hematoma during anticoagulant therapy. *Neurology* 1976; 26:213–225.
 59. Watts C, Porto L. Recognizing spontaneous spinal epidural hematoma. *Geriatrics* 1976; 31:97–99.

ADDRESS: Robert F. McLain, MD, Cleveland Clinic Center for Spine Health, Department of Orthopaedic Surgery, A41, Cleveland Clinic, 9500 Euclid Avenue, Cleveland, OH 44195; e-mail mclainr@ccf.org.

Visit our web site at <http://www.ccmj.org>

Contact us by e-mail at ccjm@ccf.org