

**CRAIG NIELSEN, MD**Department of General Internal Medicine,
Cleveland Clinic**PETER MAZZONE, MD**Department of General Internal Medicine,
Cleveland Clinic

A 61-year-old woman with edema, shortness of breath, and pleuritic chest pain

A 61-YEAR-OLD WOMAN is transferred to your hospital because of right-sided pleuritic chest pain, lower extremity edema, and dyspnea on exertion, which began 2 days ago.

Four months ago, she was diagnosed with the nephrotic syndrome (proteinuria, hypoalbuminemia, edema, and hyperlipidemia), and a renal biopsy revealed membranous glomerulonephritis as the cause. She received prednisone and cyclophosphamide as treatment.

Within weeks of this diagnosis, the patient developed a deep venous thrombosis in her leg and suffered a pulmonary embolism. She was treated with intravenous heparin and then warfarin. One month later, a new deep venous thrombosis developed, and her physicians placed a filter in her inferior vena cava. Since then, she has been doing relatively well at home, but she is experiencing generalized fatigue and has lost 30 pounds in the past 6 months.

The patient has smoked for more than 40 pack-years. She currently takes prednisone 40 mg daily, levothyroxine for hypothyroidism, and omeprazole. She had developed one other deep venous thrombosis more than 10 years previously, after undergoing a total abdominal hysterectomy. She has no known drug allergies.

Physical examination

On admission the patient is in mild respiratory distress. Her temperature is 37.1°C, heart rate 80, respiratory rate 20, blood pressure 106/57 mm Hg, and oxygen saturation 93% while breathing room air.

Her breath sounds are decreased over the right lower lung fields, which are dull to per-

cussion. Her left calf is swollen and tender, and she has edema in both ankles, but no jugular venous distention. Examination of her heart, abdomen, and nervous system reveals nothing abnormal. Her serum albumin level is 2.7 g/dL; her other laboratory values are shown in **TABLE 1**.

A roentgenogram of the chest (posterior-anterior and lateral) shows a right-sided pleural effusion with a patchy infiltrate in the right middle lobe and upper lobes. Duplex ultrasonography reveals iliofemoral deep venous thromboses in both legs. A ventilation-perfusion (V/Q) lung scan is interpreted as showing an intermediate probability (ie, at least 40%) of pulmonary embolism.

■ CAUSES OF RECURRENT DEEP VENOUS THROMBOSIS AND PULMONARY EMBOLISM

1 What is the most likely cause of this patient's recurrent deep venous thrombosis and pulmonary embolism?

- Protein S deficiency
- Venous stasis
- Activated protein C resistance
- Malignancy
- Membranous glomerulonephritis and the nephrotic syndrome
- Protein C deficiency
- All of the above

This patient has fairly extensive problems, with recurrent deep venous thrombosis and pulmonary embolism high on the list. A number

Look for a cause of membranous glomerulonephritis

TABLE 1

The patient's laboratory values on admission

STUDY	LEVEL	NORMAL RANGE
Albumin	2.7 g/dL	3.5–5
Blood urea nitrogen	12 mg/dL	8–25
Creatinine	0.8 mg/dL	0.7–1.4
Glucose	89 mg/dL	65–110
Alanine aminotransferase	17 U/L	0–30
Aspartate aminotransferase	20 U/L	20–120
Bilirubin	0.8 mg/dL	0–1.5
Lactate dehydrogenase	372 U/L	100–220
Sodium	140 mmol/L	132–148
Potassium	4.1 mmol/L	3.5–5.0
Chloride	105 mmol/L	98–110
Bicarbonate	24 mmol/L	18–23
Calcium	8.9 mg/dL	8.5–10.5
Hemoglobin	14.9 g/dL	12.0–16.0
Platelets	168 x 10 ⁹ /L	150–400
White blood cell count	11.50 x 10 ⁹ /L	4.0–11.0
Urine total protein	0.24 g/24 hours	0–0.15

of conditions can cause deep venous thrombosis, and all of those listed above deserve consideration. Originally, our patient's physicians felt that the nephrotic syndrome was the root of her problems. However, we need to look deeper to arrive at a unifying diagnosis.

Understanding the cause of deep venous thrombosis

Although the nephrotic syndrome can cause thrombotic events, such complications usually occur only if the serum albumin level is less than 2 g/dL. Such severe hypoalbuminemia leads to decreased levels of antithrombin III and protein C and S, and to hyperfibrinogenemia. However, our patient's albumin level is 2.7 g/dL, making it less likely that the nephrotic syndrome is causing her deep venous thrombosis.

Membranous glomerulonephritis, the cause of the nephrotic syndrome in this patient, can itself cause thrombotic complications. A classic complication of membranous glomerulonephritis is renal vein thrombosis. This condition can present acutely with flank pain, hematuria, and a left-sided varicocele (in men), or it may present chronically and be a cause of recurrent pulmonary emboli. Again, such complications happen primarily when the serum albumin level is less than 2 g/dL.

Membranous glomerulonephritis, in turn, can be caused by a number of conditions, including systemic lupus erythematosus, chronic infections (eg, malaria and hepatitis B), exposure to heavy metals (eg, gold and mercury), drug use, and solid tumors (eg, melanoma, lung cancer, and colon cancer). This information, as well as the patient's history of smoking and a 30-pound weight loss, raise concerns that she might have an underlying malignant disease.

HOSPITAL COURSE

The patient started heparin treatment. Her pulmonary symptoms improved somewhat, but she still required supplemental oxygen from a nasal cannula. Her chest radiographic findings remained unchanged. A review of her records from the other hospital revealed that the infiltrates on the chest roentgenogram had been present for more than 6 weeks.

WHAT DIAGNOSTIC PROCEDURE IS NEEDED?

2 What should the next diagnostic procedure be?

- Hypercoagulability panel
- Bronchoscopy
- Pulmonary angiogram
- CT of the chest
- Thoracentesis

To determine if the patient has a malignant disease of the lung, the next step should be to obtain tissue for a pathologic diagnosis. An argument could be made for performing either a bronchoscopy or a thoracentesis. If a cytologic examination of fluid obtained by thora-



centesis is positive, no other diagnostic test would be necessary, since such a finding would indicate advanced disease.

In this case, a computed tomographic (CT) scan was done first to help guide the pulmonologist in selecting sites for a possible transbronchial biopsy (FIGURE 1). This scan demonstrated atelectasis in the right upper and right middle lobes, with a probable underlying right hilar mass. It also showed evidence of pericardial effusion. A bronchoscopy with transbronchial biopsies and a right thoracentesis were then performed.

Over the 12 hours after the procedure, the patient's systolic blood pressure gradually declined to approximately 80 mm Hg. She received 2.5 L of normal saline intravenously, but her blood pressure did not increase. Another chest roentgenogram was obtained but showed no new findings. An electrocardiogram showed low voltages. Her breath sounds were equal on both sides, her jugular veins were distended, and her heart sounds were distant. She did not require increased oxygen.

■ CAUSES OF HYPOTENSION

3 What is the most likely cause of this patient's hypotension?

- Sepsis
- Recurrent pulmonary embolism
- Cardiac tamponade
- Tension pneumothorax
- Hemothorax

Many conditions can cause hypotension, and all of the above choices deserve consideration, but a number of clues place cardiac tamponade higher on the list: jugular venous distension, distant heart sounds, no radiographic findings suggestive of a tension pneumothorax or hemothorax, and low voltage on the electrocardiogram.

In cardiac tamponade, fluid accumulates in the pericardium, obstructing blood flow into the ventricles. Therefore, intracardiac pressures are elevated, ventricular filling in diastole is limited, and cardiac output is reduced. The amount of fluid required to cause such compromise is related to the suddenness of the accumulation: cardiac tamponade

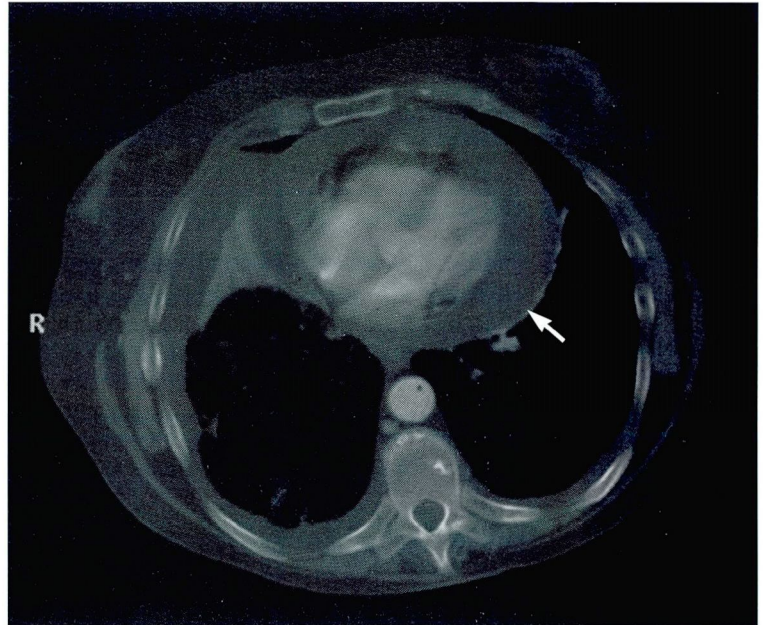


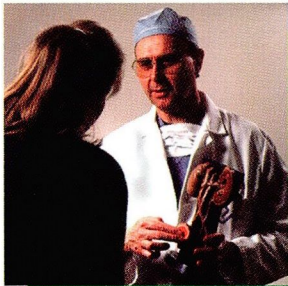
FIGURE 1. Computed tomographic scan of the lungs. This lower cut demonstrates the presence of a pericardial effusion (arrow).

can occur with as little as 200 cc in an acute accumulation. The three most common causes are neoplastic disease, idiopathic pericarditis, and uremia.

Classically, cardiac tamponade presents acutely with hypotension, distant heart sounds, and evidence of increased venous pressure. It can also have an insidious onset and mimic systolic cardiac dysfunction, presenting with dyspnea on exertion, orthopnea, jugular venous distension, and hepatic engorgement. A pulsus paradoxus (ie, an inspiratory decline of more than 10 mm Hg in the systolic blood pressure) is usually found. However, this finding is not specific and can also be seen in constrictive pericarditis, hypovolemic shock, and severe obstructive lung disease. Other clues can include enlargement of the cardiac silhouette on the chest roentgenogram and evidence of low voltage and electrical alternans on the electrocardiogram—electrical alternans of the P, QRS, and T axes is a fairly specific sign.

The diagnostic test of choice is echocardiography, which can help establish the diagnosis, exclude other diagnoses, and guide

Cancer can cause membranous glomerulonephritis, nephrotic syndrome, and deep venous thrombosis






LET US HEAR FROM YOU

- Let us hear your opinions about the *Cleveland Clinic Journal of Medicine*.
- Do you like current articles and sections?
- What topics would you like to see covered and how can we make the Journal more useful to you?

PHONE 216.444.2661
FAX 216.444.9385
E-MAIL ccjm@cesmtp.ccf.org
WWW <http://www.ccf.org/ed/ccjm/ccjhome.htm>


CLEVELAND CLINIC JOURNAL OF MEDICINE
The Cleveland Clinic Foundation
9500 Euclid Avenue, EE37
Cleveland, Ohio 44195



treatment, ie, pericardiocentesis. Our patient underwent echocardiography, which confirmed the diagnosis.

■ CASE RESOLUTION

A pericardiocentesis was performed, 800 cc of bloody fluid was removed, and the patient's hypotension resolved. The transbronchial biopsy findings were positive for poorly differentiated adenocarcinoma, as was a cytologic study of the pleural and pericardial fluid. An oncologist was consulted, and the patient was transferred to the palliative care service; she opted to enter home hospice care and was discharged.

Diagnosis: Membranous glomerulonephritis, recurrent deep vein thrombosis, and cardiac tamponade, all due to metastatic adenocarcinoma of the lung. 

■ SUGGESTED READING

Ball JB, Morrison WL. Cardiac tamponade. *Postgrad Med J* 1997; 73:141-145.

Cattran DC. Cytotoxics, cyclosporine and membranous nephropathy. *Curr Opin Nephrol Hypertens* 1996; 5:427-436.

Hogan SL, Muller KE, Jennette JC, Falk RJ. A review of therapeutic studies of idiopathic membranous glomerulopathy. *Am J Kidney Dis* 1995; 25:862-875.

Mathieson P. Renal disease. II. Membranous nephropathy. *J Royal Coll Physicians* 1997; 31:133-137.

Rosendaal FR. Risk factors for venous thrombosis: prevalence, risk, and interaction. *Semin Hematol* 1997; 34:171-187.

Turkstra F, Koopman MM, Buller HR. The treatment of deep vein thrombosis and pulmonary embolism. *Thromb Haemost* 1997; 78:489-496.

Wilde JT. The investigation of a patient with unexpected venous thrombosis. *Postgrad Med J* 1995; 71:720-724.

ADDRESS: Craig Nielsen, MD, P39, The Cleveland Clinic Foundation, 9500 Euclid Avenue, Cleveland, OH 44195.