

FAYEZ KHEIR, MD

Department of Pulmonary Diseases, Critical Care, and Environmental Medicine, Tulane University Health Sciences Center, New Orleans, LA

ABDUL HAMID ALRAIYES, MD

Department of Pulmonary Diseases, Critical Care, and Environmental Medicine, Tulane University Health Sciences Center, New Orleans, LA

DANIEL SALERNO, MD, MS

Assistant Professor of Clinical Medicine, Department of Pulmonary Diseases, Critical Care, and Environmental Medicine, Tulane University Health Sciences Center, New Orleans, LA

M. CHADI ALRAIYES, MD

Clinical Assistant Professor of Medicine, Cleveland Clinic Lerner College of Medicine of Case Western Reserve University, Cleveland, OH; Department of Hospital Medicine, Cleveland Clinic

The Clinical Picture

Lung air-fluid level in a smoker

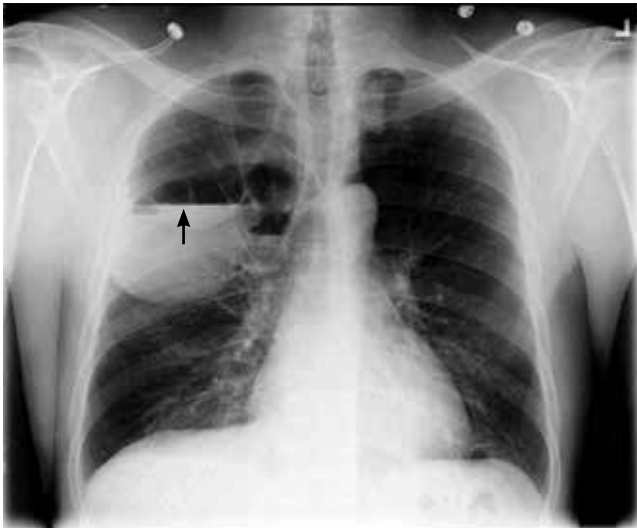


FIGURE 1. Chest radiography (posterior-anterior view) showed bullous disease and a right-sided air-fluid level (arrow).

A 49-YEAR-OLD MAN was referred for evaluation of an abnormal chest radiograph. A 25-pack-year smoker, he had a history of chronic shortness of breath on exertion with occasional coughing and whitish sputum production. He also had a history of hypertension. He had not had hemoptysis, fever, chills, weight loss, or other symptoms, and he had not traveled recently.

On examination, he appeared comfortable. His breath sounds were decreased bilaterally; the rest of his physical examination was normal. His medical history, social history, and review of systems were otherwise unremarkable.

His white blood cell count was $9.4 \times 10^9/L$ (reference range 4.5–11.0), with a normal differential. His hemoglobin concentration was 166 g/L (140–175).

Pulmonary function testing demonstrated moderate obstruction, with the following values:

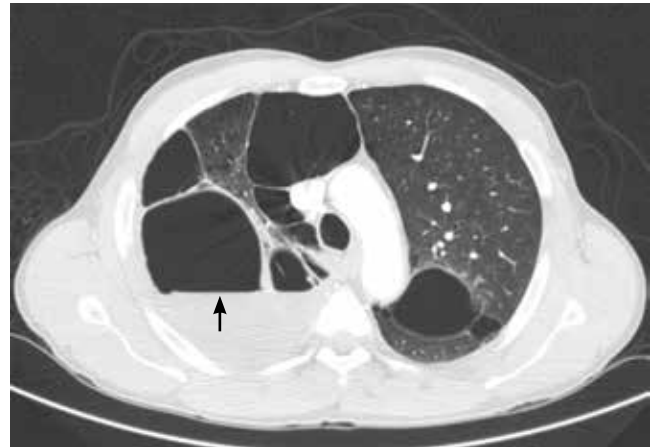


FIGURE 2. Computed tomography of the chest (lung window) showed bilateral bullous disease and a right-sided air-fluid level (arrow).

- Forced expiratory volume in the first second of expiration/forced vital capacity 0.65
- Forced expiratory volume in the first second of expiration 2.40 L (72% of predicted)
- Total lung capacity 7.11 L (92% of predicted)
- Diffusing capacity of lung for carbon monoxide 58% of predicted.

He underwent radiography (**FIGURE 1**) and computed tomography of the chest (**FIGURE 2**).

DIAGNOSIS:
INFECTED EMPHYSEMATOUS BULLAE

The patient had infected emphysematous bullae.

The diagnosis can typically be made by the new development of an air-fluid level in a patient known to have preexisting emphysematous bullae.¹ If previous images are not available, the presence of other bullae in a patient with established chronic obstructive pulmonary disease, a thin-walled cavity, and a disproportionate presentation with impressive radiographic find-

ings along with a subtle clinical picture can support the diagnosis.² In most reported cases, patients are not significantly symptomatic or ill.³ The differential diagnosis includes loculated parapneumonic pleural effusion,⁴ lung abscess,⁵ tuberculosis,⁶ and infected pneumatocele.

Since percutaneous aspiration of the bullae has been discouraged,² the causative organism is often not identified. Also, the role of bronchoscopy in the diagnostic evaluation and treatment of infected emphysematous bullae appears to be limited.⁷

Our patient had minimal symptoms and did not appear ill; he had a relatively unremarkable physical examination, no leukocytosis, and negative blood and sputum cultures, suggesting a benign presentation. In addition, chest radiography a few months before this presentation showed multiple large emphysematous bullae (FIGURE 3). The current chest radiograph suggested multiple thin-walled cavitary lesions with an air-fluid level, which was confirmed on computed tomography.

TREATMENT OF INFECTED EMPHYSEMATOUS BULLAE

Currently, there is no established therapy for infected emphysematous bullae. Because the presentation is usually relatively benign in most case series, conservative treatment with a prolonged course of antibiotics alone seems to be the most appropriate initial course of action. A follow-up evaluation with chest imag-

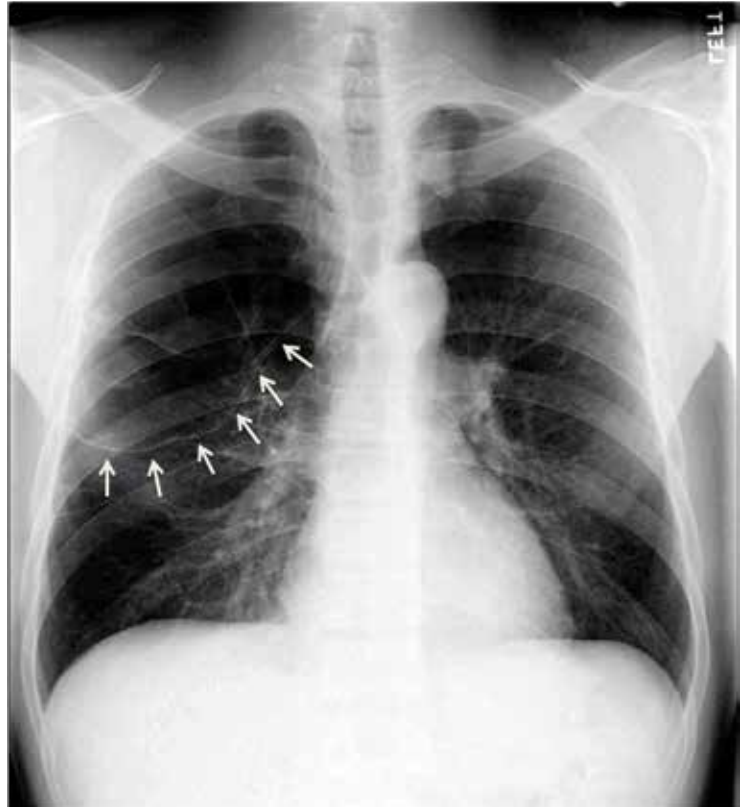


FIGURE 3. The patient's chest radiograph a few months before presentation showed multiple large emphysematous bullae (arrows).

ing is recommended. On the other hand, in patients with worse symptoms, percutaneous aspiration of the bullae should be considered, as it may guide antibiotic therapy.⁸

We started our patient on clindamycin and scheduled him for follow-up chest imaging in 6 weeks. ■

REFERENCES

1. **Burgener FA.** Pulmonary cavitary and cystic lesions. In: Burgener FA, Korman M, Pudas T, editors. *Differential Diagnosis in Conventional Radiology*. 3rd ed. New York, Thieme; 2008: chap.24.
2. **Chandra D, Soubra SH, Musher DM.** A 57-year-old man with a fluid-containing lung cavity: infection of an emphysematous bulla with methicillin-resistant *Staphylococcus aureus*. *Chest* 2006; 130:1942–1946.
3. **Leatherman JW, McDonald FM, Niewohner DE.** Fluid-containing bullae in the lung. *South Med J* 1985; 78:708–710.
4. **Sahn SA.** Diagnosis and management of parapneumonic effusions and empyema. *Clin Infect Dis* 2007; 45:1480–1486.
5. **Hammond JM, Potgieter PD, Hanslo D, Scott H, Roditi D.** The etiology and antimicrobial susceptibility patterns of microorganisms in acute community-acquired lung abscess. *Chest* 1995;108:937–941.
6. **Woodring JH, Vandiviere HM, Fried AM, Dillon ML, Williams TD, Melvin IG.** Update: the radiographic features of pulmonary tuberculosis. *AJR Am J Roentgenol* 1986; 146:497–506.
7. **Chandra D, Rose SR, Carter RB, Musher DM, Hamill RJ.** Fluid-containing emphysematous bullae: a spectrum of illness. *Eur Respir J* 2008; 32:303–306.
8. **Henao-Martinez AF, Fernandez JF, Adams SG, Restrepo C.** Lung bullae with air-fluid levels: what is the appropriate therapeutic approach? *Respir Care* 2012; 57:642–645.

ADDRESS: M. Chadi Alraies, MD, Department of Hospital Medicine, A13, Cleveland Clinic, 9500 Euclid Avenue, Cleveland, OH 44195; e-mail: alraiec@ccf.org