

DAVID L. LONGWORTH, MD, AND JAMES K. STOLLER, MD, EDITORS

An 81-year-old woman with dyspnea on exertion

AN 81-YEAR-OLD WHITE WOMAN reports that she becomes increasingly short of breath during routine activities; this began 1 year ago and has become worse in the last 2 to 3 months. She denies having any fever, cough, chest pain, palpitations, orthopnea, or syncope. She does not smoke, but has had hypertension for the past 27 years and atrial fibrillation that was medically converted to normal sinus rhythm 5 years ago, and has severe kyphoscoliosis due to osteoporosis.

Her medications include long-acting diltiazem (which has been gradually increased to 240 mg daily), hydrochlorothiazide 25 mg daily, potassium chloride 20 mEq daily, and procainamide 250 mg three times a day.

On physical examination her temperature is normal, blood pressure 210/88 mm Hg, heart rate 60, and respiratory rate 16. Fundoscopic examination reveals arteriovenous nicking. The neck is supple without jugular venous distention. The carotid pulses have a bifid quality, a brisk upstroke, a rapid dropoff, and no bruits. The lung sounds are diminished in the bases with fine bibasilar crackles. No wheezing is noted.

Cardiac examination reveals normal first and second heart sounds, and a fourth heart sound. There is a grade 2/6 systolic ejection murmur that is loudest at the apex and radiates to the left axilla and lower left sternal border; it increases in intensity with Valsalva's maneuver. The abdomen is normal. The lower legs have 1+ pitting edema and varicose veins. No clubbing is noted. The neurologic examination is normal. The electrocardiogram reveals sinus bradycardia (a rate of 55 beats per minute), but no

evidence of left ventricular hypertrophy, ischemic changes, or atrial fibrillation. A chest radiograph is normal and shows no vascular redistribution. The percent oxygen saturation (by pulse oximetry, while breathing room air) is 98%.

1 On the basis of the history and physical examination, what is the most likely diagnosis?

- Mitral stenosis
- Aortic stenosis
- Hypertensive hypertrophic cardiomyopathy
- Chronic pulmonary emboli

Hypertensive hypertrophic cardiomyopathy (hypertensive HCM) is the most plausible diagnosis. Hypertensive HCM is distinct from juvenile-type HCM, but the clinical presentation, rather than the pathophysiology, distinguishes the two conditions.

Hypertensive HCM usually occurs in persons older than 60 years, and more often in women and in African Americans. Patients usually have a history of treated hypertension. Common presenting symptoms include pulmonary congestion, angina, and syncope; sudden death is uncommon. In contrast, juvenile-type HCM is seen in younger patients (in their 30s and 40s), often presents as sudden death, and is more common in men.

Myocardial mass is increased in both types of HCM, the left ventricle being more involved than the right. Most patients with juvenile-type HCM

HOW HYPERTENSIVE HYPERTROPHIC CARDIOMYOPATHY OBSTRUCTS THE LEFT VENTRICULAR OUTFLOW TRACT

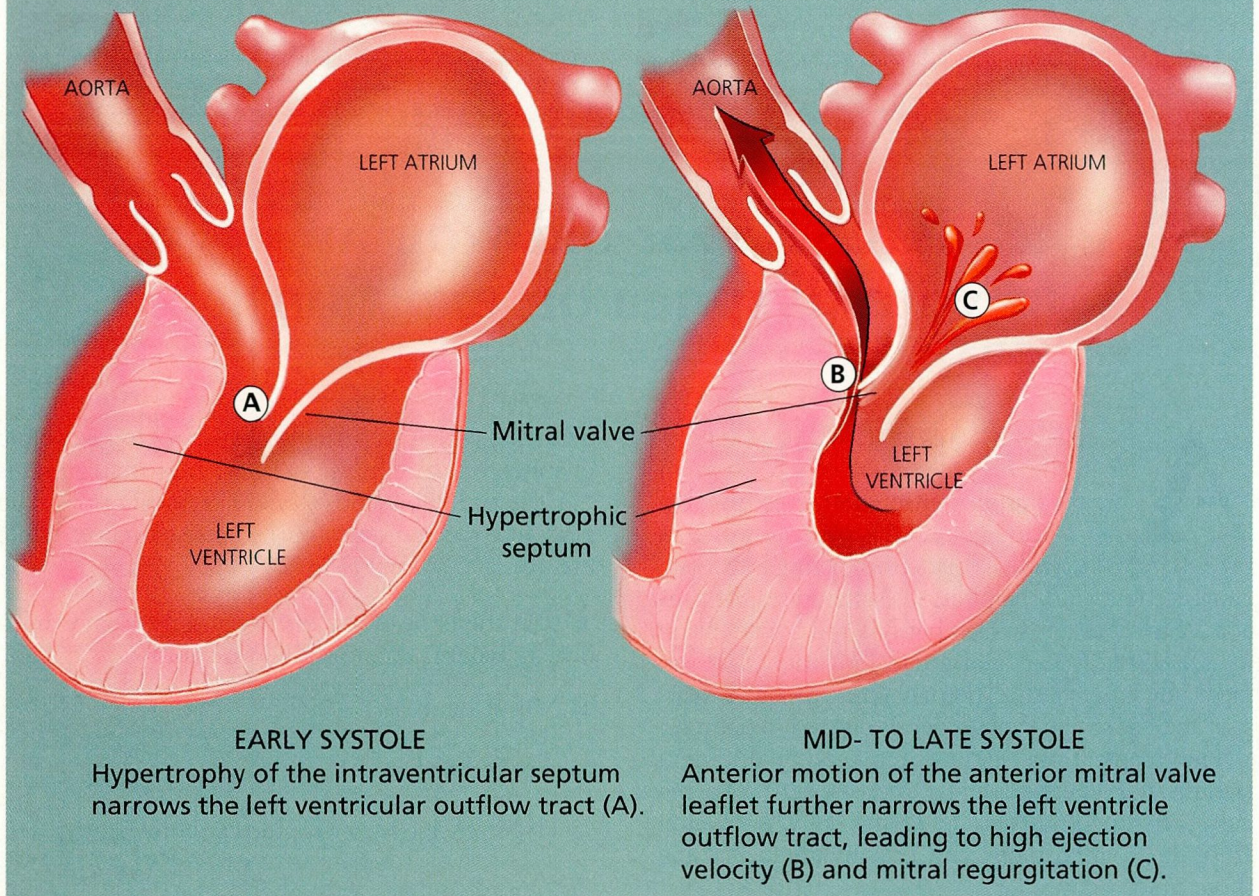


FIGURE.

have disproportionate enlargement of the septum and anterolateral wall, while most patients with hypertensive HCM have concentric left ventricular hypertrophy. Obstruction results when hypertrophy of the septum and anterior displacement of the mitral leaflets narrow the left ventricular outflow tract; the latter also results in mitral regurgitation (Figure). However, HCM can also be nonobstructive, with normal systolic function but impaired relaxation of the left ventricle.

In both types of HCM (juvenile and hypertensive), left ventricular function is abnormal. Diastolic dysfunction appears first, as impaired relaxation and decreased ventricular compliance increase the filling pressure, despite normal or small left ventricular cavity size. Only late in the disease process does systolic dysfunction appear.

SIGNS AND SYMPTOMS OF HCM

The clinical picture in HCM varies considerably; patients may have no symptoms at all or be severely ill. The most common symptoms include dyspnea (in 75% of patients, caused by increased left ventricular end-diastolic pressure); angina (in 66%, caused by myocardial ischemia due to impaired left ventricular relaxation, increased left ventricular filling pressures, small-vessel disease of the intramural coronary arteries, increased oxygen demand, and left ventricular outflow tract obstruction); and presyncopal and syncopal symptoms (caused by either atrial or ventricular arrhythmias or left ventricular outflow obstruction). Congestive heart failure is seen more frequently in hypertensive HCM than in juvenile-type HCM.

The apical systolic murmur of mitral regurgitation is characteristic of HCM. Patients with obstruction of the left ventricular outflow tract at rest usually have a louder murmur (> grade 3/6) than do patients without obstruction or with only latent obstruction. Valsalva's maneuver accentuates the murmur, while maneuvers such as handgrip that increase afterload reduce its intensity.

As for the other diagnoses listed above, in aortic stenosis, the carotid pulse has a slow upstroke and a low amplitude, while in HCM, it has a rapid upstroke and a quick falloff. Chronic pulmonary embolism is unlikely in this patient, since venous varicosities are her only risk factor for deep venous thrombosis. In addition, pulmonary embolism would not explain the quality of the arterial pulses or the heart murmur. Finally, mitral stenosis presents with a diastolic murmur, but this patient has a systolic murmur.

2 Which of the following is *not* a risk factor for sudden death in patients with HCM?

- History of syncope
- Nonsustained ventricular tachycardia on Holter monitoring
- Family history of HCM
- Older age at time of diagnosis
- Sustained ventricular tachycardia

Older age at the time of diagnosis is not a risk factor for sudden death; in fact, persons younger than 30 years are at higher risk. In younger adults, the most reliable marker for increased risk is nonsustained ventricular tachycardia on 48-hour Holter monitoring. Because death often occurs during exercise, isometric exercise should be prohibited in all patients with HCM.

This patient underwent echocardiography, which demonstrated a normal left ventricle, moderate concentric hypertrophy, and a large septal bulge. Systolic left ventricular function was normal. The left ventricular outflow tract was normal at rest, but the pressure gradient increased to more than 100 mm Hg with amyl nitrate inhalation. The right ventricle and both atria were normal. There was trivial mitral regurgitation and aortic insufficiency; aortic sclerosis was present.

3 What is the next step in the care of this patient?

- Increase the dosage of diltiazem
- Increase the dosage of the thiazide diuretic
- Discontinue diltiazem and the thiazide diuretic and add a beta blocker
- Consult a cardiothoracic surgeon for possible septal myectomy

TREATING HCM

Echocardiography can differentiate the various forms of cardiomyopathy and also the three subgroups of patients with HCM: those with latent obstruction of the outflow tract, those with obstruction at rest, and those with no obstruction. A practical approach to treating HCM is based on these hemodynamic subgroupings.

Patients with latent obstruction

This patient's echocardiogram demonstrated a latent obstruction that could be induced by amyl nitrate, and for her, discontinuing diltiazem and the thiazide diuretic and adding a beta blocker would be the best next step.

Approximately one third of patients enjoy a prolonged decrease in symptoms in response to a beta blocker. Beta blockers do not always affect the severity of obstruction, but they prevent further obstruction during exercise (by decreasing the force of contraction), improve the diastolic function of the left ventricle (by increasing the filling time), and can relieve symptoms of angina, dyspnea, and presyncope.

Another option, though very controversial, is dual-chamber pacing. The mechanism by which this therapy decreases the pressure gradient across the outflow tract is uncertain but may be related to decreased septal motion and left ventricular contractility. Surgery and disopyramide therapy are other alternatives, though they are rarely needed. Dihydropyridine calcium channel blockers are generally avoided because they may induce vasodilation, which may increase the obstruction, resulting in death.

Patients with obstruction at rest

Approximately two thirds of patients with obstruction at rest experience an increase in exercise

capacity with therapy with a beta blocker or verapamil, a nondihydropyridine calcium antagonist that, like beta blockers, has a negative inotropic effect. Verapamil appears to improve diastolic filling by improving ventricular relaxation, as evidenced by reduced filling pressures. However, it must be used with caution: by decreasing sinus node automaticity, dilating peripheral arterioles, and decreasing the force of cardiac contraction, it can precipitate hypotension, pulmonary edema, and death.

If medical therapy fails, surgical septal myectomy is appropriate. Other indications for surgery include atrial fibrillation in young patients, unexplained syncope, and cardiac arrest. The 1-year postoperative mortality rate is between 1% and 2%.

Patients without obstruction

Either verapamil, diltiazem (another nondihydropyridine calcium antagonist), or a beta blocker can be used in patients with nonobstructive HCM, who have normal systolic function and impaired relaxation of the left ventricle. If the initial drug produces a suboptimal effect, a combination of a calcium antagonist and beta blocker can be tried.

Diuretics decrease preload and ventricular filling pressures, which can lead to increased obstruction. They are reserved for patients with severe symptoms of congestive heart failure, in whom they should be used cautiously as an adjunct to a beta blocker or a calcium antagonist.

4 Should this patient be advised about prophylaxis against spontaneous bacterial endocarditis?

Endocarditis has been linked to HCM, and this patient should receive amoxicillin 3.0 g by mouth 1 hour before undergoing any dental work, and 1.5 g 6 hours afterward. The incidence of spontaneous bacterial endocarditis after a high-risk procedure is 3% in patients with resting obstruction. If endocarditis does develop, it is most commonly found on the mitral and aortic valves or on the subaortic endocardium at the level of the mitral leaflet. Management of spontaneous bacterial endocarditis in patients with HCM is the same as in patients with other types of heart disease that predispose to endocarditis.

5 Should this patient be evaluated for asymptomatic ventricular tachycardia by 48-hour Holter monitoring?

This is not necessary. Up to 36% of patients with HCM may have asymptomatic ventricular tachycardia, but only a subgroup require diagnostic evaluation. Patients at increased risk include those with resting obstruction, history of syncope or palpitations, or family history of sudden death. There is no consensus regarding the treatment of patients with triplets of ventricular tachycardia or prolonged episodes of asymptomatic ventricular tachycardia. Treatment for sustained or symptomatic ventricular tachycardia requires an electrophysiological evaluation.

BARBARA WILLIAMS, MD
J. HARRY ISAACSON, MD
Department of Internal Medicine
MICHAEL S. LAUER, MD
Department of Cardiology
The Cleveland Clinic Foundation

SUGGESTED READING

- Davies MJ, McKenne WJ. Hypertrophic cardiomyopathy: an introduction to pathology and pathogenesis. *Br Heart J* 1994; **72**(6 Suppl):S2-S3.
- Fananapazir L, Epstein N. Prevalence of hypertrophic cardiomyopathy and limitation of screening methods. *Circulation* 1995; **92**:700-704.
- Maron BJ, Cecchi F, McKenna W. Risk factors and stratification for sudden cardiac death in patients with hypertrophic cardiomyopathy. *Br Heart J* 1994; **72**(6 Suppl):S13-S18.
- Sasson Z, Rakowski H, Wigle ED. Hypertrophic cardiomyopathy. *Cardiology Clin* 1988; **6**:233-280.
- Saumaez R. Electrophysiological investigation of patients with hypertrophic cardiomyopathy. *Br Heart J* 1994; **72**(6 Suppl):S19-S23.
- Spirito P, Bellone P. Natural history of hypertrophic cardiomyopathy. *Br Heart J* 1994; **72**(6 Suppl):S10-S12.
- Topol EJ, Traill T, Fortuin N. Hypertensive hypertrophic cardiomyopathy of the elderly. *N Engl J Med* 1985; **313**:277-283.
- Vasan RS, Benjamin CJ, Levy D. Congestive heart failure with normal left ventricular systolic function: Clinical approaches to the diagnosis and treatment of diastolic heart failure. *Arch Intern Med* 1996; **156**:146-157.
- Watkins H. Multiple disease genes cause hypertrophic cardiomyopathy. *Br Heart J* 1994; **72**(6 Suppl):S4-S9.
- Wigle E, Rakowski H, Kimball B, et al. Hypertrophic cardiomyopathy: Clinical spectrum and treatment. *Circulation* 1995; **92**:1680-1692.
- Wynne J, Braunwald EB. Hypertrophic cardiomyopathy. In: Braunwald EB, editor. *Heart disease: a textbook of cardiovascular medicine*. Philadelphia: W.B. Saunders; 1992:1404-1415.