

---

## H. RALPH SCHUMACHER, Jr, MD

Professor of Medicine, University of Pennsylvania,  
Philadelphia, PA

# The pathogenesis of gout

## ■ ABSTRACT

An elevated serum urate level, together with local factors, can result in the deposition of urate crystals into the joints. Once crystals are deposited into a joint, they can be released into the joint space and initiate an inflammatory cascade causing acute gouty arthritis. These acute flares resolve, but the crystals remain in the joint. The way to ultimately correct the underlying metabolic problem of hyperuricemia and the crystal deposition is to lower the serum urate level and dissolve the crystal deposits. This will stop both the acute attacks and the progressive joint damage.

## ■ KEY POINTS

A serum urate level of approximately 6.8 mg/dL is the concentration at which urate crystals begin to precipitate. The higher the urate level, the more likely that crystals will deposit into joints.

---

Local factors that combine with hyperuricemia to contribute to the development of gout are trauma, irritation, reduced temperature, and prior joint disease.

---

Because acute attacks of gout typically resolve spontaneously, especially early in the disease course, evaluating the efficacy of acute therapies can be difficult.

---

Lowering the serum urate to less than 6 mg/dL will dissolve crystals out of the joints, ultimately preventing acute gout attacks and joint damage.

**A** serum urate level greater than approximately 6.8 mg/dL, the saturation point of urate in biological fluids, is the underlying cause of gout. Hyperuricemia, along with other factors (detailed below), over time can result in the deposition of monosodium urate crystals into the joints. Gouty attacks are thought to occur by the abrupt release of

these crystals into the joint space, where they may initiate an acute inflammatory reaction recognized as acute gouty arthritis. The acute attack is self-limited, but crystals remain in the joint and low-grade, often subclinical, inflammation persists even between acute attacks. Although acute attacks can be treated with anti-inflammatory medications, the underlying cause of the disease can be treated only by lowering the serum urate level.

## ■ CRYSTAL DEPOSITION AND THE DEVELOPMENT OF GOUT

Asymptomatic hyperuricemia is not a disease but rather is the underlying factor that can predispose to gout. A serum urate level of approximately 6.8 mg/dL is the concentration at which monosodium urate crystals begin to precipitate.<sup>1,2</sup> Although this level is based on in vitro studies, it suggests a reasonable biological threshold for clinicians assessing patients for hyperuricemia. It should be noted that there are often no manifestations of gout during an extended period of hyperuricemia even though urate crystals are beginning to deposit into joints. The higher the serum urate level, the more likely that crystals will deposit into joints.

### Predisposition is not causation

In the Normative Aging Study, 22% of men who had serum urate levels greater than 9 mg/dL developed gout during a 5-year period—a much higher rate than among men with serum urate levels less than 9 mg/dL.<sup>3</sup> Nevertheless, a full 78% of the men in this study with serum urate levels greater than 9 mg/dL did not develop gout over the 5-year period, illustrating that while hyperuricemia predisposes to gout, it does not automatically cause gout.

### Contributing factors beyond serum urate

Other factors, when combined with hyperuricemia, contribute to crystal deposition and the development of gout.

**Trauma or irritation.** Patients with hyperuricemia tend to have monosodium urate crystal deposition at

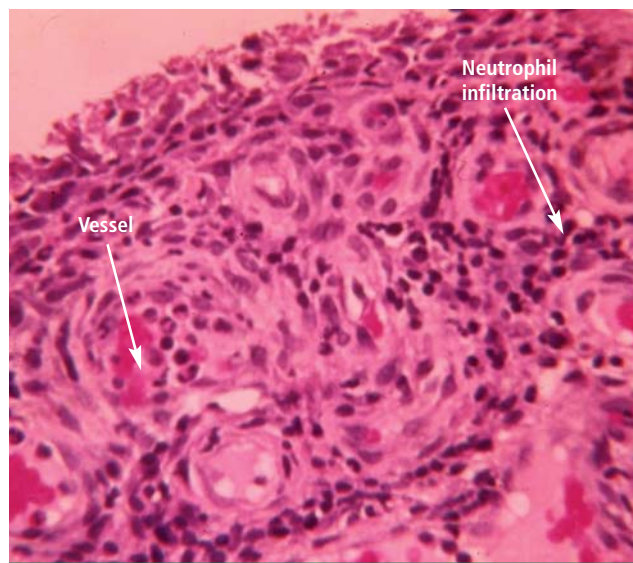---

Dr. Schumacher reported that he has received research grant support and consulting/advisory fees from TAP Pharmaceutical Products and Savient Pharmaceuticals as well as consulting/advisory fees from Pfizer, Regeneron, and Xoma.

Dr. Schumacher received honoraria for participating in the symposium that formed the basis of this supplement and for writing this article. The honoraria were paid by Fallon Medica LLC, a medical communication company, on behalf of TAP Pharmaceutical Products, the underwriter of this supplement. TAP had no

input on the content of presentations at the symposium or on this article.

This article is based on Dr. Schumacher's lecture on this subject at the symposium that formed the basis of this supplement. Dr. Schumacher reported that he prepared his lecture, Fallon Medica transcribed his lecture, and he alone developed the transcript into this article without assistance from undeclared contributors. The article underwent formatting and nonsubstantive copyediting by Fallon prior to submission to the *Journal*.



**FIGURE 1.** Synovial tissue of a patient with acute gout. Note the dilated vessels, representing the throbbing, hot, erythematous joint, and the large numbers of neutrophils.

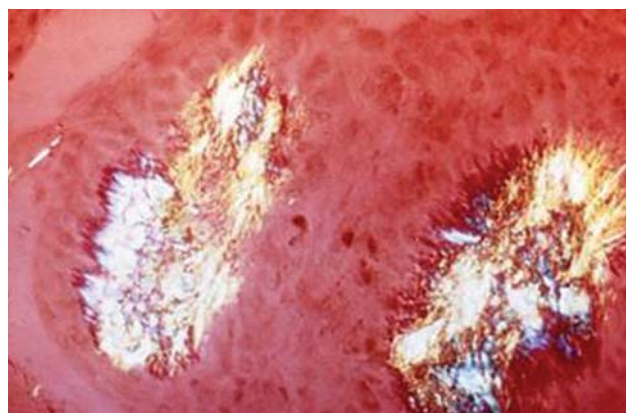
sites of trauma or irritation. The first metatarsophalangeal joint is often affected, at least in part because it is a site of mechanical stress. Likewise, mechanical irritation from leaning on the elbow may cause crystals to deposit in the olecranon bursa.

**Lower temperatures** favor crystal deposition,<sup>1,4</sup> which may explain why the helix of the ear and the foot are often sites of crystal deposition and tophus development. Both temperature and mechanical effects probably play a role in crystal deposition, however, as gouty attacks tend to occur at the first metatarsophalangeal joint, not at the interphalangeal joints of the foot, which are at a lower temperature.

**Previous disease.** Crystals also deposit with an increased incidence in previously diseased joints. The Heberden node is a good example.<sup>5</sup> A patient with osteoarthritis in the fingers may experience dramatically increased pain and swelling because of a gout flare superimposed on an osteoarthritic joint.

## ■ ACUTE GOUTY ARTHRITIS

In some patients, the deposited monosodium urate crystals will be released into the joint space and cause the dramatic acute inflammatory response of acute gouty arthritis. Crystals are believed to be released either by some metabolic change, such as an increase or decrease in serum urate level, or by mechanical trauma. In the joint space, synovial lining cells appear to be the first to phagocytize the crystals.<sup>6</sup> This sets into motion the formation of a complex called the inflammasome, which releases IL-1 beta, one of the most important mediators



**FIGURE 2.** The synovium between acute gout attacks, viewed under polarized light. Two small micro-topi and mononuclear cells are apparent, but there is no acute inflammatory response.

of the acute attack.<sup>7</sup> It stimulates the release of chemokines, other cytokines, prostaglandins, and a variety of other proinflammatory molecules.<sup>8</sup> The chemokines attract neutrophils into the synovial tissue and the synovial fluid. Neutrophil influx into the joint is a key feature of an acute attack of gout (**Figure 1**).

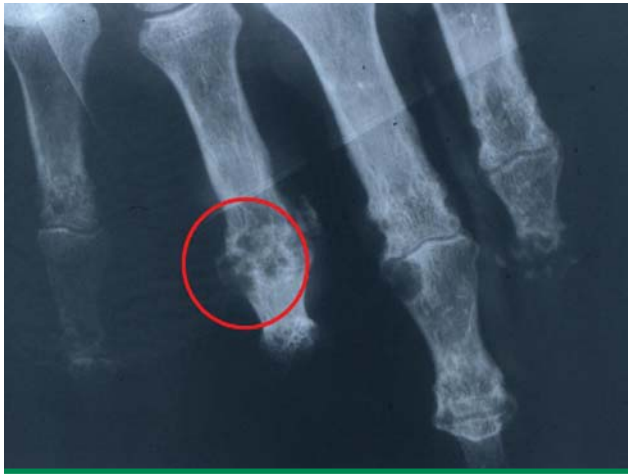## Gout flares may resolve spontaneously

Clinicians should be aware that gout attacks initially subside spontaneously.<sup>9</sup> Because acute attacks of gout typically resolve with or without treatment, especially early in the course of the disease,<sup>10</sup> it can be difficult to evaluate which treatments actually are effective against acute attacks.

A number of factors have been identified to explain how inflammation in acute attacks can be spontaneously suppressed. Crystals may dissolve or become sequestered in the tissue. Monocytes mature into macrophages, changing their responsiveness to urate crystals, and can begin to produce anti-inflammatory cytokines. In addition, some proteins that exude into the joint space with the attack, such as apolipoprotein B, can coat the crystals and reduce their inflammatory properties.<sup>11</sup>

## Crystals persist during intercritical periods

Following an acute attack, the symptoms of gouty arthritis may be gone, but the crystals are still present in the joint. Therefore, the patient remains at risk for continued flares and progressive disease.<sup>12</sup> The crystals that remain in the joint are often associated with a low-grade persistent inflammation.<sup>13</sup> It is not known why these crystals that remain in the joint fluid between attacks, some of which are phagocytized by white cells, do not initiate the whole cascade of inflammation. The reason may be related to the number of crystals present, their protein coating, or the nature of the resident synovial cells. Crystals may also persist as micro-topi in the synovium (**Figure 2**). The



**FIGURE 3.** Large, cystic joint erosions producing an overhanging edge (circled area) characteristic of chronic gouty arthritis.

key point is that low-grade inflammation persists and crystals remain in the joint, which can lead to progressive disease.<sup>14</sup>

### ■ ADVANCED GOUT

Clinicians treating patients with gout need to prevent the development of chronic, destructive arthritis and the overt, large tophaceous deposits of advanced gout. Over time, even in the absence of flares, deposited crystals and inflammation can lead to the development of clinically evident joint damage and erosions that can be seen on radiographs (Figure 3) or magnetic resonance imaging.<sup>15</sup>

### ■ INTERVENTIONS MUST NORMALIZE URATE LEVEL

Acute gout attacks can be treated with anti-inflammatory drugs, but the disease can and often will continue to progress unless the serum urate level is normalized. Two studies of patients whose serum urate levels were successfully reduced to less than 6 mg/dL showed that crystals began to be depleted from the patients' joint fluid, which should ultimately prevent the risk of progressive gouty arthritis.<sup>12,16</sup> Perez-Ruiz and colleagues have shown that tophi can be dissolved by decreasing the serum urate level.<sup>17</sup> When tophi are present, aiming for even lower levels of serum urate, such as 4 to 5 mg/dL, may help to promote more rapid dissolution of crystals.<sup>17</sup>

### ■ REFERENCES

1. Loeb JN. The influence of temperature on the solubility of monosodium urate. *Arthritis Rheum* 1972; 15:189–192.
2. Kippen I, Klinenberg JR, Weinberger A, Wilcox WR. Factors affecting urate solubility in vitro. *Ann Rheum Dis* 1974; 33:313–317.
3. Campion EW, Glynn RJ, DeLabry LO. Asymptomatic hyperuricemia. Risks and consequences in the Normative Aging Study. *Am J Med* 1987; 82:421–426.
4. Scott JT. New knowledge of the pathogenesis of gout. *J Clin Pathol Suppl (R Coll Pathol)* 1978; 12:205–213.
5. Terkeltaub RA. Pathogenesis of gouty inflammation. In: Klippel JH, Crofford LJ, Stone JH, Weyand CM, eds. *Primer on the Rheumatic Diseases*. 12th ed. Atlanta, GA: Arthritis Foundation; 2001: 311–312.
6. Schumacher HR Jr, Wortmann RL. The pathology of crystal-induced arthropathies. In: Wortman RL, Schumacher HR Jr, Becker MA, Ryan LM, eds. *Crystal-Induced Arthropathies*. New York, NY: Taylor & Francis Group; 2006:291–319.
7. Martinon F, Glimcher LH. Gout: new insights into an old disease. *J Clin Invest* 2006; 116:2073–2075.
8. Chen CJ, Shi Y, Hearn A, et al. MyD88-dependent IL-1 receptor signaling is essential for gouty inflammation stimulated by monosodium urate crystals. *J Clin Invest* 2006; 116:2262–2271.
9. Landis RC, Yagnik DR, Florey O, et al. Safe disposal of inflammatory monosodium urate monohydrate crystals by differentiated macrophages. *Arthritis Rheum* 2002; 46:3026–3033.
10. Yagnik DR, Evans BJ, Florey O, Mason JC, Landis RC, Haskard DO. Macrophage release of transforming growth factor beta1 during resolution of monosodium urate monohydrate crystal-induced inflammation. *Arthritis Rheum* 2004; 50:2273–2280.
11. Cherian PV, Schumacher HR Jr. Immunochemical and ultrastructural characterization of serum proteins associated with monosodium urate crystals (MSU) in synovial fluid cells from patients with gout. *Ultrastruct Pathol* 1986; 10:209–219.
12. Li-Yu J, Clayburne G, Sieck M, et al. Treatment of chronic gout. Can we determine when urate stores are depleted enough to prevent attacks of gout? *J Rheumatol* 2001; 28:577–580.
13. Pascual E, Pedraz T. Gout. *Curr Opin Rheumatol* 2004; 16: 282–286.
14. Pascual E, Batlle-Gualda E, Martinez A, Rosas J, Vela P. Synovial fluid analysis for diagnosis of intercritical gout. *Ann Intern Med* 1999; 131:756–759.
15. Dalbeth N, Clark B, Gregory K, Sheehan T, McQueen F. Clinical images: three-dimensional computed tomography imaging of tophaceous gout. *Arthritis Rheum* 2007; 56:29.
16. Pascual E, Sivera F. Time required for disappearance of urate crystals from synovial fluid after successful hypouricemic treatment relates to the duration of gout. *Ann Rheum Dis* 2007; 66: 1056–1058.
17. Perez-Ruiz F, Calabozo M, Pijoan JI, Herrero-Beites AM, Ruibal A. Effect of urate-lowering therapy on the velocity of size reduction of tophi in chronic gout. *Arthritis Rheum* 2002; 47:356–360.

**Correspondence:** H. Ralph Schumacher, Jr, MD, VA Medical Center, 151K, University and Woodland Avenues, Philadelphia, PA 19104; schumacr@mail.med.upenn.edu.