EXFOLIATIVE CYTOLOGY AS AN AID TO THE DIAGNOSIS OF GASTRIC CARCINOMA

A Preliminary Analysis of 116 Cases

EDWARD J. KURT, M.D.,* CHARLES H. BROWN, M.D.,
Department of Gastroenterology

LAWRENCE J. McCORMACK, M.D., JOHN B. HAZARD, M.D.,

and

DORIS BELOVICH, B.S.
Department of Anatomic Pathology

GASTRIC carcinoma is increasingly important because of the diagnostic and the therapeutic problems it raises and the high annual mortality—40,000 persons[1]—in this country. Because of this high mortality many surgeons advocate drastic surgical therapy for all potentially malignant lesions in the stomach. Ochsner and Blalock[2] believed that all gastric ulcers should receive surgical treatment, and warned of the great responsibility assumed by the physician who institutes conservative treatment of an ulcerative gastric lesion. Ravdin[3] and others are of a like opinion.

The reported five-year survival rate for all patients having carcinoma of the stomach has varied from 1 to 15 per cent.[4,5] The Cleveland Clinic rate for the years 1940 through 1945 was 7.1 per cent. With the more frequent and, at times, extensive resections being performed for the past 10 years, a greater number of patients are selected for operation and the five-year survival rate should be higher.[6-8] For a personal series of 53 patients with gastric carcinoma who underwent gastric resections for cure, Hoerr,[9] at the Cleveland Clinic, has had a five-year survival rate of 36 per cent.

The low survival values have been thought to result, in part at least, from the difficulty of obtaining an early diagnosis. Certainly, the detection of the disease at a stage when more favorable resections can be performed is dependent upon its recognition before metastasis or marked local extension occurs. Routine screening by roentgen examination of the stomach, as done on 7,500 patients at Johns Hopkins Hospital and on 7,500 control subjects in North Carolina[10] (screening program sponsored by the American Cancer Society), proved the procedure to be impractical. Obviously there is great need of a method for earlier diagnosis of gastric carcinoma.

In addition, there is need of a more accurate method of diagnosis of gastric carcinoma. The accuracy of roentgen diagnosis in most centers is from 60 to 70 per cent, while that of gastroscopy usually is less. The accuracy of combined roentgen and gastroscopic examinations is higher—approximately 80 per cent.

Our interest in improving diagnostic accuracy led us to use exfoliative gastric cytology as a diagnostic approach. Raskind,[11] Rubin, Klayman, and

**Formerly Fellow in the Department of Gastroenterology; present address: 3140 Dorr St., Toledo, Ohio.*

Kirsner,[12] and Klayman and associates[13] reported greater than 90 per cent accuracy of exfoliative cytology in the diagnoses of more than 1,700 patients. At The University of Chicago Clinics the surgeons have such confidence in the findings on gastric cytology that in several patients they have resected the stomach on the basis of the cytologic report alone, even though all other preoperative findings and the stomach itself grossly at operation appeared normal. In those few patients, pathologic examination of the resected specimen revealed a barely discernible lesion.

Gastric cytology was used half a century ago, but it did not become clinically dependable until recently. This procedure has evolved from simple aspiration of gastric contents with smears being made for cytologic evaluation; to mechanical abrasion of the gastric walls with ingeniously devised balloons and brushes;[14-18] to gastric lavage with mucolytic agents such as papain[16] and chymotrypsin;[13,19] to a simple gastric lavage technic using an acetate buffer solution.

Initial attempts at cytologic evaluation by simple smears of gastric contents failed because of the overabundance of debris, and autolysis of cells by the enzymatic content of gastric juice. The various abrasive technics have not been satisfactory, in our opinion, because of the difficulty in placing the abrasive balloon and also the uncertainty that the appropriate areas were reached by the instrument; antral lesions particularly are difficult to diagnose by these technics. Three years ago Rossmiller[20] undertook the use of the Ayre brush technic in approximately fifty cases. Results were so consistently incorrect that the procedure was abandoned.

Technic

Our exfoliative cytologic technic involves no special equipment, and the financial cost to the patient is moderate. The equipment consists of a plastic disposable Levin tube, an Asepto aspirating syringe, a 100-ml. plunger type of syringe, a few lengths of rubber hose, a sink aspirator (mechanism of the type commonly employed in a laboratory), a bucket, and a supply of ice.

The patient is prepared by fasting from midnight before the test, except that he is encouraged to drink water. He is intubated orally with a standard disposable plastic Levin tube. Contrary to the recommendations of some,[21] we do not use an Ewald tube, or prepare the patient with barbiturates, narcotics, or topical anesthetics. When the Levin tube is properly placed, it is secured with adhesive tape and the stomach is aspirated. This fasting aspirate is not used for smears,[21] but is discarded. The stomach is then washed with from 500 to 1,000 ml. of tepid tap water in 100-ml. amounts and each of these aspirates is discarded. This lavage rids the stomach of much debris and permits making much "cleaner" slides. The lavage is discontinued when the aspirated solution becomes practically crystal clear, and 500 ml. of acetate buffer solution is immediately introduced into the stomach. The Levin tube is then clamped and the patient is rotated 360 degrees during a 10-minute period. After this rotation, the Levin tube is connected to a sink aspirator through a bypass 500-ml. flask

that has been packed in ice and has been chilling since the start of the procedure to slow down cellular digestion. The solution is then removed in its greatest amount, usually from 200 to 300 ml. which, with the sink aspirator, requires approximately five minutes. This collection constitutes the "total buffer" solution which is centrifuged. Slides are prepared of the pooled sediment.

After the collection of the "total buffer" solution, the Levin tube is connected to a 100-ml. syringe. The "last drop" of solution is recovered after repeated flushing of the stomach with the residual fluid. This collection usually amounts to from 20 to 30 ml. of specimen, the richest in cellular content. After this last collection the Levin tube is withdrawn and discarded. The specimen is transmitted to the Cytology Laboratory in a bucket of ice.

The securing of the specimen requires from 15 to 20 minutes. We have noted no cellular degeneration as a result of the few minutes' delay involved in transporting the specimen to the laboratory; we believe that this is most important because it eliminates the need for centrifuging the specimen and preparing the slides at the site of collection. A technician does not collect the specimen; we believe that only the physician who is familiar with gastric carcinoma can give the attention so necessary for obtaining a satisfactory specimen. When the collection of the cellular specimen is made by a physician, as in the study reported here, and is delivered as an unknown to the cytopathologist, there can be no subjective influence on the interpretation of the cellular forms.

After we had used the procedure in a few cases, we found that more satisfactory material could be obtained with the use of the simple acetate buffer solution than with the acetate buffer with chymotrypsin[19] added as a mucolytic agent. Our cellular collections have been better with the acetate buffer solution than with the plain saline solution. We have noted, as have others, that the acetate buffer solution develops a sediment after standing for some time. Others[21] have filtered the solution. We found this sediment to be a mold that can be avoided by proper refrigeration that preserves the acetate buffer solution for an indefinite period without sediment.

Results

During the nine-month period from September, 1957, to June, 1958, 116 consecutive patients underwent exfoliative cytology. Although this group is not sufficiently large nor is the follow-up (of patients not operated upon in whom the cytologic findings were negative) sufficiently long to be of statistical value, the results are indicative.

In 79 of the 116 patients, the cytologic findings were negative and no operation was performed. In none of these patients were there any clinical (including roentgen) indications of malignancy. Many of the examinations were performed as controls to improve our cytologic technic and methods. Twenty-four of the 79 patients had gastric ulcers that were thought to be benign clinically, were associated with ample gastric acidity, and appeared benign on roentgenography; progress roentgen examinations in these patients have shown the gastric ulcers to have healed completely. Progress cytologic studies can give

added reassurance to the clinician treating a gastric ulcer that appears entirely benign clinically, gastroscopically, and roentgenographically. Cytologic studies were done in some patients who had received cobalt-60 teletherapy for complicated peptic ulcer,[22] but in whom there was no evidence of neoplasm.

Thirty-seven of the 116 patients have been operated upon. It must be noted that the cytologic studies of these patients include first efforts with this technic. Most patients were chosen for cytologic examination because they had some type of gastric abnormality that on the basis of other findings might require surgical treatment.

In Table 1 the rates of accuracy of the findings by exfoliative cytology and roentgenography in the 37 patients who underwent operation are compared,

Table 1. — *Comparison of accuracy of findings by exfoliative cytology and by roentgenography in 37 patients*

Pathologic diagnosis, number of patients		Cytologic diagnosis		Roentgen diagnosis		
		Inaccurate, number of patients	Accurate, number of patients	Inaccurate, number of patients	Accurate, number of patients	Indeterminate, number of patients
Benign lesions	23	2	21 (91%)	7	14 (64%)	2
Malignant lesions	14	1	13 (92.9%)	0	12 (86%)	2
Total	37	3	34 (92%)	7	26 (70%)	4

and in Table 2 the gastroscopic findings are summarized. The one falsely negative cytologic report was on a patient with widespread carcinoma of the stomach with extension into the distal esophagus. The Levin tube could not be

Table 2. — *Gastroscopic findings in nine patients with carcinoma*

Findings	Number of patients
Accurate	7
Unsatisfactory examination (considered erroneous diagnosis)	1
Inaccurate (benign lesion reported as carcinoma)	1

well placed because of some esophageal obstruction, and the collection of material was not rigidly controlled. This falsely negative report is considered to have resulted from poor collection technic rather than from improper cytologic evaluation. Gastric cells were not present on the slides. Because of

this experience our cytologists now indicate whether or not gastric cells are present for evaluation.

In the series there was a total of 15 patients on whom reports were rendered. There were two falsely positive cytologic reports on washings for patients with clinically active gastric ulcers that had been considered benign by conventional evaluation. Both of these patients were operated upon and specimens from each showed dysplastic changes; one patient had received cobalt-60 teletherapy (Case 4).

Illustrative Cases

Case 1. A 66-year-old man was examined in November, 1957, because of epigastric distress of two weeks' duration. The pain had its onset after meals and was relieved by food or alkali. He had had arteriosclerotic heart disease, old posterior myocardial infarction, and angina pectoris. Roentgen examination of the stomach showed an ulcer crater in the fundus with some rigidity of the wall of the distal portion with a lack of peristalsis in the antrum, indicating the possibility of neoplasm (Fig. 1). A hemogram was normal. On gastric analysis after alcohol stimulation, there was 18 units of free hydrochloric acid. Exfoliative gastric cytology showed no tumor cells.

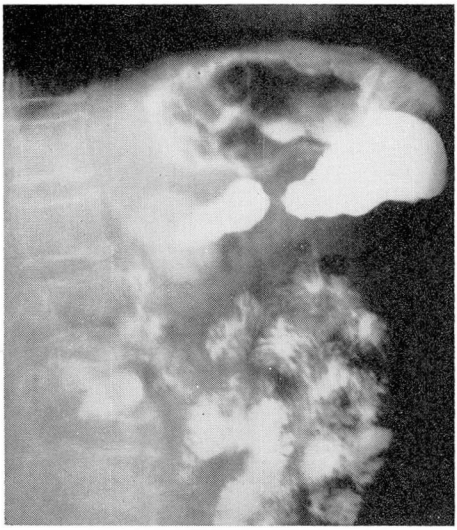

Fig. 1. (Case 1.) Roentgenogram shows ulcer crater in the fundus and some narrowing and irregularity of the antrum. Although cytologic findings were normal, operation was advised because of the appearance of the antrum and the ulcer. Histologic study showed no evidence of cancer.

On November 21, 1957, a transgastric biopsy of the gastric ulcer and a posterior gastroenterostomy were performed. The pathologic report of the biopsy specimen was chronic gastritis with superficial glandular dysplasia. The patient had an uneventful postoperative course and was discharged eight days postoperatively. On January 2, 1958, six weeks after operation, the patient suddenly died, presumably as a result of myocardial infarction.

Comment. The cytologic examination of this patient was among the first that we performed, and we did not yet have confidence in its diagnostic accuracy. The operation was of little value to the patient since he did not have carcinoma; he died six weeks later with a myocardial infarction. If more reliance had been placed on the cytologic diagnosis, operation would have been avoided.

Case 2. A 73-year-old man was first examined here in February, 1958, because of episodes of fullness and gas beneath the sternum one hour after breakfast, which were relieved promptly by belching, and anterior chest pain precipitated by exertion and relieved by nitroglycerin. There was no history of gallbladder colic. The diagnoses were generalized arteriosclerosis with arteriosclerotic hypertension, arteriosclerotic heart disease with angina pectoris, gallstones, small sliding hiatal hernia, and questionable intramural neoplasm of the gastric fundus.

Roentgen examination revealed a small sliding hiatal hernia. The distance between the top of the gastric fundus and the left leaf of the diaphragm was increased, and there was some loss of the normally rounded contour of the fundus. It was considered that these changes represented an intramural type of neoplasm (Fig. 2). The hemogram was normal, and on gastric analysis free acid was present in the fasting specimen. Exfoliative gastric cytology was reported as showing no tumor cells.

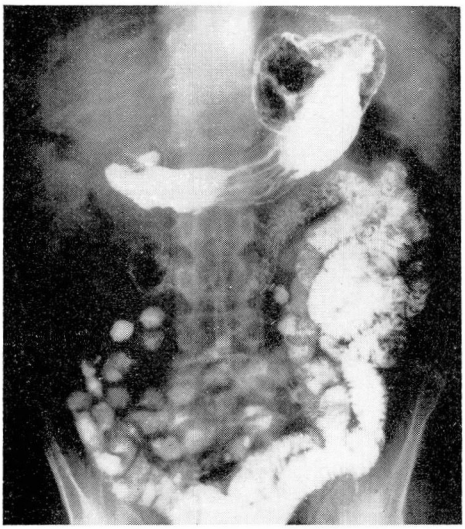

Fig. 2. (Case 2.) Roentgenogram suggests a tumor in the cardia. The distance between the diaphragm and the cardia was increased, also suggesting the presence of neoplasm. Cytologic findings were normal. At operation, patient had an enlarged spleen with adhesions between the spleen and diaphragm producing the deformity seen on the roentgenograms.

At operation on April 1, 1958, the spleen was found to be enlarged two to three times its normal size. The spleen was adherent to the diaphragm next to the hiatus, and this adherence produced the filling defect in the fundus of the stomach consistently seen on roentgen examination. The stomach itself was normal.

Cholecystectomy was performed. The patient had an uneventful postoperative course and was discharged on the eighth postoperative day. When he was last examined in May, 1958, one month after operation, he was asymptomatic.

Comment. Since this 73-year-old patient had no history of gallbladder colic or other

serious symptoms referable to the gallstones, the chief surgical indication was the suspected carcinoma of the stomach. As in Case 1, if we had had more confidence in the diagnostic accuracy of cytologic examination, operation might have been avoided.

Case 3. A 74-year-old man underwent a "routine check-up" in October, 1957. He had a gastric resection for gastric ulcer in 1925, following which he had no digestive symptoms. Roentgen examination showed that the stomach had been approximately half resected and then anastomosed to the jejunum (Fig. 3). There were prominence and irregularity of the mucosal folds and the stomach had a stiff appearance, most likely as the result of infiltrating neoplasm. Gastroscopic examination revealed fixation of the walls of the stomach as evidenced by lack of insufflation. Also, high in the stomach on the anterior wall, a moundlike formation of tissue with a white exudate was observed, suggestive of neoplastic tissue. According to the gastroscopist there was probably diffuse gastric neoplasm without involvement of the esophageal cardiac junction.

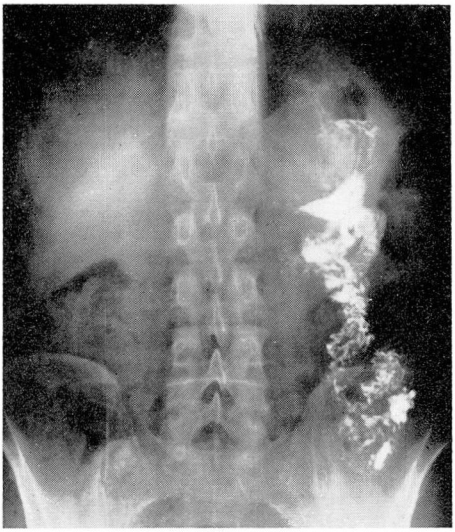

Fig. 3. (Case 3.) Roentgenogram shows evidence of stiffening and loss of the normal mucosal pattern in a patient who had gastric resection for ulcer 33 years previously. Gastroscopic findings suggested diffuse neoplasm and cytologic findings were abnormal. At operation, an extensive nonresectable gastric carcinoma was found.

The laboratory findings showed an anemia: an erythrocyte count of 2,830,000 per cu. mm., a cell volume of 32 ml. per 100 ml., and a hemoglobin content of 10.0 gm. per 100 ml. Findings on exfoliative gastric cytology were positive for atypical cells compatible with malignancy.

On October 25, 1957, a transabdominal biopsy was performed and the posterior and lesser curvatures of the stomach were seen to be involved by an ulcerating infiltrating lesion adherent to the left lobe of the liver and to the posterior parietes. A large lymph node lying in the gastrohepatic ligament alongside the hepatic artery was involved by tumor. A biopsy of the gastric tumor was reported as showing undifferentiated carcinoma.

Comment. Exfoliative gastric cytology was diagnostic in this patient, but in view of the findings on roentgen and gastroscopic examinations, surgical treatment would have been advised without the cytologic findings that supported the roentgen and gastroscopic diagnoses.

Case 4. A 61-year-old man was examined in March, 1958, because of ulcer-like distress that had occurred for a few weeks each spring for the past four years. The distress consisted of epigastric burning two hours after meals, and was relieved by antacids and food. The hemogram was normal and, on gastric analysis, after administration of Histalog, there was 36 units of free hydrochloric acid.

Roentgen examination revealed an ulcer, high on the lesser curvature of the stomach, which was considered to be benign (Fig. 4). Gastroscopic examination revealed an ulcer crater just proximal to the angle. The crater was 1½ cm. in diameter and had a sharp well-defined edge surrounded by a zone of erythema. The base of the ulcer was covered with a white membrane. A few folds of mucosa were seen radiating into the upper perimetry. The ulcer was considered to be benign by gastroscopic examination.

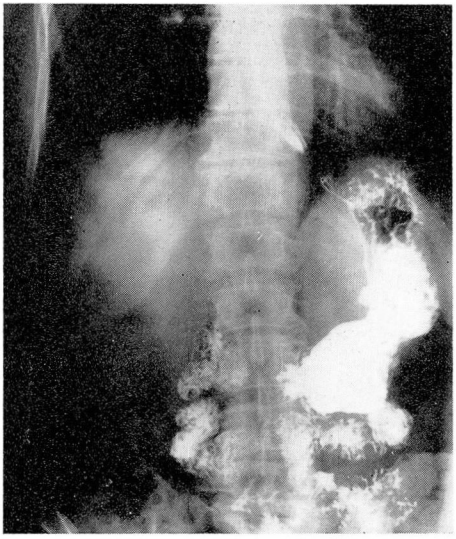

Fig. 4. (Case 4.) Roentgenogram shows gastric ulcer that appears benign. Cytologic findings were positive for dysplastic cells. At operation the ulcer appeared benign, but severe dysplasia was seen in the fundus, pyloric antrum, and vestibule. The patient received one treatment with cobalt-60 before the first cytologic study, and five treatments before the operation, all of which were directed at the gastric fundus to decrease acid secretion.

As a supplement to intensive medical treatment[23] this patient was given cobalt-60* teletherapy,[22] starting on March 21, 1958. After the first cobalt-60 treatment, gastric cytology revealed cells compatible with malignancy. Three days later and after four cobalt-60 treatments, cytology was repeated and cells that were considered to be dysplastic were observed. Because of the cytologic findings, operation was advised. A two-thirds gastric resection (Billroth I) and a biopsy of the gastric fundus were performed on March 31, 1958. During operation, a direct smear of the ulcer was taken and spreads were made and stained by the Papanicolaou method; they showed dysplastic cells.

The pathologic examination of the biopsy specimen from the fundal mucosa revealed no evidence of neoplasm or dysplasia, but there were many parietal cells. The pathologic examination of the resected portion of the stomach, which contained the ulcer crater,

**The radioactive cobalt used was supplied by Oak Ridge National Laboratory on authorization of the Isotopes Division, United States Atomic Energy Commission, Oak Ridge, Tennessee.*

revealed chronic peptic ulcer of the anterior lesser curvature of the fundus of the stomach; severe dysplasia of the gastric mucous membrane of the fundus, pyloric antrum, and vestibule; and chronic inflammation of the lymph nodes. Postoperatively, the patient had a superficial wound infection that healed fairly promptly and he was discharged on the sixteenth postoperative day.

The patient was examined in May, 1958, two months after operation, at which time he was completely asymptomatic and was advised to return to work.

Comment. This patient had dysplasia after only one treatment, and again after four treatments with cobalt-60 teletherapy. Cytologic studies in nine patients during and after cobalt-60 teletherapy have shown dysplasia in one case, nuclear changes in one, and have been normal in seven cases after cobalt-60 teletherapy used to reduce the acidity in benign ulcer. The relation between dysplasia in the stomach and the subsequent development is not clear.[24] Until we know that gastric dysplasia is not a precursor of gastric carcinoma, patients with this type of cytologic change must be treated as though they have potentially malignant lesions. Further studies on the effect of cobalt-60 teletherapy on gastric cytology are being conducted here.

Case 5. A 47-year-old woman was first examined in January, 1958, in the Department of Orthopedic Surgery because of pain in the upper lumbar area. She had epigastric distress radiating into the back intermittently for 12 years. This distress was unrelated to meals and had been more severe during the previous two years.

Laboratory findings were normal except for a hypochlorhydria on gastric analysis (free hydrochloric acid—18 units after stimulation with histamine). Exfoliative gastric cytology showed no neoplastic cells. Roentgen examination showed a large gastric ulcer on the lesser curvature, at the posterior wall near the cardiac end of the stomach.

The location of the gastric ulcer would have required an extremely high resection, and the roentgen and cytologic examinations both suggested a benign ulcer (Fig. 5A).

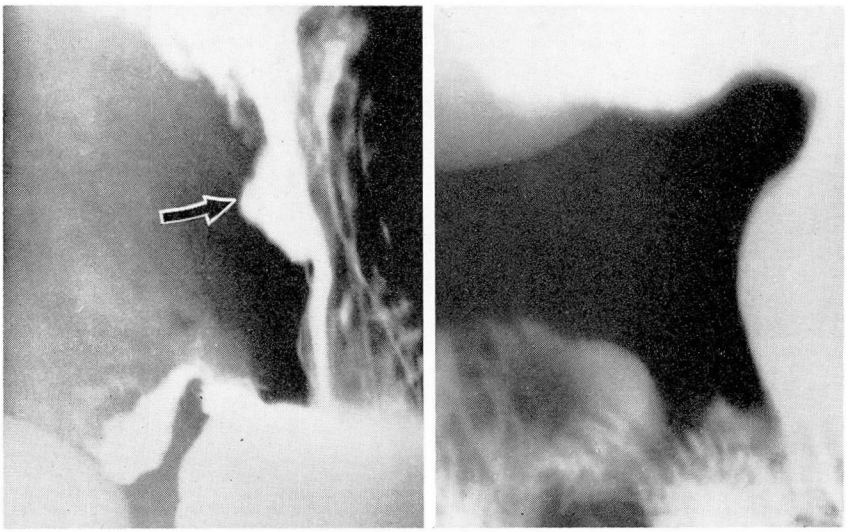

A B

Fig. 5. (Case 5.) **A.** Roentgenogram indicates a moderately sized ulcer crater high along the lesser curvature near the cardia. There was no filling defect and the ulcer appeared benign. Cytologic findings were negative. **B.** Roentgenogram six weeks later indicates complete healing of the ulcer crater. Cytologic findings again were negative.

Intensive medical therapy[23] supplemented by cobalt-60 teletherapy[22] was instituted and within three days the patient was asymptomatic.

Examination six weeks later showed that the patient had remained entirely asymptomatic; cytologic findings were negative for neoplastic cells, and roentgenography showed complete healing of the ulcer (Fig. 5B). On gastric analysis after the injection of histamine, there was achlorhydria, indicating the effect of the cobalt-60 teletherapy.[22] In June, five months after starting treatment, progress studies (roentgenography of stomach and cytology) were again normal.

Comment. Negative findings on cytologic examinations, associated with roentgen and clinical evidence of a benign ulcer, supported the clinician in advising and continuing conservative medical treatment. The proper decision concerning treatment (medical or surgical) was extremely important to the patient, since she would have required a high resection for a benign lesion.

Some of the cytologic and histologic features encountered are demonstrated in Figures 6 through 9.

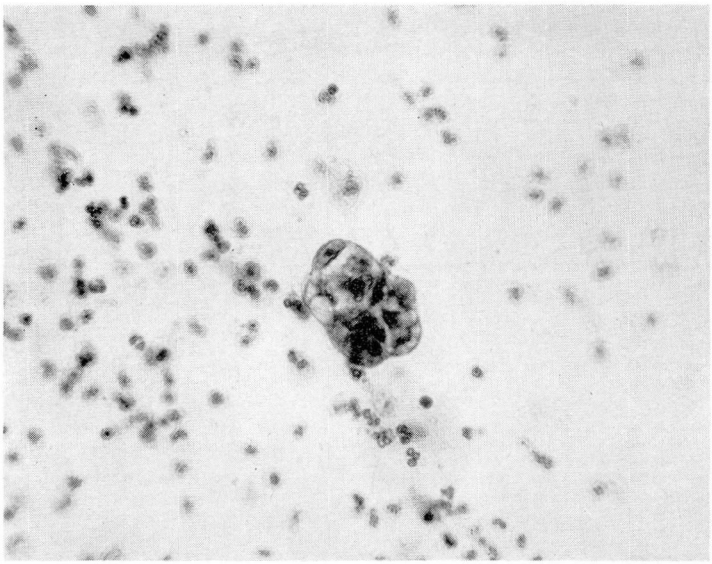

Fig. 6. Neoplastic mucus-containing cells from signet-ring cell carcinoma of the stomach. Papanicolaou stain; x 425.

Indications for Gastric Cytology

Much has been written regarding the role of gastric cytology in the field of cancer detection. On the basis of our experience, we believe that this procedure should not be routine but should be used in the following situations:

(1) For diagnosis when there is a possibility on the basis of clinical (including roentgen) findings of neoplastic change in the stomach.

(2) For the annual or even semiannual screening of patients with premalignant lesions such as pernicious anemia, polyposis (when effective operative procedures cannot be done), and achlorhydria.

(3) For follow-up evaluation of cellular changes following irradiation for nonneoplastic conditions.

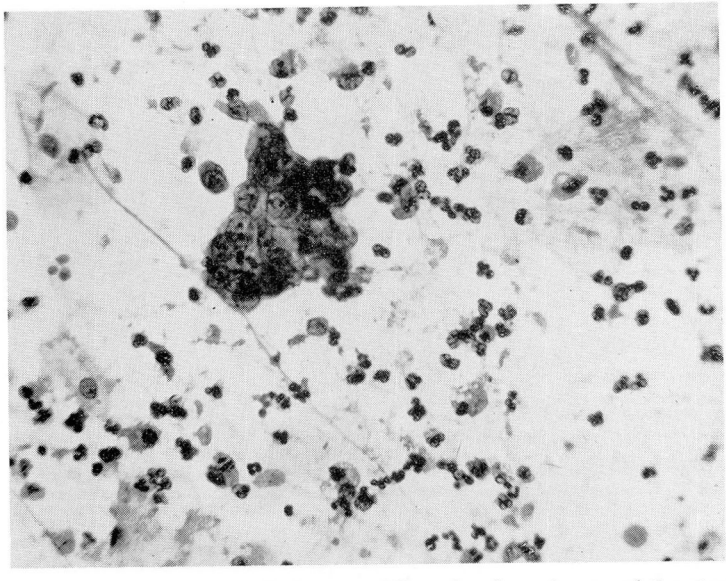

Fig. 7. Cluster of darkly stained cells from undifferentiated carcinoma of the stomach. Papanicolaou stain; x 425.

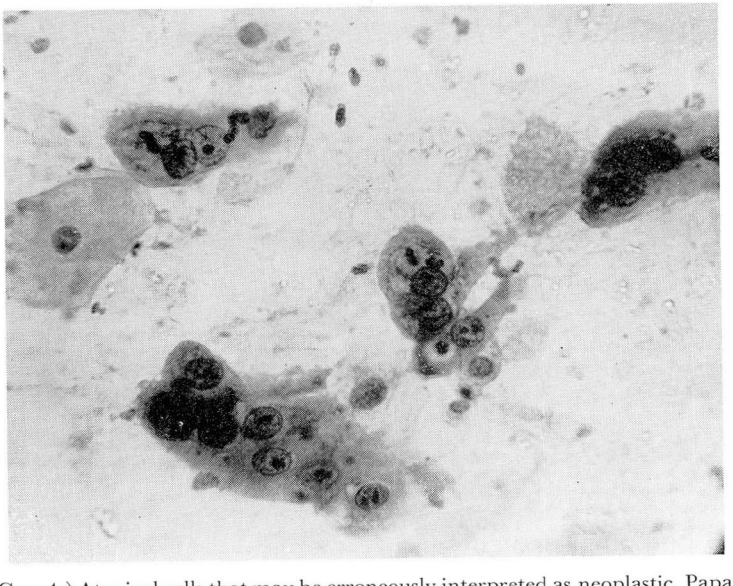

Fig. 8. (Case 4.) Atypical cells that may be erroneously interpreted as neoplastic. Papanicolaou stain; x 425.

(4) For a possible research tool in the further evaluation of cellular changes as one of the fundamental processes in the development of carcinoma.

(5) For confirmation of the gastric origin of a neoplasm evident as a metastatic carcinoma.

(6) For supportive evidence for trial on medical treatment of patients with clinically and roentgenographically benign gastric ulcers.

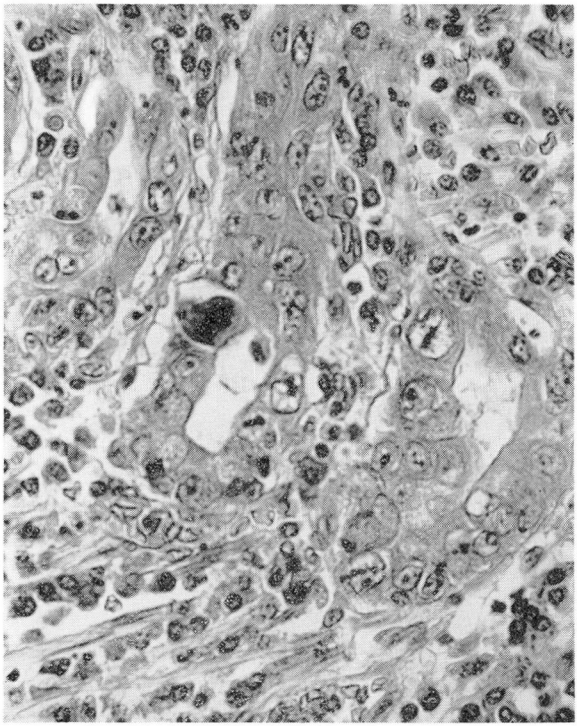

Fig. 9. (Case 4.) Histologic specimen of gastric lesion that was the source of cells in Figure 8. Carcinoma in situ or irradiation reaction? Pathologically, the latter diagnosis was favored. Hematoxylin-eosin and methylene blue stains; x 425.

Summary

Exfoliative gastric cytology was performed on 116 patients, using a revised method of collection and an acetate buffer solution. To obtain good results with gastric cytology, two conditions are essential: (1) securing an adequate specimen, and (2) obtaining competent cytologic interpretation. Each is worthless without the other.

In 79 of 116 patients, there was no clinical or roentgen indication of gastric neoplasm and the cytologic findings were negative. However, the findings on cytologic examinations in this group can be considered only "presumptively correct" because none of the 79 patients underwent operation.

Thirty-seven of the 116 patients underwent operation, and on the basis of the findings on pathologic examination are considered "proved cases." The accuracy of the preoperative cytologic diagnoses in these 37 patients was 92 per cent; there were two false positive and one false negative reports. This high rate of accuracy indicates the practical importance of exfoliative gastric cytology in the diagnosis of carcinoma of the stomach.

The indications for employing exfoliative gastric cytology correspond with any suspicion of the presence of a gastric neoplasm. More widespread use of the technic should result in more accurate and earlier diagnoses of gastric carcinoma.

Acknowledgment

The authors are indebted to Walter L. Palmer, M.D., Joseph B. Kirsner, M.D., Howard Raskind, M.D., and co-workers at The University of Chicago, for stimulating interest and giving liberally of their time and knowledge in setting up the aspiration technics.

References

1. Steigmann, F.: Symposium on gastrointestinal diseases; carcinoma of stomach; diagnostic and therapeutic considerations. M. Clin. North America **37**: 63-85, 1953.
2. Ochsner, A., and Blalock, J.: Carcinoma of stomach; need for earlier diagnosis. Am. J. Gastroenterol. **26**: 476-491, 1956.
3. Ravdin, I. S., and Horn, R. C., Jr.: Gastric ulcer and gastric cancer. Ann. Surg. **137**: 904-910, 1953.
4. Maimon, S. N., and Palmer, W. L.: Gastric cancer: diagnosis, course, and prognosis. Postgrad. Med. **6**: 201-211, 1949.
5. Brown, C. H., and Kane, C. F.: Carcinoma of stomach: review of 406 cases seen from 1940 to 1945: operability, resectability, and curability. Gastroenterology, **22**: 64-74; discussion, 75-79, 1952.
6. Brown, C. H.; Kane, C. F., and Harrington, A., Jr.: Changes in surgery for carcinoma of stomach; 1940 through 1951. Cleveland Clin. Quart. **20**: 276-285, 1953.
7. Brown, C. H.: Changes in surgery for carcinoma of stomach 1940 through 1952. CA **3**: 180-183, 1953.
8. Wangensteen, O. H.: Cancer of the Esophagus and the Stomach. The American Cancer Society, Inc., New York, 1951, pp. 112.
9. Hoerr, S. O.: Personal communication, July 29, 1958.
10. Alsobrook, W. L.: Personal communication, April 18, 1958.
11. Raskind, H. F.: Personal communications, Sept. 1957.
12. Rubin, C. E.; Klayman, I., and Kirsner, J. B.: Symposium on clinical advances in medicine; exfoliative cytology; valuable method for diagnosing gastrointestinal cancer. M. Clin. North America **39**: 261-280, 1955.

13. Klayman, M. I.; Massey, Barbara W.; Pleticka, Sylvia; Galambos, J. T.; Brandborg, L.; Kirsner, J. B., and Palmer, W. L.: Cytologic diagnosis of gastric cancer by chymotrypsin lavage; I. Accuracy of method. Gastroenterology **29**: 849-853; discussion, 863, 864, 1955.

14. Ayre, J. E., and Oren, B. G.: New rapid method for stomach-cancer diagnosis: gastric brush. Cancer **6**: 1177-1181, 1953.

15. Panico, F. G.; Papanicolaou, G. N., and Cooper, W. A.: Abrasive balloon for exfoliation of gastric cancer cells. J.A.M.A. **143**: 1308-1311, 1950.

16. Rosenthal, M., and Traut, H. F.: Mucolytic action of papain for cell concentration in diagnosis of gastric cancer. Cancer **4**: 147-149, 1951.

17. Panico, F. G.: Improved abrasive balloon for diagnosis of gastric cancer. J.A.M.A. **149**: 1447-1449, 1952.

18. Cooper, W. A., and Papanicolaou, G. N.: Balloon technique in cytological diagnosis of gastric cancer. J.A.M.A. **151**: 10-14, 1953.

19. Klayman, M. I.; Massey, Barbara W.; Pleticka, Sylvia; Galambos, J. T.; Brandborg, L.; Kirsner, J. B., and Palmer, W. L.: Cytologic diagnosis of gastric cancer by chymotrypsin lavage; II. Detection of early malignancy. Gastroenterology **29**: 854-862; discussion 863, 864, 1955.

20. Rossmiller, H. R.: Personal communication. Cleveland Clinic, March 1958.

21. Ross, J. R.; McGrath, J. M.; Crozier, R. E.; Rohart, R. R., and Middleton, Margaret: Symposium on Gastric Carcinoma; Exfoliative cytology: its practical application in diagnosis of gastric neoplasms. Gastroenterology **34**: 24-33, 1958.

22. Brown, C. H.: Complicated peptic ulcer treated by cobalt-60 teletherapy; preliminary report of results in 34 patients. Henry Ford Hosp. M. Bull. **5**: 276-282, 1957.

23. Brown, C. H., and Hoerr, S. O.: Treatment of duodenal ulcer. Postgrad. Med. **12**: 308-316, 1952.

24. Goldgraber, M. B.; Rubin, C. E.; Palmer, W. L.; Dobson, R. L., and Massey, Barbara: Early gastric response to irradiation, serial biopsy study. Gastroenterology **27**: 1-20, 1955.