

# MANDIBULAR ODONTOMA: EXCISION FROM A COMBINED INTRAORAL AND TRANSCERVICAL APPROACH

## REPORT OF A CASE

PAUL V. SLATER, M.D.,\* SHATTUCK W. HARTWELL, JR., M.D., AND  
ROBIN ANDERSON, M.D.

*Department of Plastic Surgery*

**O**DONTOMAS are benign tumors of the jaws, which are derived from dental elements.<sup>1, 2</sup> They occur twice as often in females as in males, and they are most frequently discovered in the second and third decades of life. These *hard*, radiopaque tumors usually cause no symptoms, diagnosis being incidental to routine roentgenographic examination of the jaws. The most common site is in the area of the second and third molars, where they may prevent eruption of contiguous teeth.<sup>3</sup> Occasionally odontomas cause bulging and pain in the jaw.

These tumors, rarely bulky or large, most frequently are removed by means of the intraoral approach, thus easily preserving the continuity of the mandible. The patient reported here had an odontoma so large that, at first, resection of the involved mandible seemed to be the only means to eradicate the tumor. The patient was referred to us in the hopes of avoiding partial mandibulectomy. The tumor was removed with relative ease by using a combined intraoral and transcervical approach, and the continuity of the mandible was preserved.

## REPORT OF A CASE

A 16-year-old white girl was admitted to the Cleveland Clinic Hospital on March 30, 1964, because of swelling and pain in the right jaw. There had been gradual swelling of the jaw for more than one year, with some pain and tenderness over the area for several months. Her medical history was noncontributory.

Examination revealed facial asymmetry, the right mandible being larger than the left. Intraoral examination of the mandible disclosed both buccal and lingual enlargement in the molar area, with normal soft-tissue covering. Roentgenograms of the jaws on March 11, 1964, showed evidence of a large, round, calcified mass within the right mandible, posterior to the first molar (*Fig. 1A and B*). There was distension and almost complete resorption of cortical bone on the lingual aspect. On March 31, 1964, a biopsy was performed and the diagnosis was a composite, complex odontoma of the mandible. The patient was discharged from the hospital, to be readmitted, at a later date, for total excision of the lesion.

On June 29, 1964, under nasotracheal anesthesia, an operation was performed using both an intraoral and a transcervical submandibular approach. The mandible was approached through an incision in an upper cervical skin crease. The lingual aspect of the right mandible was approached, sparing the mandibular branch of the seventh nerve, and the inferior and lingual cortices were removed with a chisel. As much of the odontoma as could be exposed from this approach was divided and partially resected with a high-speed, air-driven burr.

\* *Fellow in the Department of Plastic Surgery.*

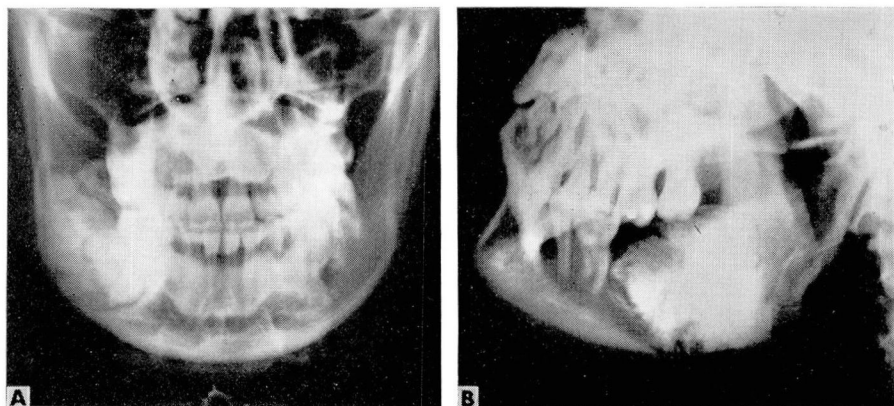


Fig. 1. A and B, preoperative roentgenograms of the jaws, showing irregular radiopacity surrounded by radiolucent bands.

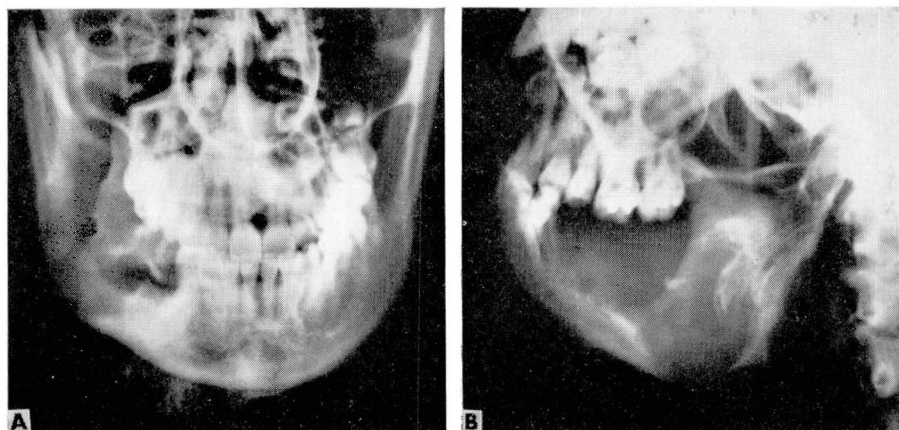


Fig. 2. A and B, postoperative roentgenograms showing that removal of the tumor was complete, with the remaining buccal strut preserving the continuity of the mandible.

An oral approach was then made on the lingual side of the mandible, elevating mucoperiosteal flaps. The tumor was visualized, was separated from normal bone, and all visible parts of it were removed with a chisel. The right inferior alveolar nerve and artery were necessarily divided in the piecemeal removal of the tumor.

The cervical wound was closed in three layers with 4-zero chromic catgut and 5-zero nylon sutures in the skin. The oral wound was closed over a Penrose drain with three loose 4-zero chromic catgut sutures. The lingual mandibular plate adjacent to the tumor was either egg-shell thin or absent, and after removal of the odontoma the remains of the plate were excised to allow collapse of the soft tissues into the solid buccal strut. This buccal remnant of the right mandible was not large (Fig. 2).

The pathologist's report confirmed the findings of the previous biopsy: composite, complex odontoma, epithelial hyperplasia, and chronic inflammation of the right mandible (Fig. 3).

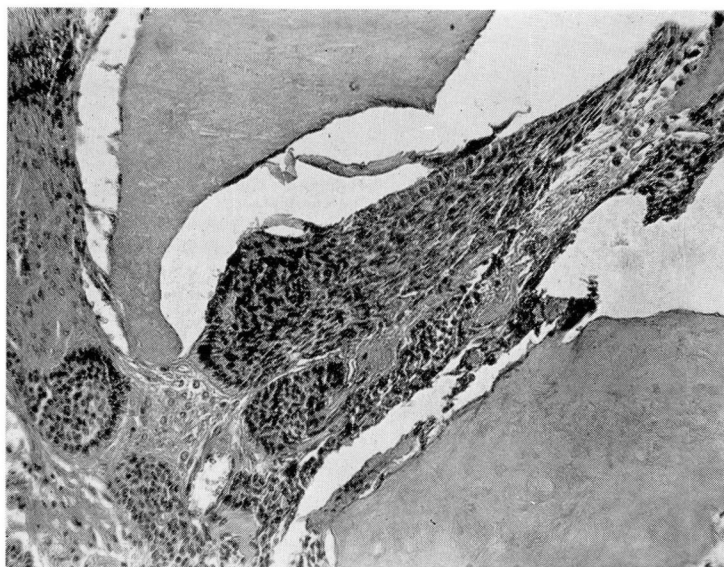


Fig. 3. Photomicrograph of an area of the odontoma in osseous tissue, showing islands of spindle cells with peripheral palisading. Hematoxylin and eosin stain; magnification  $\times 180$ .

Postoperatively this patient has done well and now has no evidence of recurrence of the tumor. Her only postoperative difficulties have consisted of discomfort in the lower right first bicuspid and pain in the temporomandibular joint. This pain has recurred about once a month. In July of 1965, a maxillary night-bite guard was inserted in an effort to alleviate this sporadic pain. The face now is symmetric.

#### SUMMARY AND CONCLUSION

The combined intraoral and submandibular exposure was a key to success in the resection of a large composite, complex odontoma in the case reported. It allowed the dissection to be completed with relative ease; surgical exposure was adequate; and no adjacent teeth were lost. The patient not only has been cured of the mandibular odontoma, but has no disfigurement and little discomfort. The combined approach for dissection is essential to adequate and appropriately aggressive treatment of large tumors of the mandible.

#### REFERENCES

1. Gorlin, R. J., and Meskin, L. H.: Odontogenic tumors in man and animals: pathologic classification and clinical behavior; a review. *Ann. New York Acad. Sci.* **108**: 722-771, 1963.
2. Thoma, K. H.: *Oral Pathology; A Histological, Roentgenological, and Clinical Study of the Diseases of the Teeth, Jaws, and Mouth*, 4th ed. St. Louis: The C. V. Mosby Company, 1954, 1536 p.; p. 1225.
3. Olech, E.: Complex composite odontoma; a clinical and histologic report. *Oral Surg.* **16**: 960-964, 1963.