

Fulminating vasculitis in a homozygous C2-deficient patient¹

Ralph E. Bennett, M.D.²
John D. Clough, M.D.
Leonard H. Calabrese, D.O.

Homozygous C2 deficiency is associated with a variety of autoimmune diseases, but has never been described in association with acute necrotizing vasculitis. The authors observed such a case involving a 55-year-old white man who presented with a five-week history of progressive digital gangrene. There was no clinical or laboratory evidence of systemic lupus erythematosus or other connective tissue disease. Angiography supported the diagnosis of obliterative vasculitis involving arteries of both medium and small caliber. High levels of immune complexes were detected, documented by Clq binding and cryoprecipitation. Total hemolytic complement activity was undetectable. Assays of individual complement components revealed absence of C2. Evidence of participation of the complement system in mediation of vascular inflammation was supported by demonstration of C3 activation products using two-dimensional electrophoresis; in view of the normal C4 levels, this suggests activation of an alternate pathway. It would appear that acute complement-mediated vascular inflammation can occur in the absence of an early component of the standard pathway.

Index term: Vasculitis

Cleve Clin Q 52:213-215, Summer 1985

Deficiency of the C2 component of complement is the most common type. While many C2-deficient individuals have no serious medical problems, some may have a variety of autoimmune diseases, particularly systemic lupus erythematosus (SLE).¹ Other associated diseases may include Henoch-Schönlein purpura, dermatomyositis, membranoproliferative glomerulonephritis, inflammatory bowel disease, and infection.¹⁻¹² While there has been a report of a C2-deficient patient with chronic vasculitis who had Raynaud's phenomenon, arthralgia, and foot drop,⁸ we believe this is the first reported case of C2 deficiency in fulminating vasculitis.

Case Report

A 55-year-old white man was admitted to the Cleveland Clinic for evaluation of digital gangrene. He had been well until five weeks earlier, when his right index finger became cold and painful. Over the next few weeks, the tips of his right ring finger and both index fingers became necrotic, while his other fingertips became cyanotic. His history revealed long-standing cirrhosis, as well as a portacaval shunt in 1975, and he had smoked one pack of cigarettes a day for 35 years. On admission, his orientation was good and his vital signs were stable. The Allen test was abnormal on the left; other pulses were within normal limits. Fundal examination was normal, and there were no splinter hemorrhages. Cardiac examination showed a III/VI holosystolic murmur at the left sternal border, unchanged from a year earlier.

A complete blood count was normal, with 147,000 platelets. Urinalysis was normal. Blood urea nitrogen was 37 mg/100 mL (14.8 mmol/L); creatinine, 2.2 mg/100 mL (194 μ mol/L); and serum electrolytes, normal except for a sodium level of 129 mEq/L. Total bilirubin was 2.0 mg/100 mL (36 μ m/L); other liver enzymes were normal. The Westergren sedimentation rate was 24 mm/hr, and the latex fixa-

¹ Departments of Rheumatic Disease and Immunopathology, The Cleveland Clinic Foundation. Submitted for publication Nov 1984; accepted Feb 1985.

² Current location: The Arthritis Center, Ltd., Phoenix, Ariz. sjh

0009-8787/85/02/0213/03/\$1.75/0

Copyright © 1985, The Cleveland Clinic Foundation

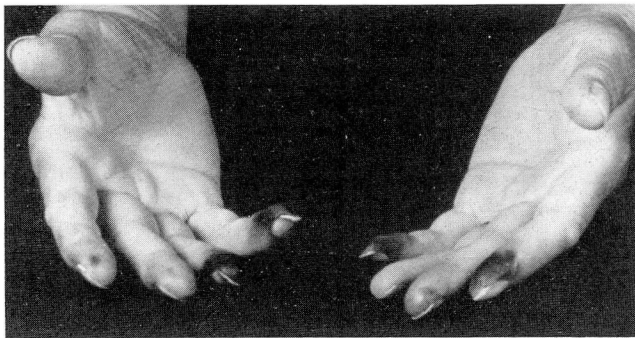


Fig. Appearance of the patient's fingers late in his hospital course.

tion titer 1:640. Cryoglobulins were 113 $\mu\text{g}/\text{mL}$ (normal, <50), including C3 and polyclonal IgG, IgA, and IgM. Clq binding assay showed 481 U/mL (normal, <62); C3 was 98 mg% (normal, 83–169), C4 was 19.5 mg% (normal, 24–51), and CH50 was markedly depressed (3 U). ANA, anti-DNA, and anti-ENA were all negative. Factor B was 6 mg/100 mL (normal, 12–30). Using two-dimensional immunoelectrophoresis, activated C3 was found to be 18 mg% of total antigenic C3 (normal, <10%). HBsAG was negative, as were multiple blood cultures.

After identification of C2 deficiency,¹³ C3 activation was assessed by two-dimensional immunoelectrophoresis¹⁴ in order to differentiate B1c (native C3) from B1a (activated). C3 and C4 were measured by nephelometry and factor B by radioimmunoassay. Total hemolytic complement was measured in the standard manner¹⁵ (normal range in our laboratory, 70–190 CH50 U/mL).

Following heparinization, echocardiography combined with cardiac catheterization revealed no source of emboli. Angiograms of the left hand and arm showed tapering and occlusion of the left ulnar artery 5 cm proximal to the styloid process, as well as occlusion of several interdigital arteries. Other digits subsequently became necrotic as well (Fig). Plasmapheresis was attempted several times, but because of poor vascular access was successful only once. Oral cyclophosphamide (Cytosan, Mead Johnson) was administered at a rate of 100 mg a day. The patient's condition deteriorated rapidly; anasarca, severe pre-renal azotemia, and hepatic encephalopathy developed, the plasmapheresis shunt became occluded by clot, and his arm became warm and swollen. A chest radiograph showed infiltrates. *Staphylococcus aureus* grew in blood cultures. Septic shock developed, and the patient died on the 30th hospital day. Hemolytic complement analysis revealed absence of C2, consistent with homozygous deficiency. The patient's HLA type was A25 B18 Dr2. Postmortem examination showed endocarditis involving the tricuspid valve; permission for examination of the digital arteries was not obtained.

Discussion

Glass et al¹ surveyed 509 blood bank donors and found that 1.2% had heterozygous C3 deficiency, suggesting that the frequency of homozygous deficiency is approximately 1 in 30,000. A survey of patients with rheumatic disease re-

vealed a 3.7% prevalence of heterozygous deficiency in patients with juvenile rheumatoid arthritis and 5.9% in patients with SLE.¹⁶ Thus while partial C2 deficiency is not uncommon in the general population, it is more frequently associated with rheumatic disease.

Several cases of C2 deficiency associated with chronic vasculitis have been described. Friend et al⁸ described a patient with a 23-year history of inflammatory arthritis, Raynaud's phenomenon, and a mononeuropathy multiplex. Several patients with C2 deficiency and anaphylactoid purpura have been described.^{2,14,17} All had recurrent purpuric eruptions, often following upper respiratory infections, and one also had focal glomerulonephritis.¹⁷ Another patient had cryoglobulins, though they were not characterized.¹⁸ All had markedly decreased C2 as measured by functional assay, and 1 had decreased factor B.²

In contrast to these cases of vasculitis, our patient's course was rapidly terminal, with only 10 weeks intervening between the onset of digital gangrene and death. Since permission for post-mortem examination of the extremities was not obtained, we could not obtain pathological evidence of vasculitis of the digital arteries. No evidence of vasculitis was seen in the kidneys or lungs. While it could be postulated that thromboangiitis obliterans was responsible for the digital gangrene, this is unlikely; the course of his illness was unusually rapid, neither superficial nor deep thrombophlebitis was present, and, most importantly, his gangrene progressed despite abstinence from tobacco. His right-sided endocarditis could not explain the entire course of his illness and was considered to be agonal; moreover, multiple blood cultures, echocardiography, and cardiac catheterization had failed to reveal evidence of endocarditis on admission. The presence of immune complexes and the characteristic angiogram further supported the diagnosis of vasculitis as the cause of the digital gangrene.

The precise role of immune complexes in the pathogenesis of our patient's disorder is unclear. Alternative mechanisms must be considered, since terminal activation of the complement cascade via the usual pathway would be impossible. One possibility is activation of an alternate pathway by either the appropriate antigen or IgA or IgG4 immunoglobulins, as supported by the detection of IgA in the cryoprecipitate. The presence of activated C3 in the serum, combined with the normal level of non-activated C3, implies a

low level of activation; in view of the normal C4 levels and homozygous C2 deficiency, activation of an alternate pathway seems likely.

Another possible pathogenic mechanism considers the potential effect of the complement system on the normal circulation and clearance of immune complexes. It has been demonstrated¹⁸ that the solubility of immune complexes is greatly impeded in C2-deficient sera, thereby exerting a protective effect *in vivo* by solubilizing large antigen-antibody aggregates which may cause tissue damage. Furthermore, decreased solubility may lead to impaired clearance, a prolonged circulatory half-life, and increased tissue deposition.¹⁹ Lastly, all of these interactions may be influenced by the presence of immune complexes, which can themselves influence immunoregulation. Depending on the system used, Clough et al²⁰ demonstrated both immunologic enhancement and inhibition of suppressor cell function in the presence of immune complexes.

The reason for the association of C2 deficiency with rheumatic disease is not known; hypotheses have included an immune response gene associated with an HLA haplotype and decreased viral neutralization. Defective immune complex solubility with subsequent activation of an alternative pathway could explain the fulminating vasculitis seen in our patient.

Leonard H. Calabrese, D.O.
Department of Rheumatic Disease
The Cleveland Clinic Foundation
9500 Euclid Ave.
Cleveland OH 44106

References

1. Glass D, Raum D, Gibson D, Stillman JS, Schur PH. Inherited deficiency of the second component of complement. *J Clin Invest* 1976; **58**:853-861.
2. Sussman M, Jones JH, Almeida JD, Lachmann PJ. Deficiency of the second component of complement associated with anaphylactoid purpura and presence of mycoplasma in the serum. *Clin Exp Immunol* 1973; **14**:531-539.
3. Leddy JP, Griggs RC, Klemperer MR, Frank MM. Hereditary complement (C₂) deficiency with dermatomyositis. *Am J Med* 1975; **58**:83-91.
4. Slade JD, Luskin AT, Gewurz H, Kraft SC, Kirsner JB, Zeitz HJ. Inherited deficiency of second component of complement and HLA haplotype A10, B18 associated with inflammatory bowel disease. *Ann Intern Med* 1978; **88**:796-798.
5. Riggs JE, Griggs RC, Rosenfeld SI, May AG, Penn AS. Heterozygous C₂-deficiency and myasthenia gravis. *Neurology* 1980; **30**:871-873.
6. Arala-Chaves MP, Fundenberg HH, Boackle RJ, Ainsworth SK, Mello-Vieira R. A case of "common variable immunodeficiency" with reduced C₂ activity and multiple associations. *Clin Immunol Immunopathol* 1980; **17**:227-234.
7. Loirat C, Levy M, Peltier AP, Broyer M, Checoury A, Mathieu H. Deficiency of the second component of complement; its occurrence with membranoproliferative glomerulonephritis. *Arch Pathol Lab Med* 1980; **104**:467-472.
8. Friend P, Repine JE, Youngki K, Clawson CC, Michael AF. Deficiency of the second component of complement (C₂) with chronic vasculitis. *Ann Intern Med* 1975; **83**:813-819.
9. Gewurz A, Lint TF, Roberts JL, Zeitz H, Gewurz H. Homozygous C₂ deficiency with fulminant lupus erythematosus: severe nephritis via the alternative complement pathway. *Arthritis Rheum* 1978; **21**:28-36.
10. Roberts JL, Schwartz MM, Lewis EJ. Hereditary C₂ deficiency and systemic lupus erythematosus associated with severe glomerulonephritis. *Clin Exp Immunol* 1978; **31**:328-338.
11. Sampson HA, Walchner AM, Baker PJ. Recurrent pyogenic infections in individuals with absence of the second component of complement. *J Clin Immunol* 1982; **2**:39-45.
12. Repine JE, Clawson CC, Friend PS. Influence of a deficiency of the second component of complement on the bactericidal activity of neutrophils *in vitro*. *J Clin Invest* 1977; **59**:802-809.
13. Clough JD, Mansfield LR. Use of C₆- and C₇-deficient human sera in quantitative hemolytic assays for C₆ and C₇. *J Immunol Methods* 1979; **30**:201-207.
14. Laurell CB. Antigen-antibody crossed electrophoresis. *Anal Biochem* 1965; **10**:358-361.
15. Mayer M. Complement and complement fixation. [In] Kabat EA, ed. *Experimental Immunochemistry*. 2nd ed. Springfield Ill, Charles C Thomas, 1971, pp 133-240.
16. Glass D, Schur PH. Inherited deficiency of the second component of complement: HLA linkage and rheumatic disease associations. *Clin Rheum Dis* 1978; **4**:603-615.
17. Einstein LP, Alper CA, Block KJ, et al. Biosynthetic defect in monocytes from human beings with genetic deficiency of the second component of complement. *N Engl J Med* 1975; **292**:1169-1171.
18. Gelfand EW, Clarkson JE, Minta JO. Selective deficiency of the second component of complement in a patient with anaphylactoid purpura. *Clin Immunol Immunopathol* 1975; **4**:269-276.
19. Takahashi M, Takahashi S, Hirose S. Solubilization of antigen-antibody complexes; a new function of complement as regulator of immune reactions. *Prog Allergy* 1980; **27**:134-166.
20. Clough JD, Getzy DM, Calabrese LH, Frank SA, Mazanec DJ. Immune complexes and immunoregulation. [In] Krakauer RS, Cathcart MK, eds. *Immunoregulation and Immunity*. Amsterdam, Elsevier North Holland, 1980, pp 21-28.