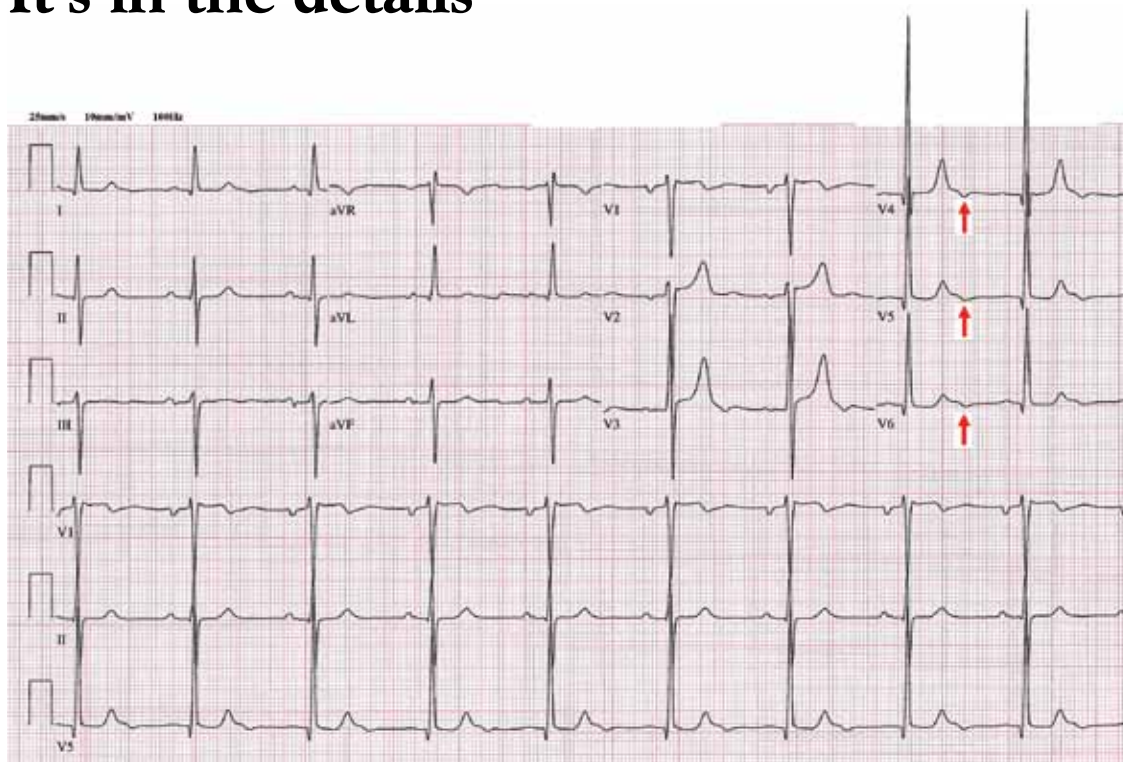


The Clinical Picture

Electrocardiography in aortic regurgitation: It's in the details



Although not routinely reported, the negative U wave indicates underlying structural or ischemic heart disease

FIGURE 1. The patient's 12-lead electrocardiogram shows normal sinus rhythm and a rate of 55 beats per minute. The frontal-plane QRS complex vector is deviated leftward. Left atrial abnormality is present, given the terminally negative P wave in lead V₁ and the bifid P wave in lead II. Left ventricular volume overload is supported by the following findings: increased QRS complex voltage, best seen in the precordial (chest) leads, indicative of increased left ventricular mass; prominent septal depolarization, as reflected by Q waves in leads V₄ to V₆; the absence of an ST-segment or T-wave abnormality; and negative U waves in leads V₄ to V₆ (arrows).

A 72-YEAR-OLD MAN with a 15-year history of a heart murmur presents to his cardiologist with shortness of breath on exertion over the past 12 months. He otherwise feels well and reports no chest discomfort, palpitations, or swelling of his legs or feet. He is not

taking any cardiac drugs, and his health has previously been excellent.

On physical examination, his pulse rate is regular at 55 beats per minute, and his blood pressure is 178/66 mm Hg. Cardiac auscultation reveals an early- to mid-diastolic murmur heard best with the patient seated and leaning forward, and located at the left sternal border;

the murmur is consistent with aortic regurgitation. Standard 12-lead electrocardiography (ECG) is performed (FIGURE 1), followed shortly by transthoracic echocardiography, which confirms severe aortic regurgitation, moderate left ventricular hypertrophy, an enlarged left ventricular end-diastolic diameter, and normal left ventricular systolic function, with an estimated left ventricular ejection fraction of 60%. Coronary angiography shows normal coronary arteries.

Q: Which of the following findings on 12-lead ECG is not commonly reported in chronic severe aortic regurgitation?

- Left ventricular hypertrophy
- QRS complex left-axis deviation
- A negative U wave
- Atrial fibrillation

A: The correct answer is a negative U wave.

In long-standing left ventricular volume overload, such as in chronic aortic regurgitation, characteristic findings on ECG include lateral precordial narrow Q waves and left ventricular hypertrophy. The ST segment and T wave are often normal or nearly normal. The QRS complex vector may demonstrate left-axis deviation, but this is not absolute. In contrast, pressure overload conditions such as aortic stenosis and systemic hypertension commonly manifest as left ventricular hypertrophy with strain pattern of ST depression in lateral precordial leads and asymmetric T-wave inversion.

A negative U wave, best identified in leads V_4 to V_6 , is a common finding in left ventricular volume overload. A negative U wave represents a negative deflection of small amplitude (normally < 0.1 to 3 mV) immediately following the T wave. Although not routinely reported, the negative U wave is an indicator of underlying structural heart disease.¹

Q: A negative U wave has been associated with which of the following conditions?

- Aortic or mitral regurgitation
- Myocardial ischemia
- Hypertension
- All of the above

A: The correct answer is all of the above.

Negative U waves have been identified in regurgitant valvular heart disease with left ventricular volume overload, in myocardial ischemia,^{2,3} and in hypertension.⁴ During exercise stress testing, the transient appearance of negative U waves strongly suggests flow-limiting coronary artery disease. Moreover, changes in the U wave during exercise stress testing may be a sign of well-developed coronary collaterals.⁵ Therefore, it is prudent to note their presence on resting ECG and to investigate further with cardiac stress testing and imaging.

The pathogenesis of the negative U wave remains unclear. Of the various hypotheses put forth, a mechano-electric phenomenon may best explain its diverse pathology. ■

REFERENCES

1. **Correale E, Battista R, Ricciardiello V, Martone A.** The negative U wave: a pathogenetic enigma but a useful, often overlooked bedside diagnostic and prognostic clue in ischemic heart disease. *Clin Cardiol* 2004; 27:674-677.
2. **Rimmerman CM.** A 62-year-old man with an abnormal electrocardiogram. *Cleve Clin J Med* 2001; 68:975-976.
3. **Gerson MC, Phillips JF, Morris SN, McHenry PL.** Exercise-induced U-wave inversion as a marker of stenosis of the left anterior descending coronary artery. *Circulation* 1979; 60:1014-1020.
4. **Lambert J.** Clinical study of the abnormalities of the terminal complex TU-U of the electrocardiogram. *Circulation* 1957; 15:102-104.
5. **Miwa K, Nakagawa K, Hirai T, Inoue H.** Exercise-induced U-wave alterations as a marker of well-developed and well-functioning collateral vessels in patients with effort angina. *J Am Coll Cardiol* 2000; 35:757-763.

ADDRESS: Curtis Rimmerman, MD, MBA, Department of Cardiovascular Medicine, J2-4, Cleveland Clinic, 9500 Euclid Avenue, Cleveland, OH 44195; e-mail rimmerc@ccf.org.

CME ANSWERS

Answers to the credit tests on page 559 of this issue

Persistent cough **1B 2B**

Cardiovascular device **1D 2B**
infection

Small renal masses **1A 2D**

Sleep and diabetes **1B 2C 3C**