

# Subpectoral Biceps Tenodesis

David M. Levy, MD, Zachary I. Meyer, MD, Kirk A. Campbell, MD, and Bernard R. Bach Jr, MD

## Abstract

Biceps tenodesis is a common procedure performed for tendinopathy of the long head of the biceps brachii (LHB). Indications include partial-thickness LHB tear, tendon subluxation with or without subscapularis tear, and failed conservative management of bicipital tenosynovitis. Biceps tenodesis may also be performed for superior labrum anterior to posterior tears.

Evaluation of biceps stability is important in the treatment of LHB pathology. We advocate a technique of subpectoral biceps tenodesis. Interference screw fixation has demonstrated biomechanical superiority in laboratory models. If there are any concomitant operations, such as rotator cuff repair, the postoperative rehabilitation protocol may need to be adjusted. Overall, subpectoral biceps tenodesis with interference screw fixation has had excellent clinical outcomes and low complication rates.

Tendinopathy of the long head of the biceps brachii (LHB) is a common source of anterior shoulder pain. The LHB tendon is an intra-articular yet extrasynovial structure, ensheathed by the synovial lining of the articular capsule.<sup>1</sup> Branches of the anterior circumflex humeral artery course along the bicipital groove, but the gliding undersurface of the LHB remains avascular.<sup>2</sup> Tendon irritation is most common within the groove and usually produces “tendinosis,” characterized by collagen fiber atrophy, fibrinoid necrosis, and fibrocyte proliferation.<sup>1</sup> Neviasser and colleagues<sup>3</sup> correlated such changes in the LHB tendon with rotator cuff pathology, as the 2 often coexist. Primary LHB tendinitis is less common and associated with younger patients who engage in overhead activities, such as baseball and volleyball.<sup>4</sup>

Nonoperative management, which is trialed initially, consists of rest, use of nonsteroidal anti-inflammatory drugs, and physical therapy. Corticosteroid injections are administered through the subacromial space or glenohumeral joint, which is continuous with the LHB sheath. Some physicians give ultrasound-guided injections into the LHB sheath. For fear of tendon atrophy from corticosteroid injections, some

physicians prefer iontophoresis with a topical steroid over the bicipital groove. If conservative measures fail, the physician can choose from 2 primary surgical options: biceps tenotomy and tenodesis. Tenodesis can be performed within the groove (suprapectoral) or subpectoral. In this review, we highlight 5 key features of subpectoral biceps tenodesis to guide treatment and improve outcomes.

## Examination and Indications

Management of LHB tendinopathy begins with a complete physical examination. Tenderness over the bicipital groove is the most consistent finding, but this region may be difficult to localize in large individuals. The arm should be internally rotated 10° to orient the groove anterior and palpated 7 cm below the acromion.<sup>5</sup> Anterior shoulder pain after resisted elevation with the elbow extended and supinated represents a positive Speed test. A positive Yergason test produces pain with resisted forearm supination while the elbow is flexed to 90°.

Evaluation of biceps instability is important in deciding which type of management (operative or nonoperative) is appropriate for a patient. Medial biceps subluxation may be detected by bringing the flexed arm from abduction, external rotation into cross-body adduction, internal rotation with decreased arm flexion.<sup>6</sup> Another maneuver that elicits biceps irritation is combined abduction–extension, which places tension on the biceps tendon. Similarly, coracoid impingement may disrupt the subscapularis roof of the biceps sheath and cause LHB instability. Dines and colleagues<sup>7</sup> reproduced the painful clicking of coracoid impingement by placing the shoulder in forward elevation, internal rotation, and varying degrees of adduction. Belly-press, lift-off, and internal rotation strength are other tests that assess subscapularis integrity. Rotator cuff impingement signs should be evaluated, and the contralateral shoulder should be examined for comparison.

Plain radiographs may show a pathology, such as anterior acromial spurring or posterior overgrowth of the coracoid, for which surgery is more suited. T2-weighted magnetic resonance imaging (MRI) may show an increased LHB signal, but this has shown poor concordance with arthroscopic findings of biceps pathology.<sup>8</sup> Magnetic resonance arthrography can better detect medial dislocation of the LHB tendon from subscapularis tears. Ultrasound is cost-effective but highly operator-dependent.

Indications for biceps tenotomy or tenodesis include failed

---

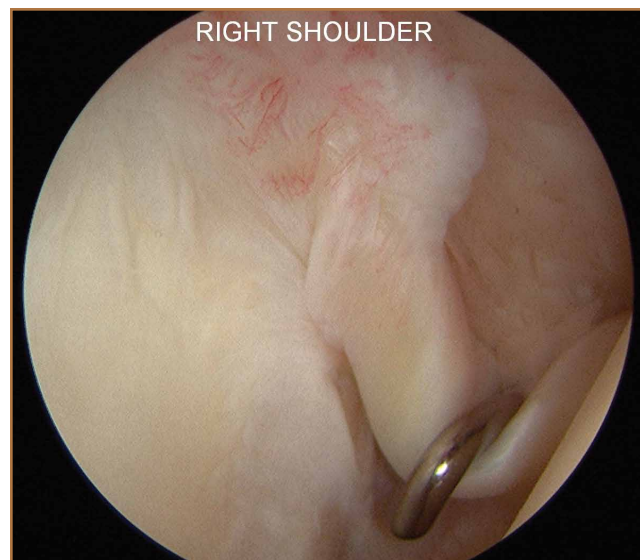
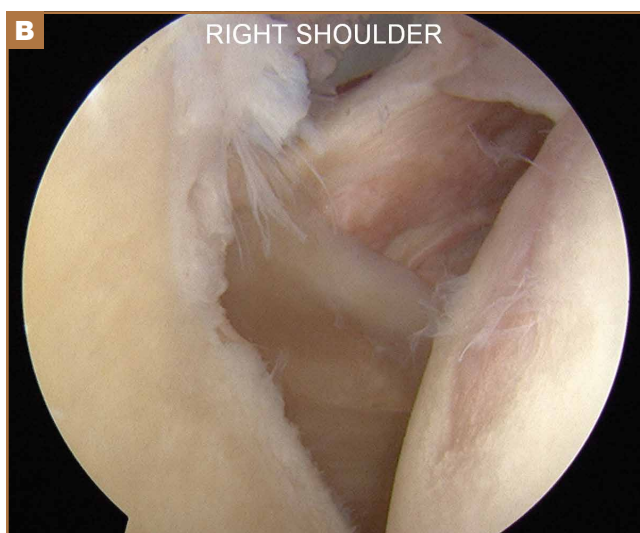
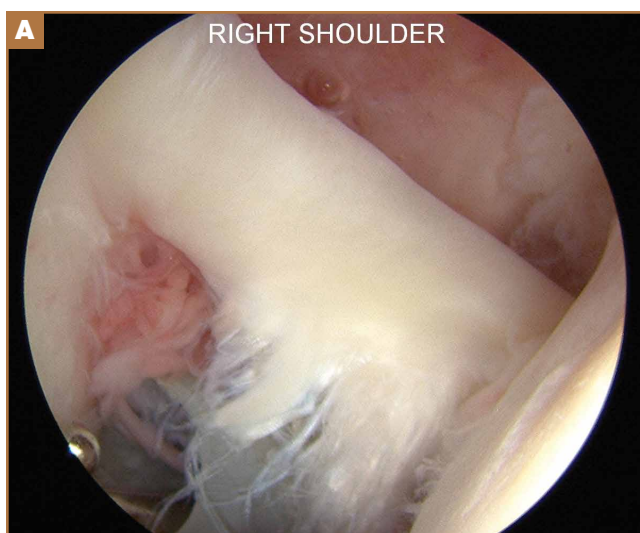
**Authors' Disclosure Statement:** Dr. Bach has received research support from Arthrex, Conmed Linvatec, DJ Orthopaedics, Ossur, Smith & Nephew, and Tornier; received publishing royalties and financial and material support from Slack; and served as a board or committee member for the American Orthopaedic Society for Sports Medicine. The other authors report no actual or potential conflict of interest in relation to this article.

conservative management, partial-thickness LHB tears more than 25% to 50% in diameter, and medial subluxation of the LHB tendon with or without a subscapularis tear. Superior labrum anterior to posterior (SLAP) tears in older patients are a relative indication. Intraoperative findings may also indicate the need for LHB surgery. During the diagnostic arthroscopy, the LHB tendon should be evaluated for synovial inflammation or fraying (Figures 1A, 1B). This may need to be done under dry conditions, as pump pressure can compress and blunt the inflamed appearance. The O'Brien maneuver can be performed to demonstrate incarceration of the LHB tendon within the anterior glenohumeral joint. A probe should be placed through an anterior portal to pull the intertubercular LHB tendon into view, as this region is most commonly inflamed (Figure 2). Probing of the tendon also allows assessment of the stability of the biceps sling.

## Surgical Technique

When biceps surgery is indicated, the surgeon must choose between tenotomy and tenodesis. Tenotomy is a low-demand procedure indicated for low-demand patients. A "Popeye" deformity may occur in up to 62% of patients, but Boileau and colleagues<sup>9</sup> reported that none of their patients were bothered by it. Another concern after tenotomy is fatigue-cramping of the biceps muscle belly. Kelly and colleagues<sup>10</sup> reported that up to 40% of patients had soreness and decreased strength with elbow flexion. Such cramping is more common in patients under age 60 years. For these reasons, biceps tenotomy should be reserved for older, low-demand patients who are not concerned about cosmesis and less likely to comply with postoperative motion restrictions.<sup>2</sup> We tend to perform tenotomy in obese patients, who may have a Popeye deformity that is not detectable, and in patients with diabetes; the goal is to avoid a wound infection resulting from the close proximity of tenodesis incision and axilla.

Biceps tenodesis should preserve the length-tension relationship of the biceps muscle and maintain its normal contour. Tenodesis location may be proximal or distal. Proximal fixation can be performed arthroscopically, and its advocates argue that keeping the LHB tendon within the bicipital groove preserves muscle strength. Boileau and Neyton<sup>11</sup> found biceps strength to be 90% that of the contralateral arm after arthroscopic tenodesis. The bicipital groove, however, is lined with synovium and is a primary site of LHB pathology. Up to 78% of intra-articular biceps tears extend through the groove outside the joint.<sup>12</sup> Proximal tenodesis thus retains a major pain generator. In a retrospective study of 188 patients, Sanders and colleagues<sup>13,14</sup> found a 36% revision rate after proximal arthroscopic tenodesis and a 13% rate after proximal open



**Figure 1.** (A) Arthroscopic image of fraying long head of biceps brachii (LHB) tendon. Patient also had medial biceps subluxation, caused in large part by partial avulsion injury of subscapularis tendon, best visualized (B) after LHB tenotomy.

**Figure 2.** Arthroscopic image of probe of long head of biceps brachii tendon to reveal synovial inflammation at tendon origin and its intertubercular portion.

tenodesis with an intact biceps sheath—significantly lower than the 3% after distal tenodesis outside the bicipital groove.<sup>1</sup>

For this reason, we advocate distal biceps tenodesis beneath the pectoralis major tendon. After tenotomy with an arthroscopic basket (Figure 3), the LHB tendon is retracted out of the glenohumeral joint by extending the elbow. For the mini-open incision, the head of the bed is lowered from the beach-chair position to 30°. The arm is abducted on a Mayo stand, and the inferior border of the pectoralis major tendon is palpated. A 3-cm vertical incision is made along the medial

arm starting 1 cm superior to the inferior pectoralis edge. The subcutaneous tissues are mobilized, and dissection is carried down to the pectoralis major and coracobrachialis tendons. Visualization of the cephalic vein indicates that the exposure is too far lateral. The horizontal fibers of the pectoralis major are identified, and a small incision through the inferior overlying fascia is directed laterally and then distally in line with the long axis of the humerus. Digital palpation helps identify the anterior humerus and fusiform LHB tendon running vertically within the intertubercular groove (Figure 4). Cephalad retraction of the pectoralis major allows direct visualization of the LHB tendon. A right-angle clamp is positioned deep to the LHB tendon and directed medial to lateral to retrieve the LHB tendon out of the incision.

No. 2 looped Fiberwire (Arthrex) is then whip-stitched from the top of the myotendinous junction up 20 mm (Figure 5). The remaining 2 to 3 cm of LHB tendon proximal to the whip-stitching may be excised to remove inflammatory tissue. The pectoralis major is retracted superiorly with an Army-Navy retractor while a pointed Hohmann retractor is placed laterally. Medial retraction of the conjoint tendon should be done carefully with a Chandler elevator and minimal levering. In a cadaveric study, Dickens and colleagues<sup>15</sup> found that the musculocutaneous nerve, radial nerve, and deep brachial artery were all within 1 cm of the standard medial retractor. Compared with internal rotation of the arm, external rotation moves the musculocutaneous nerve 11 mm farther from the tenodesis site.<sup>15</sup>

Once exposure is adequate, the appropriate length–tension of the LHB tendon must be established. The inferior edge of the pectoralis major is used as a landmark. Anatomical studies have shown that the top of the LHB myotendinous junction lies 20 to 31 mm proximal to the inferior pectoralis edge.<sup>16,17</sup> Therefore, the tenodesis site should be 2 to 3 cm superior to

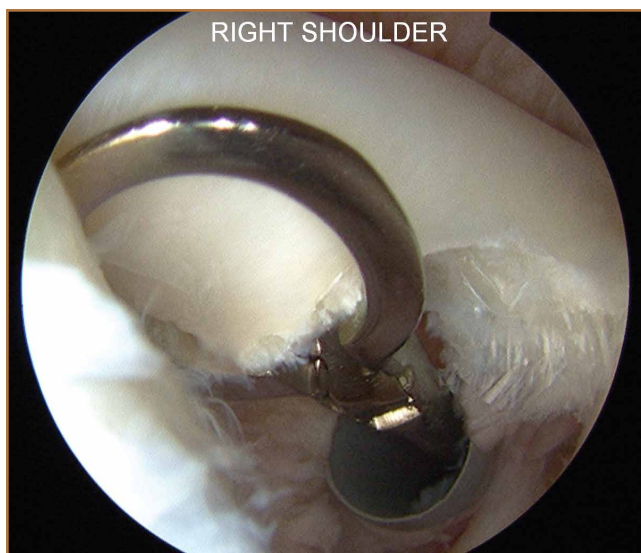

Figure 3. Arthroscopic image of tenotomy of long head of biceps brachii tendon.

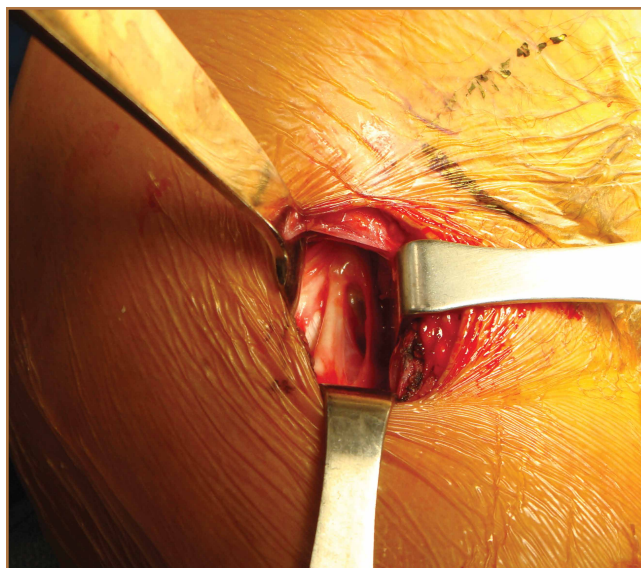


Figure 4. Small incision in fascia just inferior to pectoralis major tendon, followed by digital palpation, should reveal long head of biceps brachii tendon running vertically within intertubercular groove.

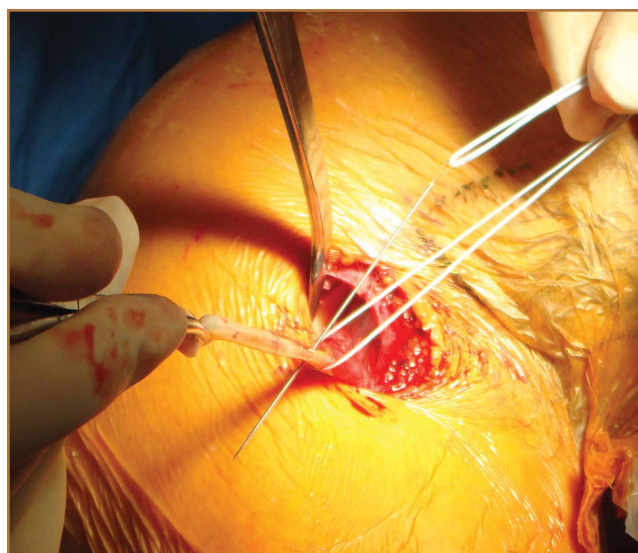

Figure 5. Looped FiberWire (Arthrex) whip-stitched from top of myotendinous junction up 15 mm.

the inferior pectoralis edge and centered on the humerus. Overall, the subpectoral location offers unique landmarks for LHB length-tensioning and provides soft-tissue coverage of the tenodesis site.

After identification of the appropriate tenodesis site, the surgeon chooses from a variety of fixation techniques. The “bone-tunnel technique” involves drilling an 8-mm unicortical hole through the anterior humerus followed by 2 smaller suture tunnels inferior to it; the LHB tendon with Krackow stitches is passed retrograde through the large hole by pulling the sutures through the smaller tunnels and tying them down.<sup>18</sup> Despite the ease of performing this type of fixation, Mazzocca and colleagues<sup>19</sup> found more cyclic displacement with bone tunnels than with interference screws and suture anchors. Other, less common techniques include the keyhole method (passing a rolled knot of LHB tendon through a keyhole in the bone)<sup>20</sup> and soft-tissue tenodesis to the rotator interval or conjoined tendon.<sup>21,22</sup> Recently, however, attention has turned mostly to interference screw and suture anchor fixation.

Multiple laboratory studies have demonstrated the superiority of interference screw fixation. Kilicoglu and colleagues<sup>23</sup> and Ozalay and colleagues<sup>24</sup> evaluated various fixation types in a sheep model, and both groups found the highest loads to failure with interference screws. Patzer and colleagues<sup>25</sup> compared interference screws and knotless suture anchors in a human cadaveric study and noted significantly higher failure loads with interference screws. Some authors<sup>26,27</sup> have presented conflicting laboratory data, and Millett and colleagues<sup>28</sup> reported no difference in clinical outcomes between interference screws and suture anchors. However, these studies have not demonstrated inferiority of interference screws, and, in light of other evidence suggesting its biomechanical superiority, we prefer interference screw fixation.<sup>19,23-25,29</sup>

Exposing the bony surface for fixation involves electrocautery and subsequent use of a periosteal elevator to reflect a 1-cm periosteal window. A guide wire is drilled unicortically through the anterior cortex at the tenodesis site and is overreamed with an 8-mm cannulated reamer (Figure 6). This tunnel is then tapped, and bone debris is irrigated and suctioned from the wound. Cadaveric studies have shown no difference in failure loads with varying screw lengths or diameters.<sup>29,30</sup> We use an 8×12-mm BioTenodesis screw (Arthrex) to match the typical width of the LHB tendon (Figures 7A-7C). One suture limb from the tendon whip-stitch is passed through the BioTenodesis screw and screwdriver. An assistant then uses a right-angle clamp as a pulley on the tendon so that the tendon may be visualized and “dunked” into the tunnel under direct visualization. As the screw is inserted, axial pressure is applied and the insertion paddle firmly held. Care should be taken to avoid overtightening the screw lest it become intramedullary. After the screw is flush to bone, the 2 whip-stitch suture limbs are tied for additional fixation.

### Postoperative Rehabilitation

The optimal postoperative protocol for subpectoral biceps tenodesis has not been rigorously studied and is guided by

the procedures performed with the biceps tenodesis. For the immediate postoperative period, Provencher and colleagues<sup>5</sup> and Mazzocca and colleagues<sup>31</sup> recommended immobilization in a sling during sleep and during the day if the patient is out in public or having difficulty maintaining the elbow flexed passively.

For isolated biceps tenodesis cases, passive- and active-assisted range of motion (ROM) of the glenohumeral, elbow, and wrist joints are permitted during the initial 4 weeks. At 3 weeks, the sling is discontinued and active ROM permitted. At 6 weeks, strengthening of the biceps, rotator cuff, deltoid, and periscapular muscles may begin with isometric contractions and progress to elastic bands and handheld weights. The same protocol is used if acromioplasty is performed at time of tenodesis. These patients may progress to active-assisted and active ROM earlier than 4 weeks if advised of the risks. However, sustained isometric biceps contraction, biceps strengthening, and resisted supination should not be performed until 6 weeks after surgery. If rotator cuff repair is performed, the patient is immobilized in a sling and passive ROM of the glenohumeral, elbow, and wrist joints is permitted during the first 6 weeks. The patient may progress to active-assisted and active ROM over the next 6 weeks, after motion is restored but before formal strengthening is initiated.<sup>32</sup> For overhead athletes, Werner and colleagues<sup>33</sup> advocated a throwing program starting 3 to 4 months after surgery.

### Outcomes and Complications

Mini-open subpectoral biceps tenodesis is a safe, reliable, and effective treatment for LHB tendon pathology. This procedure provides excellent pain relief and functional outcomes<sup>32,34,35</sup> and has a low complication rate.<sup>5,35-40</sup> At a mean of 29 months after biceps tenodesis with an interference screw, Mazzocca

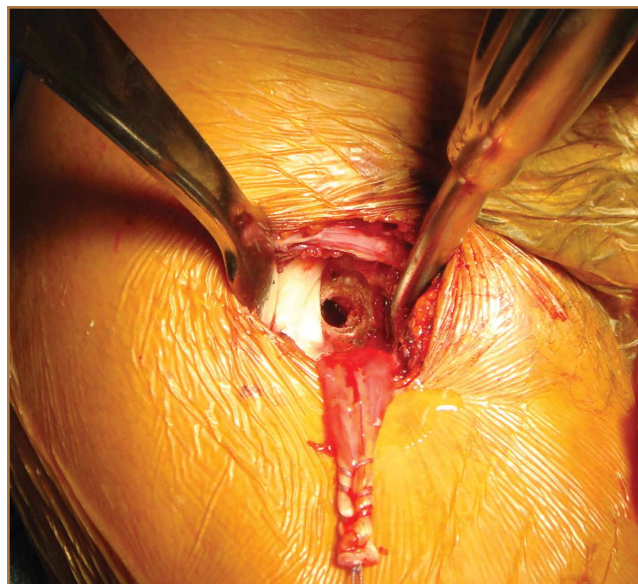
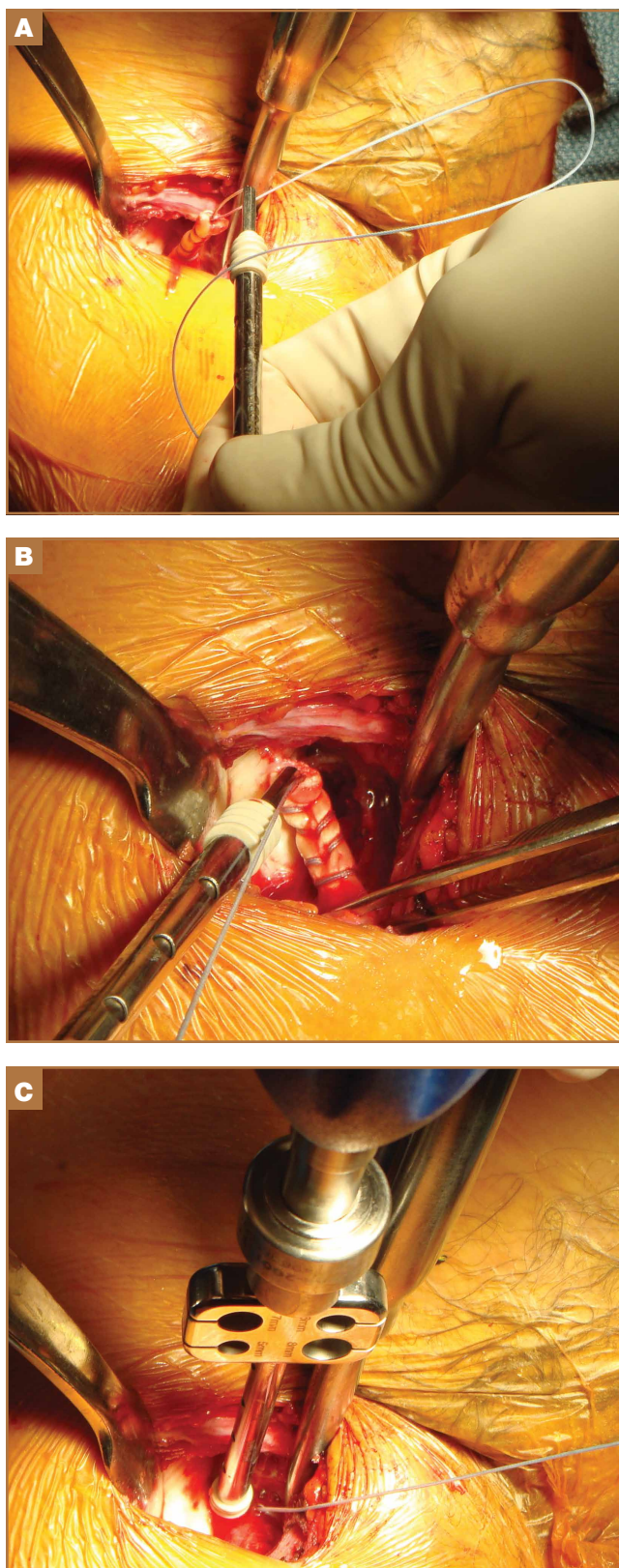


Figure 6. Unicortical drill hole 2 to 3 cm superior to inferior pectoralis edge and centered on humerus.



**Figure 7.** (A) Limb from whip-stitch fed through 8×12-mm BioTenodesis screw and screwdriver (Arthrex). (B) Screw placed firmly against tendon surface while tension is held on suture limb within screwdriver. (C) Screw then placed in predrilled hole to seat tendon in its tenodesis site.

and colleagues<sup>32</sup> found statistically significant improvements on all clinical outcome measures: Rowe, American Shoulder and Elbow Surgeons (ASES), Simple Shoulder Test (SST), Constant-Murley, and Single Assessment Numeric Evaluation (SANE). Biceps symmetry was restored in 35 of 41 patients. Millett and colleagues<sup>28</sup> reported that subpectoral biceps tenodesis relieved pain and improved function as measured by visual analog scale pain, ASES scores, and abbreviated Constant scores. Werner and colleagues<sup>34</sup> compared open subpectoral and arthroscopic suprapectoral techniques and found excellent clinical and functional outcomes with both techniques at a mean of 3.1 years. There were no significant differences in ROM, strength, or clinical outcome scores between the 2 techniques.

Potential complications include hematoma, seroma, hardware failure, reaction to biodegradable screw, persistent anterior shoulder pain, stiffness, humeral fracture, reflex sympathetic dystrophy, infection, nerve injury, and brachial artery injury. The musculocutaneous nerve can be lacerated during screw placement or even avulsed if the surgeon attempts to retrieve the LHB tendon blindly.<sup>41</sup> In the most comprehensive study of tenodesis complications, Nho and colleagues<sup>35</sup> recorded a 2% complication rate in 353 patients over 3 years. Persistent bicipital pain and fixation failure causing a Popeye deformity were the 2 most common complications (0.57% each). In a study of 103 patients, Abtahi and colleagues<sup>39</sup> found a 7% complication rate, with 4 superficial wound infections and 2 temporary nerve palsies. Millett and colleagues<sup>28</sup> reported low complication rates with both interference screw and suture anchor fixation. Neither technique had a fixation failure, and persistent bicipital groove tenderness occurred in just 3% of patients after interference screw fixation and in 7% after suture anchor fixation. Mazzocca and colleagues<sup>32</sup> documented 1 fixation failure (2%) 1 year after interference screw fixation.

Werner and colleagues<sup>34</sup> encountered stiffness more than any other complication and found it to be more common in their arthroscopic group (9.4%) than in their open group (6.0%). They used intra-articular corticosteroid injections and physical therapy to successfully treat all cases of postoperative stiffness. Humeral fracture is uncommon after tenodesis.<sup>37,42</sup> In a recent biomechanical study, however, Euler and colleagues<sup>40</sup> found a significant reduction (25%) in humeral strength after a laterally eccentric, malpositioned biceps tenodesis. This decreased osseous strength may increase susceptibility to humeral shaft fracture, especially when interference screw fixation is used. Sears and colleagues<sup>37</sup> and Dein and colleagues<sup>42</sup> presented case reports of humeral fracture after biceps tenodesis with an interference screw.

For patients with fixation failure or continued anterior shoulder pain, revision biceps tenodesis is safe and effective. Heckman and colleagues<sup>43</sup> and Gregory and colleagues<sup>44</sup> showed revision tenodesis can lead to excellent pain relief and functional outcomes, for it allows complete removal of the biceps from the groove and preserves biceps function. Gregory and colleagues<sup>44</sup> revised subpectoral biceps tenodesis for either continued pain or fixation failure and found significant

improvements in pain and function a mean of 33.4 months after surgery. Anthony and colleagues<sup>45</sup> performed biceps tenodesis for failed surgical tenotomies and autorupture of the LHB tendon. In their study of 11 patients, this surgery resulted in symptom improvement, patient satisfaction, resolution of Popeye deformity, and predictable return to activity.

## Conclusion

LHB tendon pathology is a significant source of anterior shoulder pain and functional limitation. Diagnosis and treatment of this pathology can be challenging, and it is important to identify any concomitant pathologies or other pain sources. After failed nonoperative management, surgeons have the option of mini-open subpectoral biceps tenodesis—a safe, reliable, and effective treatment with excellent outcomes. Although multiple fixation options are available, we think that, based on the current literature, fixation with a bioabsorbable interference screw remains the best option. This procedure has demonstrated efficacy for revision biceps tenodesis, failed biceps tenotomy, and autorupture of the biceps.

Dr. Levy is Fourth-Year Resident, Department of Orthopedic Surgery, Rush University Medical Center, Chicago, Illinois. Dr. Meyer is First-Year Resident, Department of Orthopaedic Surgery, Washington University School of Medicine, St. Louis, Missouri. Dr. Campbell is Assistant Professor, Department of Orthopaedic Surgery, NYU Langone Medical Center, New York, New York. Dr. Bach is Claude N. Lambert, MD—Helen S. Thompson Professor, and Director of Division of Sports Medicine, Department of Orthopedic Surgery, Rush University Medical Center, Chicago, Illinois.

Address correspondence to: David M. Levy, MD, Department of Orthopedic Surgery, Rush University Medical Center, 1611 W Harrison St, Suite 300, Chicago, IL 60612 (tel, 847-641-0209; fax, 312-942-1517; email, david\_levy@rush.edu).

*Am J Orthop.* 2016;45(2):68-74. Copyright Frontline Medical Communications Inc. 2016. All rights reserved.

## References

- Friedman DJ, Dunn JC, Higgins LD, Warner JJP. Proximal biceps tendon: injuries and management. *Sports Med Arthrosc.* 2008;16(3):162-169.
- Nho SJ, Strauss EJ, Lenart BA, et al. Long head of the biceps tendinopathy: diagnosis and management. *J Am Acad Orthop Surg.* 2010;18(11):645-656.
- Neviaser TJ, Neviaser RJ, Neviaser JS, Neviaser JS. The four-in-one arthroplasty for the painful arc syndrome. *Clin Orthop Relat Res.* 1982;163:107-112.
- Patton WC, McCluskey GM 3rd. Biceps tendinitis and subluxation. *Clin Sports Med.* 2001;20(3):505-529.
- Provencher MT, LeClere LE, Romeo AA. Subpectoral biceps tenodesis. *Sports Med Arthrosc.* 2008;16(3):170-176.
- Bennett WF. Arthroscopic repair of isolated subscapularis tears: a prospective cohort with 2- to 4-year follow-up. *Arthroscopy.* 2003;19(2):131-143.
- Dines DM, Warren RF, Inglis AE, Pavlov H. The coracoid impingement syndrome. *Bone Joint J Br.* 1990;72(2):314-316.
- Mohtadi NG, Vellet AD, Clark ML, et al. A prospective, double-blind comparison of magnetic resonance imaging and arthroscopy in the evaluation of patients presenting with shoulder pain. *J Shoulder Elbow Surg.* 2004;13(3):258-265.
- Boileau P, Baqué F, Valerio L, Ahrens P, Chuinard C, Trojani C. Isolated arthroscopic biceps tenotomy or tenodesis improves symptoms in patients with massive irreparable rotator cuff tears. *J Bone Joint Surg Am.* 2007;89(4):747-757.
- Kelly AM, Drakos MC, Fealy S, Taylor SA, O'Brien SJ. Arthroscopic release of the long head of the biceps tendon: functional outcome and clinical results. *Am J Sports Med.* 2005;33(2):208-213.
- Boileau P, Neyton L. Arthroscopic tenodesis for lesions of the long head of the biceps. *Oper Orthop Traumatol.* 2005;17(6):601-623.
- Moon SC, Cho NS, Rhee YG. Analysis of "hidden lesions" of the extra-articular biceps after subpectoral biceps tenodesis: the subpectoral portion as the optimal tenodesis site. *Am J Sports Med.* 2015;43(1):63-68.
- Sanders B, Lavery K, Pennington S, Warner JJP. Biceps tendon tenodesis: success with proximal versus distal fixation (SS-16). *Arthroscopy.* 2008;24(6 suppl):e9.
- Sanders B, Lavery KP, Pennington S, Warner JJ. Clinical success of biceps tenodesis with and without release of the transverse humeral ligament. *J Shoulder Elbow Surg.* 2012;21(1):66-71.
- Dickens JF, Kilcoyne KG, Tintle SM, Giuliani J, Schaefer RA, Rue JP. Subpectoral biceps tenodesis: an anatomic study and evaluation of at-risk structures. *Am J Sports Med.* 2012;40(10):2337-2341.
- Denard PJ, Dai X, Hanypsiak BT, Burkhart SS. Anatomy of the biceps tendon: implications for restoring physiological length-tension relation during biceps tenodesis with interference screw fixation. *Arthroscopy.* 2012;28(10):1352-1358.
- Jarrett CD, McClelland WB, Xerogeanes JW. Minimally invasive proximal biceps tenodesis: an anatomical study for optimal placement and safe surgical technique. *J Shoulder Elbow Surg.* 2011;20(3):477-480.
- Mazzocca AD, Noerdlinger MA, Romeo AA. Mini open and subpectoral biceps tenodesis. *Oper Tech Sports Med.* 2003;11(1):24-31.
- Mazzocca AD, Bicos J, Santangelo S, Romeo AA, Arciero RA. The biomechanical evaluation of four fixation techniques for proximal biceps tenodesis. *Arthroscopy.* 2005;21(11):1296-1306.
- Froimson AI, O I. Keyhole tenodesis of biceps origin at the shoulder. *Clin Orthop Relat Res.* 1975;(112):245-249.
- Sekiya JK, Elkousy HA, Rodosky MW. Arthroscopic biceps tenodesis using the percutaneous intra-articular transtendon technique. *Arthroscopy.* 2003;19(10):1137-1141.
- Verma NN, Drakos M, O'Brien SJ. Arthroscopic transfer of the long head biceps to the conjoint tendon. *Arthroscopy.* 2005;21(6):764.
- Kilicoglu O, Koyuncu O, Demirhan M, et al. Time-dependent changes in failure loads of 3 biceps tenodesis techniques: in vivo study in a sheep model. *Am J Sports Med.* 2005;33(10):1536-1544.
- Ozalay M, Akpınar S, Karaeminogullari O, et al. Mechanical strength of four different biceps tenodesis techniques. *Arthroscopy.* 2005;21(8):992-998.
- Patzert T, Santo G, Olender GD, Wellmann M, Hurschler C, Schofer MD. Suprapectoral or subpectoral position for biceps tenodesis: biomechanical comparison of four different techniques in both positions. *J Shoulder Elbow Surg.* 2012;21(1):116-125.
- Buchholz A, Martetstätler F, Siebenlist S, et al. Biomechanical comparison of intramedullary cortical button fixation and interference screw technique for subpectoral biceps tenodesis. *Arthroscopy.* 2013;29(5):845-853.
- Tashjian RZ, Henninger HB. Biomechanical evaluation of subpectoral biceps tenodesis: dual suture anchor versus interference screw fixation. *J Shoulder Elbow Surg.* 2013;22(10):1408-1412.
- Millett PJ, Sanders B, Gobeze R, Braun S, Warner JJP. Interference screw vs. suture anchor fixation for open subpectoral biceps tenodesis: does it matter? *BMC Musculoskelet Disord.* 2008;9(1):121.
- Sethi PM, Rajaram A, Beitzel K, Hackett TR, Chowaniec DM, Mazzocca AD. Biomechanical performance of subpectoral biceps tenodesis: a comparison of interference screw fixation, cortical button fixation, and interference screw diameter. *J Shoulder Elbow Surg.* 2013;22(4):451-457.
- Slabaugh MA, Frank RM, Van Thiel GS, et al. Biceps tenodesis with interference screw fixation: a biomechanical comparison of screw length and diameter. *Arthroscopy.* 2011;27(2):161-166.
- Mazzocca AD, Rios CG, Romeo AA, Arciero RA. Subpectoral biceps tenodesis with interference screw fixation. *Arthroscopy.* 2005;21(7):896.
- Mazzocca AD, Cote MP, Arciero CL, Romeo AA, Arciero RA. Clinical outcomes after subpectoral biceps tenodesis with an interference screw. *Am J Sports Med.* 2008;36(10):1922-1929.
- Werner BC, Brockmeier SF, Miller MD. Etiology, diagnosis, and management of failed SLAP repair. *J Am Acad Orthop Surg.* 2014;22(9):554-565.
- Werner BC, Evans CL, Holzgreffe RE, et al. Arthroscopic suprapectoral and open subpectoral biceps tenodesis: a comparison of minimum 2-year clinical outcomes. *Am J Sports Med.* 2014;42(11):2583-2590.
- Nho SJ, Reiff SN, Verma NN, Slabaugh MA, Mazzocca AD, Romeo AA. Complications associated with subpectoral biceps tenodesis: low rates of incidence following surgery. *J Shoulder Elbow Surg.* 2010;19(5):764-768.
- Rhee PC, Spinner RJ, Bishop AT, Shin AY. Iatrogenic brachial plexus injuries associated with open subpectoral biceps tenodesis: a report of 4 cases. *Am J Sports Med.* 2013;41(9):2048-2053.
- Sears BW, Spencer EE, Getz CL. Humeral fracture following subpecto-

## Subpectoral Biceps Tenodesis

- ral biceps tenodesis in 2 active, healthy patients. *J Shoulder Elbow Surg.* 2011;20(6):e7-e11.
38. Ding DY, Gupta A, Snir N, Wolfson T, Meislin RJ. Nerve proximity during bicortical drilling for subpectoral biceps tenodesis: a cadaveric study. *Arthroscopy.* 2014;30(8):942-946.
  39. Abtahi AM, Granger EK, Tashjian RZ. Complications after subpectoral biceps tenodesis using a dual suture anchor technique. *Int J Shoulder Surg.* 2014;8(2):47-50.
  40. Euler SA, Smith SD, Williams BT, Dornan GJ, Millett PJ, Wijdicks CA. Biomechanical analysis of subpectoral biceps tenodesis: effect of screw malpositioning on proximal humeral strength. *Am J Sports Med.* 2015;43(1):69-74.
  41. Carofino BC, Brogan DM, Kircher MF, et al. Iatrogenic nerve injuries during shoulder surgery. *J Bone Joint Surg Am.* 2013;95(18):1667-1674.
  42. Dein EJ, Huri G, Gordon JC, McFarland EG. A humerus fracture in a baseball pitcher after biceps tenodesis. *Am J Sports Med.* 2014;42(4):877-879.
  43. Heckman DS, Creighton RA, Romeo AA. Management of failed biceps tenodesis or tenotomy: causation and treatment. *Sports Med Arthrosc.* 2010;18(3):173-180.
  44. Gregory JM, Harwood DP, Gochanour E, Sherman SL, Romeo AA. Clinical outcomes of revision biceps tenodesis. *Int J Shoulder Surg.* 2012;6(2):45-50.
  45. Anthony SG, McCormick F, Gross DJ, Golijanin P, Provencher MT. Biceps tenodesis for long head of the biceps after auto-rupture or failed surgical tenotomy: results in an active population. *J Shoulder Elbow Surg.* 2015;24(2):e36-e40.

*This paper will be judged for the Resident Writer's Award.*

## 5 Points Collection From The American Journal of Orthopedics

Access Online at [www.amjorthopedics.com/articles/5-points.html](http://www.amjorthopedics.com/articles/5-points.html)

### Leading experts, including

Ahmad  
Cole

Navarro  
Frankle

Bach  
Tashjian

Pearle  
Duralde

Cohen  
Zuckerman

### Address these topics:

- Orthopedics in US Health Care
- Biceps Tenodesis and SLAP Tears
- Measurement of Resource Utilization for Total and Reverse Shoulder Arthroplasty
- Shoulder Examination of the Overhead Athlete
- Rationale for Strategic Graft Placement in Anterior Cruciate Ligament Reconstruction: I.D.E.A.L. Femoral Tunnel Position
- Using Wearable Technology to Record Surgical Videos
- Physical Examination of the Throwing Athlete's Elbow
- Total Ankle Arthroplasty
- Locking Plate Fixation for Proximal Humerus Fractures
- Unicompartamental Knee Arthroplasty
- Transtibial Anterior Cruciate Ligament Reconstruction
- Improving Rotator Cuff Healing

