Spirometry: a key diagnostic test in pulmonary medicine

JAMES K. STOLLER, MD

■ Spirometry is a simple and informative test for evaluating airflow obstruction. Measurements from a forced expiratory maneuver are conventionally displayed as volume vs time (spirogram) and flow vs volume (flow-volume loop) tracings. Spirometric measurements like the forced expiratory volume in 1 second inform about the degree of airflow obstruction, whereas the flow-volume loop helps identify the presence and anatomic location of upper airway obstruction, which may mimic symptoms of obstructive lung disease. As a simple, inexpensive, and informative test, spirometry should be used liberally in assessing patients with respiratory symptoms.

□ INDEX TERMS: SPIROMETRY □ CLEVE CLIN J MED 1992; 59:75–78

Spirometry, a key diagnostic test for pulmonary physicians and internists, is a simple method for evaluating the presence of airflow obstruction, which can also indicate the presence of bilateral diaphragm paralysis. While abnormalities on the spirogram (eg, decreased forced vital capacity) are not diagnostically specific, they may point to restrictive lung disease.

INSTRUMENTS AND TECHNIQUE

Spirometry is performed by collecting gas during timed exhalation, usually forced. One can calculate both the volume of exhaled gas and the rate of exhalation (flow rate) using either a spirometer or a pneumotachygraph. The spirometer serves as a volume collection chamber, whereas the pneumotachygraph measures the rate of gas flow. Whichever measurement is made, the results can be rendered as a volume-time tracing (*Figure 1*) or flow-volume loop (*Figure 2*).

If exhaled gas is collected, flow rates for the flow-volume loop are calculated electronically by determining the first derivative of volume with respect to time, or the slope of the volume-time tracing, and plotting it against exhaled volume, thus creating a flow-volume loop (*Figure 2*). On the other hand, if flow rates are measured, exhaled volume is calculated by integrating the flow rate with respect to time, thus determining the exhaled volume. To create a volume-time tracing, the volume is plotted against exhalation time (*Figure 1*).

Most currently marketed spirometers can display data as a volume-time tracing, as a flow-volume loop, or both. The data needed to generate either type of display are the same. However, variations in the shape of the flow-volume loop have been found to be especially helpful in the diagnosis of upper airway obstruction.

CHRONIC OBSTRUCTIVE PULMONARY DISEASE

In patients with chronic obstructive pulmonary disease (COPD), such as chronic bronchitis or emphysema, spirometry demonstrates a characteristic

From the Department of Pulmonary Disease, The Cleveland Clinic Foundation.

Address reprint requests to J.K.S., Department of Pulmonary Disease, The Cleveland Clinic Foundation, 9500 Euclid Avenue, Cleveland, OH 44195.

This article is adapted from a talk given at The Cleveland Clinic Foundation's "Intensive Review of Internal Medicine" course.

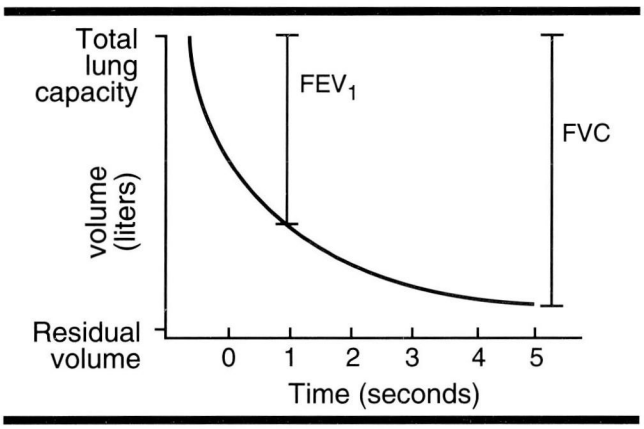

FIGURE 1. Volume-time tracing showing spirometry results when pulmonary function is normal. (FEV_1, forced expiratory volume in one second; FVC, forced vital capacity)

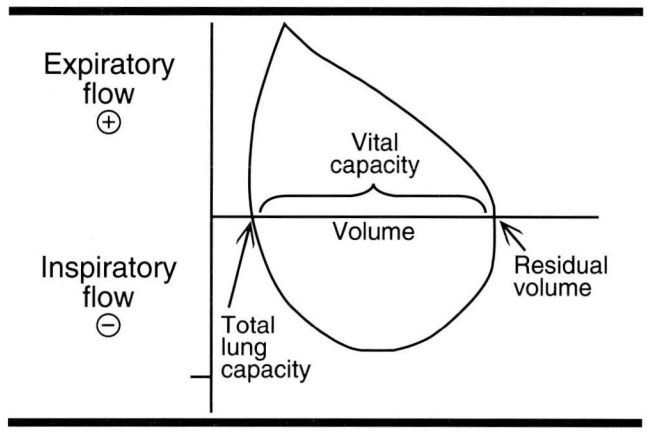

FIGURE 2. Flow-volume loop showing normal pulmonary function.

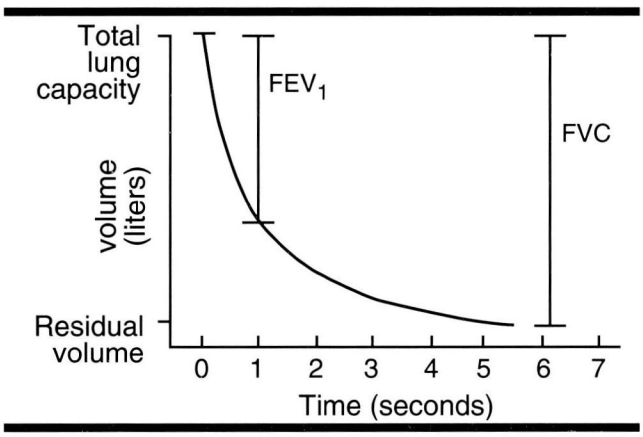

FIGURE 3. Decline in FEV_1 in a patient with COPD. Both FEV_1 and FEV_1/FVC ratio are depressed compared with values measured in patients with normal pulmonary function (see *Figure 1*). (FEV_1, forced expiratory volume in one second; FVC, forced vital capacity)

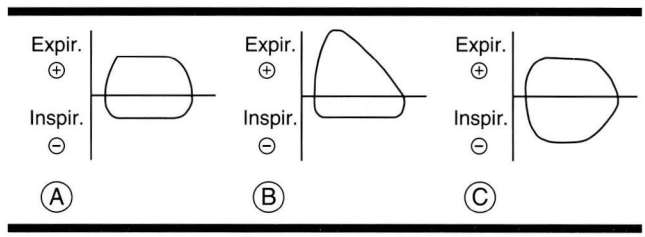

FIGURE 4. Three characteristic deviations from the normal flow-volume loop. *A* Fixed upper airway obstruction, in which both the expiratory and inspiratory portions of the flow-volume loop are flattened. *B* Dynamic extrathoracic airway obstruction, in which the expiratory limb of the loop remains normal and the inspiratory limb is flattened. *C* Dynamic intrathoracic airway obstruction, in which the inspiratory limb remains unchanged and the expiratory limb is flattened.

decline in forced expiratory volume in one second (FEV_1) (*Figure 3*). In these patients, the forced vital capacity is usually preserved if they can sustain expiration long enough, although they may need more time to empty their lungs than the 3 to 4 seconds required by the person with normal pulmonary function.[1,2] As a result, the ratio between FEV_1 and forced vital capacity (FVC) is usually low in COPD patients. Patients with asthma but no other lung problems generally have normal airflow between episodes; during exacerbations of the disease, however, they too have a decline in FEV_1 and in FEV_1/FVC, so that this ratio falls below 0.75, which approximates normal.

Flow-volume loop as a diagnostic indicator

The flow-volume loop is especially helpful as a diagnostic tool in patients with upper airway obstruction—that is, obstruction at the level of the pharynx, larynx, or proximal upper airway, including the trachea and mainstem bronchi.[2–6] Traditionally, the flow-volume loop is performed during both expiration and inspiration; by convention, expiratory flow is positive and inspiratory flow is negative. The normal flow-volume loop has a characteristic configuration (*Figure 2*).

Flow-volume loop deviations

Three characteristic deviations from the normal flow-volume loop suggest various forms of upper airway obstruction (*Figure 4*). To understand these variations, one must consider the pressure gradient across the air-

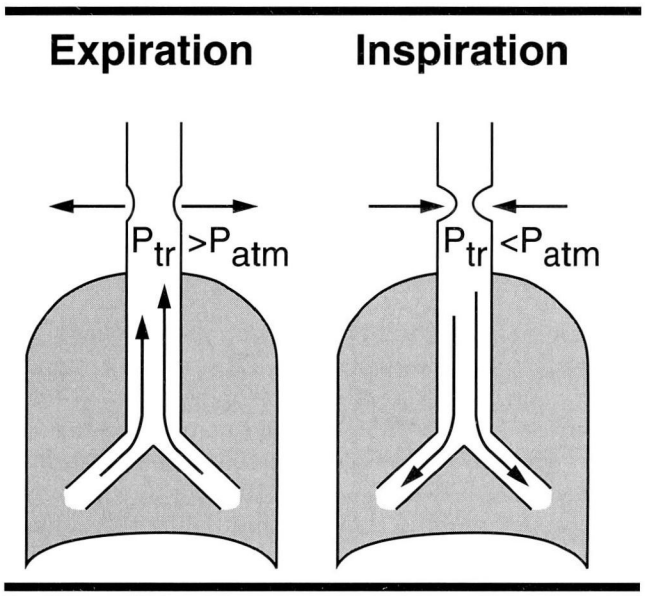

FIGURE 5. Effect of expiration and inspiration on dynamic or non-fixed extrathoracic airway obstruction. *Left* During forced expiration, intratracheal pressure (P_{tr} exceeds the pressure around the airway (P_{atm}), or atmospheric pressure), lessening the obstruction. *Right* During forced inspiration, when pressure around the airway is greater, the obstruction worsens. (Adapted from Kryger MH, Bode F, Antic R, Anthonisen N. Diagnosis of obstruction of the upper and central airways. Am J Med 1976; 61:85-93)

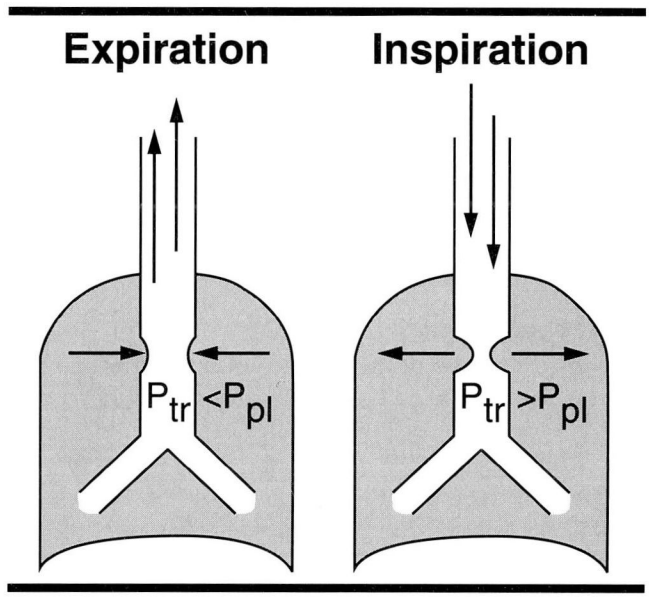

FIGURE 6. Effects of expiration and inspiration on dynamic or non-fixed intrathoracic airway obstruction. *Left* During forced expiration, pressure exerted around the airway (P_{pl}, or pleural pressure) may exceed intratracheal pressure (P_{tr}), worsening the obstruction. *Right* During forced inspiration, intratracheal pressure is greater, relieving the obstruction. (Adapted from Kryger MH, Bode F, Antic R, Anthonisen N. Diagnosis of obstruction of the upper and central airways. Am J Med 1976; 61:85-93)

way walls during inspiration and expiration.[3,4] During inspiration, intrapleural pressure is negative, so atmospheric gas flows into the alveoli across the gradient from higher to lower pressures. (By convention, the pressure of atmospheric gas is taken as 0.) The situation reverses during exhalation; as intrapleural pressure becomes more positive relative to atmospheric pressure, gas leaves the lungs and moves to the outer atmosphere, which is now lower in pressure.

It stands to reason that any fixed obstruction to airflow in the upper airways will produce a decrement in flows during both expiration and inspiration; examples are fixed tracheal stenosis and tracheal obstruction by tumors. Airflow obstruction during expiration may manifest as wheezing, whereas obstruction during inspiration may be heard as stridor (a wheezing sound on inspiration). Spirometric evidence of expiratory obstruction is seen as a flattening of the expiratory (positive) limb of the flow-volume loop, while inspiratory obstruction is seen as flattening of the inspiratory (negative) portion of the loop (*Figure 4, A*).

Some conditions produce so-called "dynamic" obstruction—that is, no fixed airway obstruction is evident. In this type of obstruction, the limitation of airflow is confined to either inspiration or expiration, but not both. Spirometry reveals an abnormality of the inspiratory or expiratory limb of the flow-volume loop. The abnormalities in the flow-volume loop that are seen in upper airway obstruction are best understood by considering upper airway passages as either extrathoracic (falling outside the thoracic inlet) or intrathoracic (inside the chest cavity) (*Figures 5 and 6*).[3,4,6] In extrathoracic upper airway obstruction, the inspiratory limb of the flow-volume loop is flattened, while the expiratory limb maintains a normal shape (*Figure 4, B*). Examples of conditions that produce dynamic obstruction of extrathoracic upper airways include tracheomalacia and vocal cord paralysis. In contrast, dynamic intrathoracic obstruction produces flattening of only the expiratory limb of the flow-volume loop; the inspiratory limb remains unchanged (*Figure 4, C*). Examples of conditions that cause dynamic intrathoracic upper airway obstruction include tracheomalacia of the intrathoracic airway and

tumors that straddle the main carina.

ILLUSTRATIVE CASE

Case presentation

A 35-year-old woman who recovered from a motor vehicle accident 18 months earlier presented with dyspnea. She had been hospitalized and on mechanical ventilation for 3 months after the acute trauma, requiring tracheostomy after 10 days of translaryngeal intubation.

Physical examination showed wheezing that was unresponsive to inhaled bronchodilators. Spirometry was performed, and the flow-volume loop resembled that seen in *Figure 4, A*.

Comment

This patient had developed fixed tracheal stenosis as a complication of her prolonged intubation. Granulation tissue had formed at the site of the cuff of the endotracheal tube and caused tracheal obstruction which was physiologically "fixed" (ie, present on both inspiration and expiration). The flow-volume loop confirmed the diagnosis, further evaluation of which might include imaging radiographically (by computed tomography of the trachea) or endoscopically (by bronchoscopy).

CONCLUSION

Spirometry is a key test for internists and pulmonologists for several reasons. First, spirometry permits diagnosis of a broad spectrum of diseases, all of which may cause wheezing and/or dyspnea but which differ in pathophysiology and treatment. Examples of the wide spectrum include COPD, asthma, tracheal obstruction, and bilateral diaphragm paralysis. Second, spirometry can provide key information for making management decisions regarding patients with airflow obstruction; for example, asthmatics with severe acute airflow and failure to respond to initial therapy should be considered for hospitalization. Third, spirometric measures of airflow obstruction are important correlates of general medical health and can be helpful in reinforcing medical advice to modify harmful behavior such as cigarette smoking. Fourth, spirometry is easy to perform in the office setting with a variety of commercially available devices.

REFERENCES

1. Stoller JK, Wiedemann HP. Chronic obstructive lung diseases: asthma, emphysema, chronic bronchitis, bronchiectasis, and related conditions. In: George RB, Light RW, Matthay MA, Matthay RA, eds. Chest Medicine. Baltimore: Williams and Wilkins. 1990:161–208.
2. Bass H. The flow volume loop: normal standards and abnormalities in chronic obstructive pulmonary disease. Chest 1973; **63(2):**171–176.
3. Kryger MH, Bode F, Antic R, Anthonisen N. Diagnosis of obstruction of the upper and central airways. Am J Med 1976; **61:**85–93.
4. Acres JC, Kryger MH. Clinical significance of pulmonary function tests: upper airway obstruction. Chest 1981; **80(2):**207–211.
5. Miller RD, Hyatt RE. Obstructing lesions of the larynx and trachea: clinical and physiologic characteristics. Mayo Clin Proc 1969; **44:**145–161.
6. Golish JA, Ahmad M, Yarnal JR. Practical application of the flow-volume loop. Cleve Clin Q 1980; **47(1):**39–45.