

ROENTGEN ASPECTS OF DISEASES OF THE COLON

E. N. COLLINS, M.D.

In carcinoma of the colon, the roentgen examination is the most important diagnostic procedure. Diverticulitis, ulcerating processes, polyposis, benign strictures, megacolon, and other diseases which affect the luminal contour of the colon, although more rarely encountered, are similarly disclosed by this examination. In infectious granulomata, the location and extent of the disease is usually determined by the roentgen examination. The most frequently encountered disturbances of the colon are functional disorders, and the value of the roentgen examination, both from the standpoint of exclusion as well as from the standpoint of furnishing aids to effective treatment, is well recognized.

In the presence of amebiasis, roentgen studies are seldom indicated or helpful, except that they furnish important negative evidence in cases where the diagnosis is unusually difficult. The diagnosis of carcinoma of the rectum is made by the clinical history, digital and proctoscopic examinations. Conditions which are primarily outside the lumen of the colon, such as sarcoma or Hodgkin's disease, or metastases, may give no roentgen evidence of abnormality. This applies to all parts of the gastro-intestinal tube¹.

In advanced lesions affecting the luminal contour of the colon, the interpretation of the roentgen findings is usually obvious. This discussion will emphasize the early roentgen findings as well as the early clinical manifestations of diseases of the colon wherein the roentgen examination is important, in the hope that in the future, the roentgenologist will make examinations earlier in the course of the disease.

The earliest roentgen evidence of abnormal anatomical change in the colon is revealed by the careful fluoroscopic observation of the opaque enema as it enters each segment of the colon, using palpatory manipulation to separate the redundant loops as well as to detect early induration, together with the use of the double contrast method of Fischer^{2,3}, as modified by Weber⁴, in which air or gas insufflation is employed after the expulsion of the opaque enema.

However, the customary fluoroscopic and film examinations alone are usually sufficient, provided observations *after the expulsion of the enema* are included. At this time sufficient barium will have adhered to the mucosa to permit visualization of early changes in the mucosal pattern and confusing redundancies will have disappeared because of the contraction of both the longitudinal and circular musculature of the colon. Films which are made after the expulsion of the barium enema will often give more information relative to an early lesion than those made when

the colon is completely distended with the opaque medium, but films made at both stages of the examination should routinely be made, because each stage supplements the other. If the findings are indeterminate when these examinations are completed, the double contrast method may be used.

The double contrast method involves unusual attention to details. Following the expulsion of the barium enema, if considerable barium has regurgitated through the ileocecal valve into the small intestine, or too much barium remains in the colon, the examination should be delayed a few hours until fluoroscopic observation shows only a small amount of barium in the colon. The patient has little or no discomfort if the air or gas enters the rectum slowly and evenly. We use two graduated bottles, one filled with water and elevated three feet while the other is placed on the fluoroscopic table. While water runs through rubber tubing from the upper to the lower bottle, air is displaced in the latter which passes through rubber tubing and the rectal tip to distend the colon. This is done under fluoroscopic control while the patient rotates into the most advantageous positions. The quantity of air injected can be determined at any time by observing the fluid level in the upper bottle. Stereoptican films are made after there is sufficient air or gas insufflation to furnish contrast between a lesion which may project into the lumen and the luminal contour itself. These are visualized by the adherence of the barium to the mucosal surfaces. Later, if the patient should have difficulty in expelling the air, the reclining position and side to side rotation with the hips elevated will prove useful.

Preparation for the roentgen examination is usually satisfactory when vegetables and fruit are withheld from the diet for the day preceding, together with cleansing enemas two hours prior to the examination. If an early non-obstructing lesion is suspected, an important additional procedure is the use of two ounces of castor oil given by mouth twenty-four hours prior to the examination. This may preclude difficulty in differentiating between inspissated fecal material and polypoid lesions, especially if pedunculated. If there is clinical evidence of an obstructing lesion, when preliminary catharsis is contraindicated, a plain film of the abdomen alone may furnish sufficient evidence for localization of the lesion.

CARCINOMA

Metastases from carcinoma of the colon occur relatively late in the course of the disease and, therefore this condition should be curable. The problem is to get the patient to the roentgenologist earlier in the course of the disease. Surgeons are still encountering inoperable lesions. This may be due to delay on the part of the patient, to the insidious nature of the disease, or to delay on the part of the clinician in requesting

ROENTGEN ASPECTS OF DISEASES OF THE COLON

a roentgen examination. Emphasis should be placed on the early clinical features as well as on the early roentgen evidence of the disease.

The most significant early symptom which calls for a roentgen examination is an unexplainable change in bowel habits, particularly if an unusual attack of diarrhea, although slight, has been present. The patient's knowledge of blood in the stools is often a late symptom. An unexplained secondary anemia, even though no gastro-intestinal symptoms are present, should direct attention to the right colon, as well as to the pars media of the stomach. However, the blood count may be normal and there may be no palpable mass. Pain is usually absent in the early stage of the disease. If present, pain is frequently indefinite and misleading because it occurs at a distance from the lesion. Symptoms of obstruction, regardless of degree, will, of course, suggest the presence of carcinoma.

In considering the early gross pathologic changes, it is well to remember that the lesion starts in the mucous membrane as an adenocarcinoma. Although the growth then predominantly infiltrates the wall of the colon, there is also some intraluminal projection of epithelial elements, particularly at the margins of the growth where irregular ridges are formed. This process then spreads in a circular fashion as well as longitudinally. Ulceration occurs, so that the lumen becomes irregular as well as narrower.

The early lesions are encountered more often in the left half of the colon because patients usually come to the physician earlier in the course of the disease because of symptoms of obstruction. The smaller size of the lumen, the thicker wall, and the fact that the fecal current is in a more solid state in this portion of the colon result in relatively early symptoms. A lesion which would involve only a part of the circumference of the right colon would completely encircle the left colon, producing an annular lesion. In the right half of the colon, where the lumen is large, the wall thin, and the fecal current in a liquid state, obstructive symptoms occur very late, if at all. In addition to the diffuse infiltration in the bowel wall, sufficient time will have elapsed so that often a fungating, cauliflower-like mass which projects into the lumen may exist before the patient is aware of its presence.

Therefore, in the roentgen examination, unusual care is needed in visualizing an early lesion in the *left* colon. (Fig. 1.) During the initial fluoroscopic examination, the head of the barium stream must be observed closely, while the patient is constantly rotating in the most favorable positions and the examiner separates one loop of the colon from another. At the same time, any questionable area is palpated for evidence of induration or mass formation. In the presence of an early lesion, only slight narrowing of the lumen where the marginal ridges

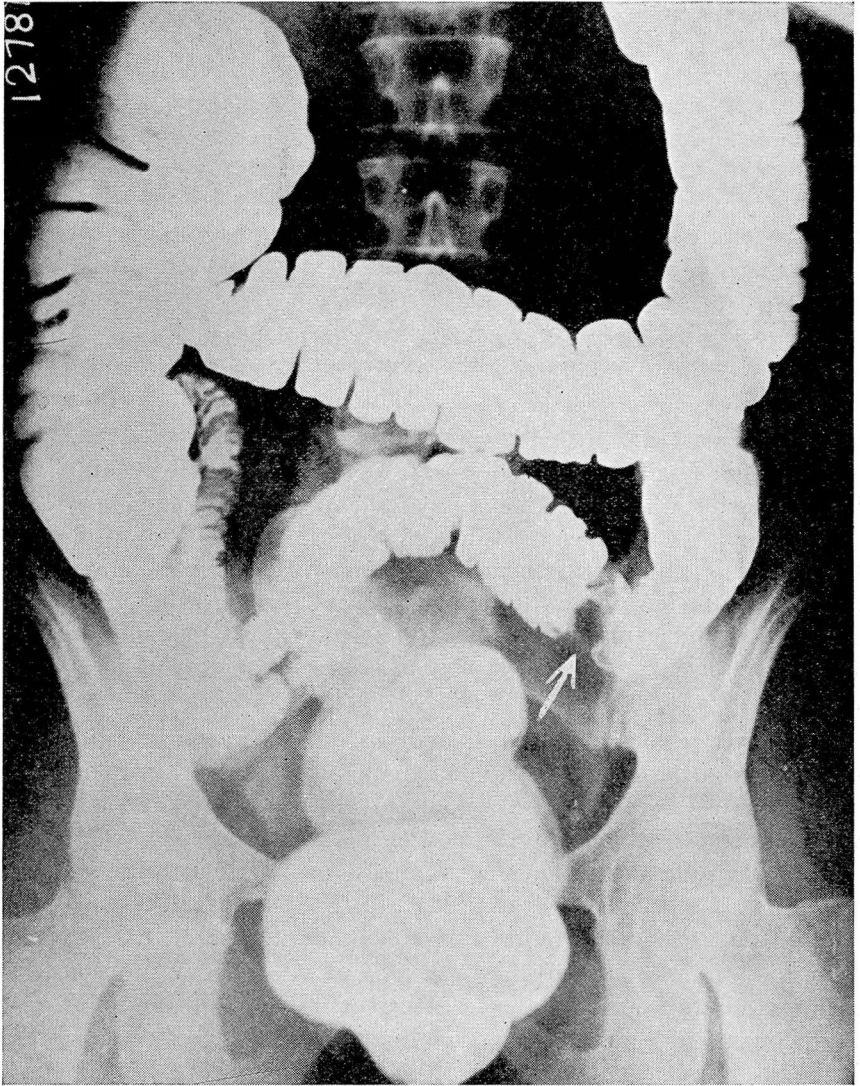


FIGURE 1.—Early adenocarcinoma of sigmoid colon. Note the short segment involved and the sharp demarcation between the normal and abnormal bowel wall. The patient had had two or three small hemorrhages from the rectum, but the blood counts were normal. Resection and end-to-end anastomosis was performed four years ago. The patient is now feeling entirely well and there is no evidence of recurrence.

of the growth project into the lumen together with some evidence of induration by palpation, may be observed.

As soon as any evidence of neoplasm is observed during the initial fluoroscopic examination, the flow of the barium stream should be stopped and films made both before and after the enema is expelled.

ROENTGEN ASPECTS OF DISEASES OF THE COLON

If the findings are still indeterminate during the subsequent fluoroscopic examination, the double contrast method should be used.

Later in the course of the disease, a definite circular filling defect (subtraction from lumenal contour where the growth projects into the lumen), together with an eccentric irregular channel and evidence of more induration, will be present. This finding is usually termed the "napkin ring" deformity. A mass, palpable under the fluoroscope, corresponding to the filling defect may not be present at the time of the examination unless the disease has progressed to the stage of definite obstruction. Under such circumstances, only the lower border of the lesion may be visualized by the use of the barium enema, and the mass may represent inspissated fecal material proximal to the lesion. Dilatation of the colon proximal, as well as distal, to the lesion may be observed. In all cases of carcinoma of the left colon, there usually is involvement of a comparatively short segment of the colon, together with a sharp demarcation between the normal and abnormal bowel wall. Stopping the barium enema as soon as a lesion is encountered is unusually important in the case of an obstructing lesion. If more barium is allowed to enter, acute obstruction may be caused by the barium above the lesion, to say nothing of difficulty in making satisfactory roentgenograms. A dilated redundant loop of colon may cover the involved area.

Following air or gas insufflation which is done in the absence of an obstructing lesion, the enema tip may be reinserted and the colon completely filled with the barium suspension under fluoroscopic observation, after which the usual films are made. Again, the film made after expelling the enema may show the lesion to best advantage.

The examination of the splenic and hepatic flexures may present difficulties because palpatory manipulation during the fluoroscopic examination may not be possible. Deep breathing and rotation into the most favorable positions on the part of the patient, together with the intermittent stopping and starting of the barium stream, will facilitate this part of the examination.

Examination of the right colon in the presence of a neoplasm is usually less difficult because of the gross pathologic features mentioned above. The intraluminal projection of the growth is apt to produce a more extensive irregular filling defect than that encountered in the left colon, and a definite mass corresponding to the defect is often present (Fig. 2).

POLYPOSIS

Except in the presence of inflammation, such as ulcerative colitis, we have found polyposis of the colon to be a rare condition. It is often suspected when a patient gives a history of bleeding or obstruction, pos-

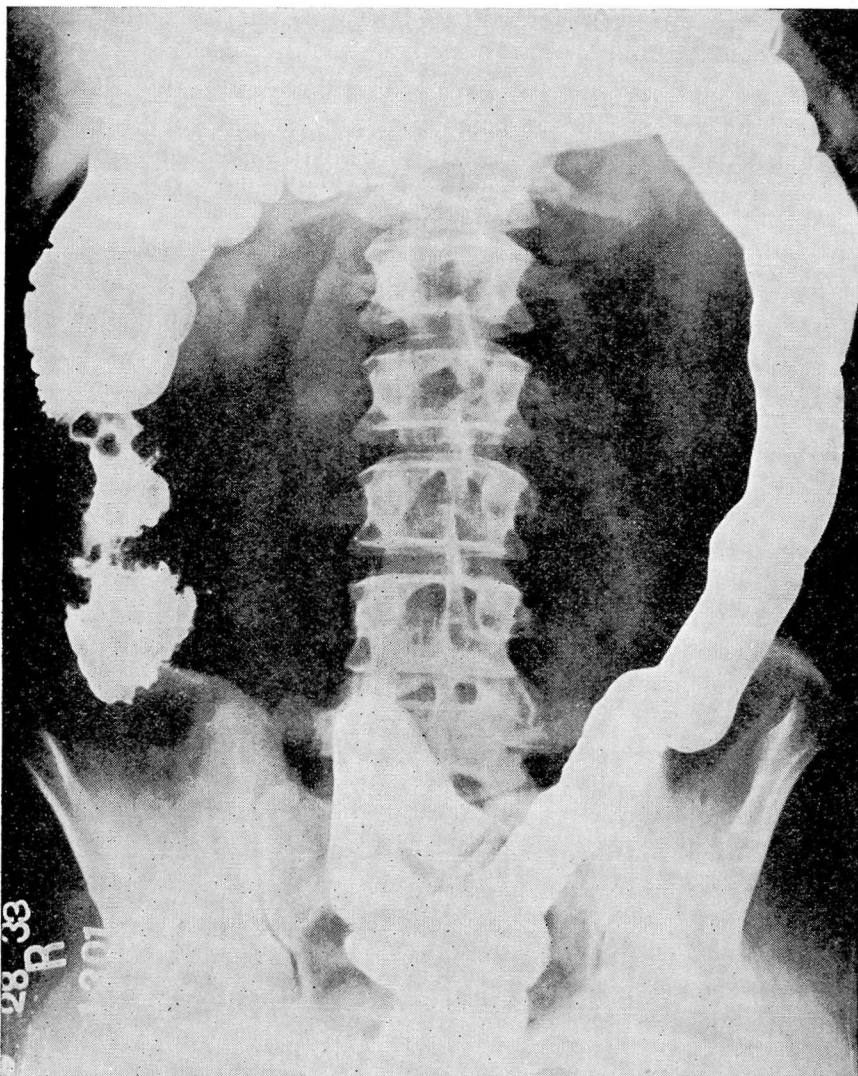


FIGURE 2.—Extensive adenocarcinoma of cecum and ascending colon. A physician, age 38, complained of weakness, loss of weight, and “some gas pains” for preceding two years. During past year, had had intravenous iron therapy. Blood count was 3,260,000 red cells with a hemoglobin of 35 per cent. At operation metastases were extensive.

sibly due to intussusception, or during the routine clinical examination, when an unexplained anemia is found. Since the presence of inspissated fecal material is the most common obstacle to accurate roentgen interpretation in this condition, it is obvious that thorough preparation of the patient is necessary before the initial barium enema is administered. The most important part of the roentgen examination is the air or gas insuffla-

ROENTGEN ASPECTS OF DISEASES OF THE COLON

tion after the expulsion of the barium enema, as emphasized by Weber⁴ (Fig. 3 and 4). The roentgen features mentioned relative to the detection of an early carcinomatous lesion also apply to polyposis, for each polyp which projects into the lumen of the colon produces a filling defect. However, since there is usually little evidence of infiltration or induration of the bowel wall, there is little if any change in the luminal contour or haustral markings. Polyposis of the colon may undergo malignant change. If surgical investigation is not made, progress roentgen studies should be employed (Fig. 8).

DIVERTICULOSIS AND DIVERTICULITIS

In a series of 3000 roentgen examinations of colons, the incidence of diverticulosis was 6.6 per cent. Diverticula of the gastro-intestinal tract are most frequently encountered in obese individuals over 50 years of age. It is difficult to determine accurately the incidence of diverticulitis because operative interference has seldom been required. The site of predilection is the sigmoid colon and a smaller number of diverticula are often found in the descending colon. Occasionally there is a diffuse diverticulosis which involves all parts of the colon, or the diverticula may be confined to the right colon. Roentgenologically, the diverticula may be visualized at one examination and not at another, depending upon the fecal content at the time of the examination.

From a pathologic standpoint, the diverticula appear first as small pits in the mucosa and submucosa; later, the mucosa herniates through the muscle layers so that little, if any, muscle tissue surrounds the extraluminal sacs. If the diverticula become infected, the inflammation may be acute or chronic with acute exacerbations, and the formation of abscesses and fistulas may constitute complications. The latter may burrow to the adjacent intestine, urinary bladder, or even to the outer surface of the body.

Diverticulitis should be suspected when the patient has the so-called symptoms and signs of left-sided appendicitis, or when a history is given of recurring attacks of intestinal obstruction associated with fever and marked tenderness, if not with a tender palpable mass in the left lower quadrant, which have recurred over a relatively long period of time. It should be noted, however, that the chief symptoms due to diverticulitis of the colon may be those of a urinary disturbance, due to extension of the process to the bladder wall.

Diverticula of the colon may be found during a routine gastro-intestinal roentgen examination following ingestion of the barium meal by mouth, together with the barium enema examination, and they are *often asymptomatic* (Fig. 5). If there is any evidence of obstruction, a plain

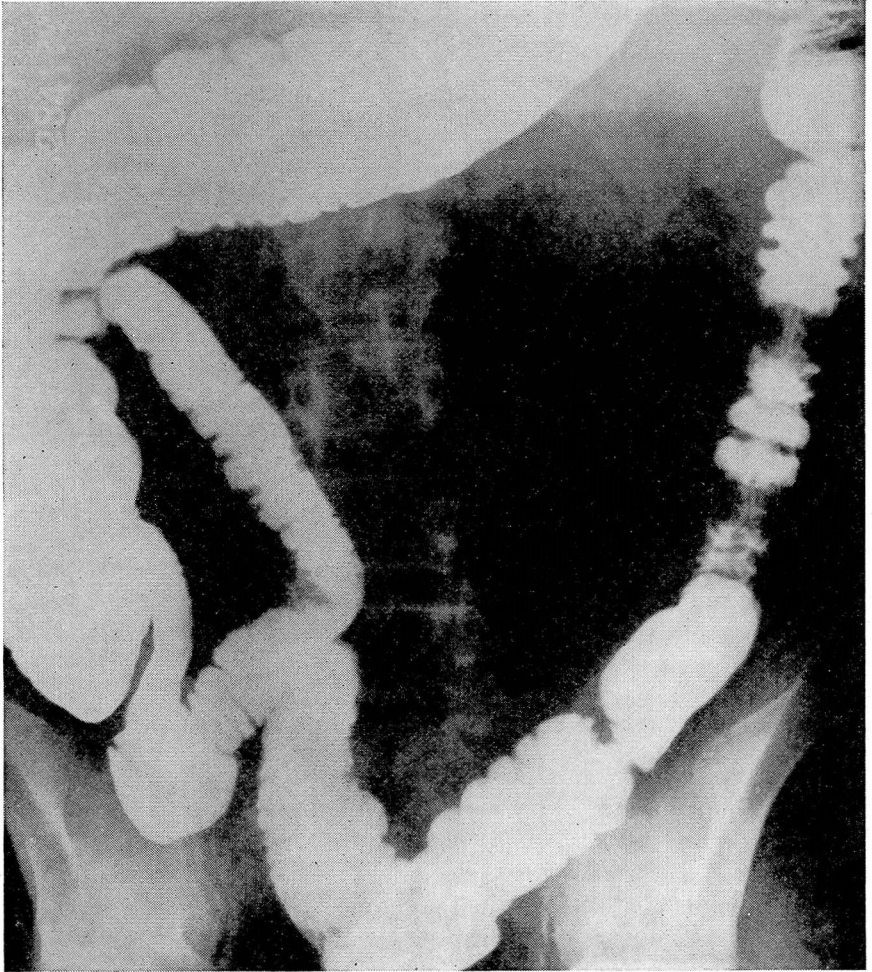


FIGURE 3.—Adenomatous polyposis of the rectum and sigmoid colon with early carcinomatous change in the rectal polypi. The usual roentgenogram taken when the colon is distended with barium suspension shows no abnormality in sigmoid colon.

film of the abdomen, followed by the barium enema examination, should be done before barium is given by mouth. If the examination is made when complete obstruction is present, in order to determine the nature of the lesion, a reëxamination may be necessary following a few days' medical management. This includes correction of body chemistry and the use of antispasmodic drugs to full physiologic effect. Even under these circumstances, the roentgen evidence may simulate that of carcinoma, but usually a longer segment of the colon is involved, characteristic serrated borders are visualized and often other diverticula are apparent (Figs. 6 and 7). In our experience, the presence of both carci-

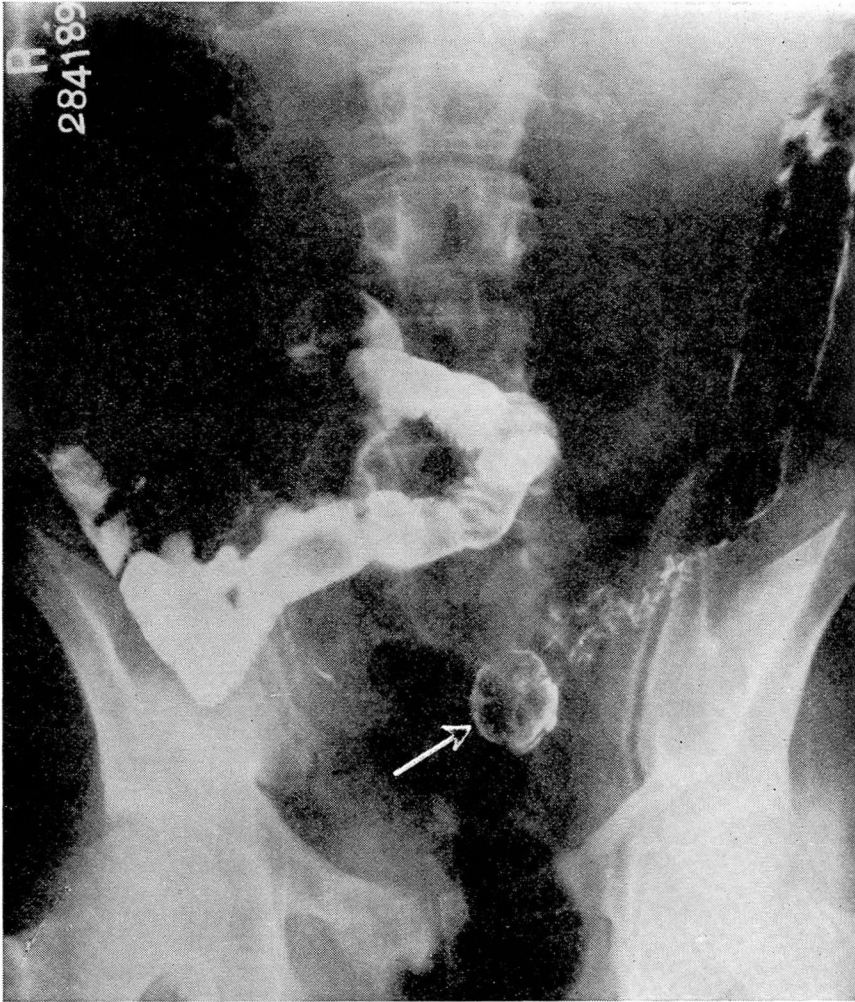


FIGURE 4.—Same case as Figure 3. Adherence of barium suspension to a large adenomatous polyp in sigmoid colon by use of the double contrast method (insufflation of air) after expulsion of the barium enema.

noma and diverticula in the same segment of the colon, although it has been observed, is a rare occurrence. If any question remains regarding the nature of the lesion, twenty-four and possibly forty-eight hour films should be made, or a reëxamination should be done in a week or ten days. Marked tenderness and a comparatively long boggy mass is often a finding revealed during the fluoroscopic examination, in addition to the roentgen findings of diverticulitis mentioned above. The proctoscopic examination usually reveals no abnormal findings because the mucosa has a normal gross appearance.

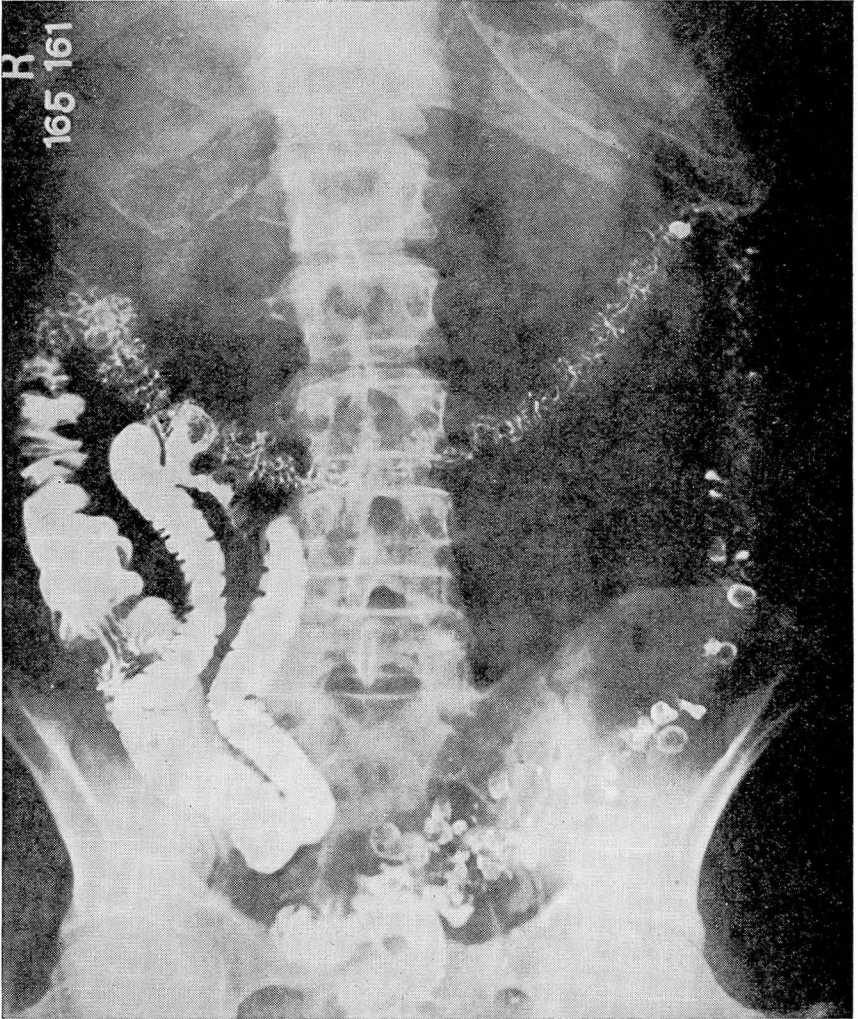


FIGURE 5.—Diverticulosis of left colon after expulsion of the barium enema.

BENIGN STRICTURE OF THE INTESTINE

Benign stricture of the intestine due to irradiation of carcinoma of the cervix uteri has been found in seven of 451 cases, an incidence of 1.5 per cent. Although this apparently is a rare condition, its presence should be suspected when a patient gives a history suggesting partial or intermittent intestinal obstruction subsequent to the original radiation therapy. This is a curable condition which may be encountered months or several years after irradiation, and its incidence, where metastatic lesions from a carcinoma of the uterine cervix are suspected, may be

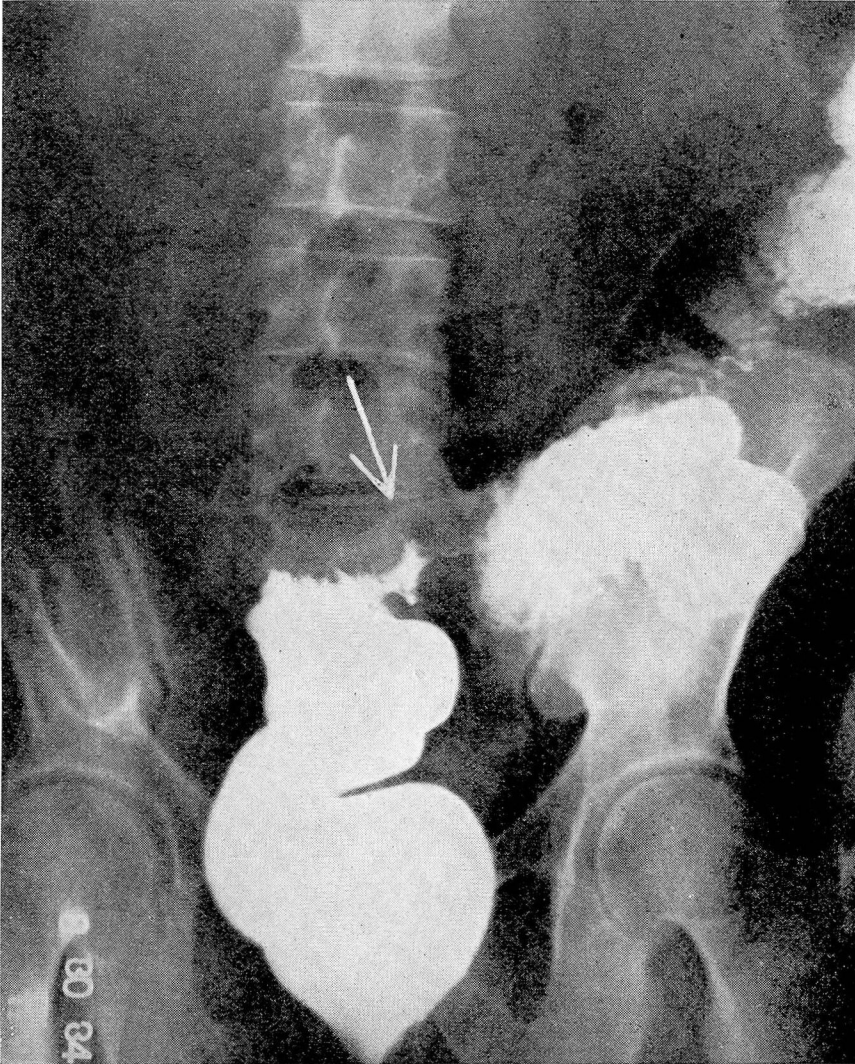


FIGURE 6.—Obstruction in sigmoid colon due to diverticulitis. Note length of segment involved, serrated channel, and dilatation of colon proximal and distal to the involved area.

greater than has heretofore been recognized. Roentgenologically, benign stricture due to this cause results in a narrow contraction of the lumen of the intestine which is most frequently found in a redundant sigmoid colon and is often fixed in position. This condition has been discussed in detail elsewhere⁵.

CHRONIC ULCERATIVE COLITIS

Although the diagnosis of chronic ulcerative colitis is usually made by proctoscopic examination and examination of the stools, the roentgen

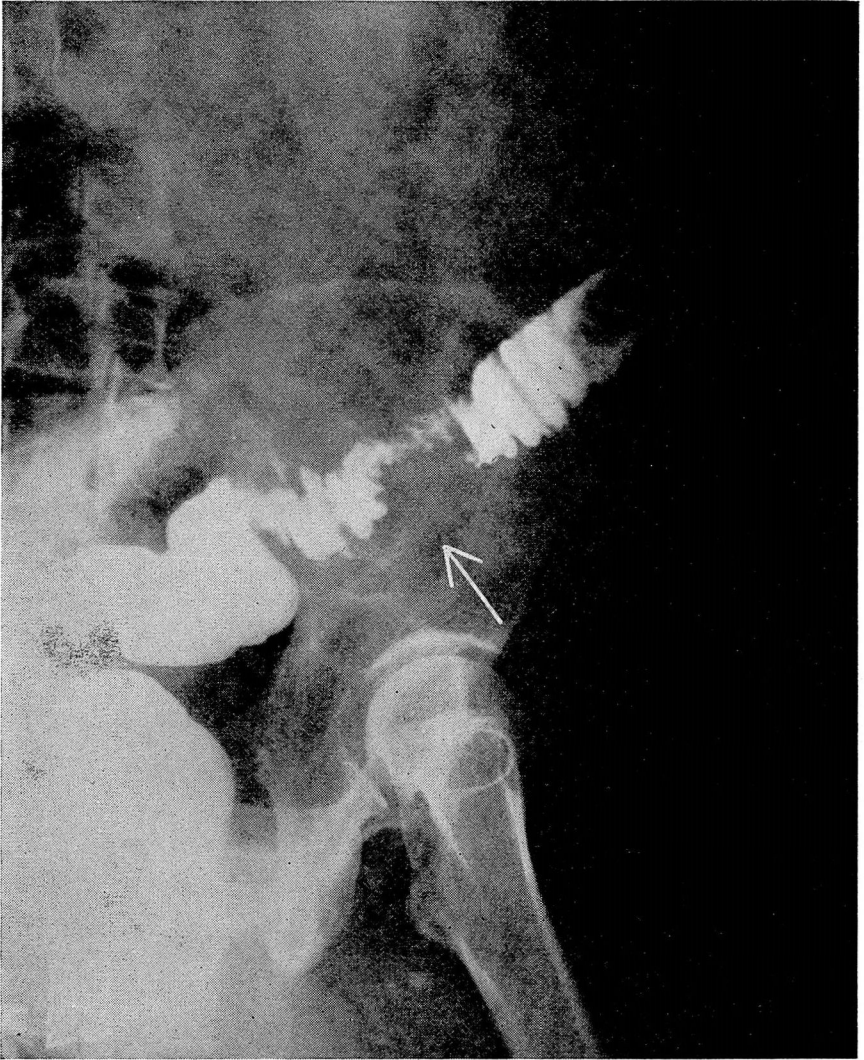


FIGURE 7.—Same case as Figure 6 one month after colostomy. Note visualization of diverticula, length of segment involved, and disappearance of dilatation of colon proximal and distal to the involved area. The colostomy was subsequently closed.

examination is often required to furnish evidence relative to the segment of the colon involved, the extent of the disease, and whether polyposis is a complication (Fig. 8). Occasionally, unsuspected ulcerative colitis is found during the course of a routine roentgen examination of the gastro-intestinal tract following the ingestion of barium by mouth.

Early in the course of the disease, the roentgen examination of the colon may show only a lack of the usual haustral markings, together

ROENTGEN ASPECTS OF DISEASES OF THE COLON

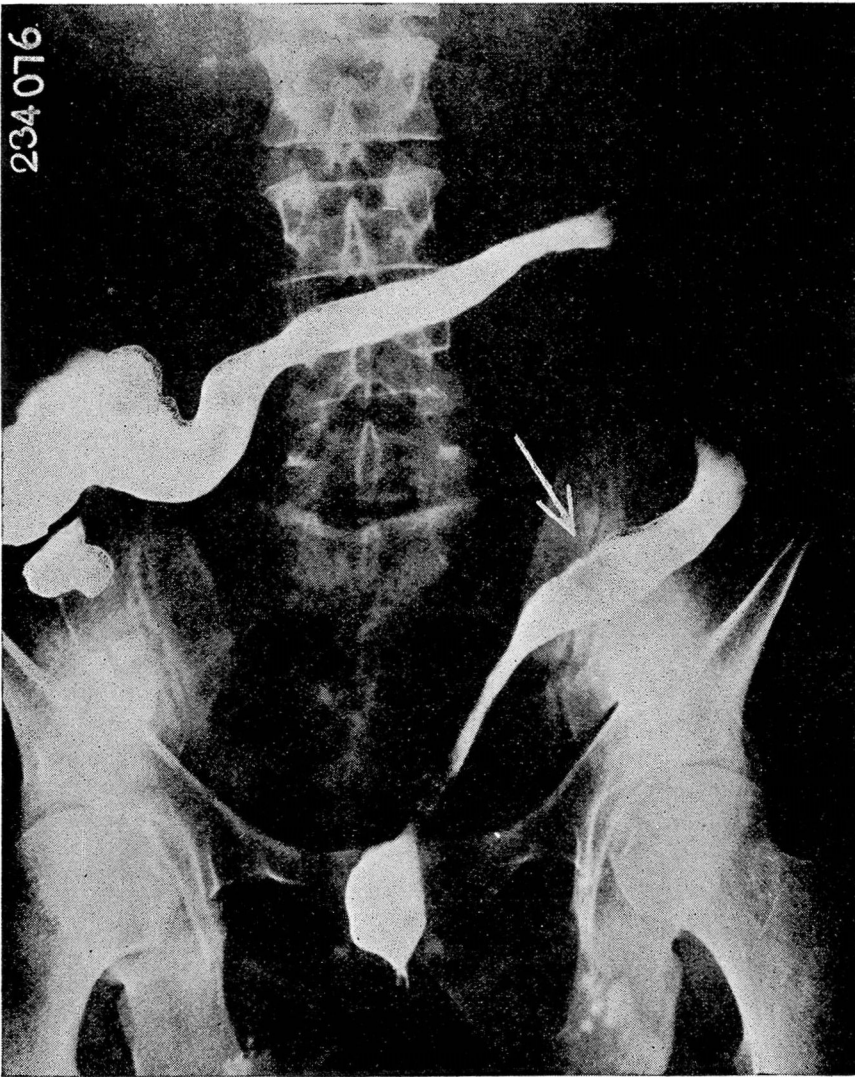


FIGURE 8.—Extensive chronic ulcerative colitis subsequent to ileostomy. Colectomy now being considered because of evidence of polyp formation in sigmoid colon which was not present during former roentgen examinations.

with unusual hypertonicity, spasticity and tenderness in the involved segment. Usually the most extensive involvement is found in the rectum, sigmoid, and lower descending colon, with gradually decreasing involvement as the cecum is approached. When there is diffuse and extensive involvement, not only is the lumen of the colon narrow, but the longitudinal axis of the colon is much shorter than the normal colon. During the fluoroscopic examination, the enema fills the colon instantly

and regurgitation occurs through the ileocecal valve. The colon may be empty by the time a film can be taken. In the involved portions, there will be a lack of haustral markings and the diameter of the lumen will be reduced to that of a narrow tube having irregular borders. Palpation during the fluoroscopic examination will reveal a rigid tender tube having thick walls. Localized chronic ulcerative colitis will present similar findings in the involved segment and may be difficult to differentiate from a neoplasm. In the former, however, a longer segment of the colon is usually involved and there are usually associated spastic phenomena which are absent from the latter.

AMEBIASIS

In our experience, roentgen examination is seldom helpful in the diagnosis of amebiasis, except that it furnishes negative evidence. The diagnosis is usually made by the history, examination of the stools, and the proctoscopic examination. However, Brown⁶ in an analysis of 533 cases, found that only one-third of the patients with active amebic dysentery had grossly visible rectal ulcers, and only one-tenth of the patients infected with *Endamoeba histolytica* had ulcers in the rectum, so that the positive proctoscopic findings, although very important when present, are relatively infrequent. If repeated examinations of the stools are negative and if there has been a long duration of symptoms, the roentgen examination may be helpful. If so, there will be evidence of ulceration in the cecum and ascending colon. The location of the disease, plus negative roentgen findings in the chest, will be highly suggestive of the presence of this disease.

TUBERCULOSIS OF THE INTESTINE

From the roentgen standpoint, the ulcerative type of intestinal tuberculosis produces changes which are characteristic of any type of ulcerating process in the intestine. Roentgen evidence of involvement of the terminal ileum and cecum, the site of predilection, in a young adult who has pulmonary tuberculosis or a primary focus elsewhere in the body, makes the diagnosis of intestinal tuberculosis highly probable. *Roentgen studies of the chest should always be made in cases where there is evidence of an ulcerative process in the right colon, even though the patient has no pulmonary symptoms or physical findings.*

The hyperplastic (tuberculoma) type often presents roentgen evidence which is difficult, if not impossible, to differentiate from a neoplasm. Tuberculoma, of course, usually occurs in younger individuals and its duration will be in terms of years rather than in months. Again the site of predilection is the cecum. Both types of intestinal tuberculosis start in the lymphoid tissue of the submucosa. In the ulcerative type, the process becomes predominantly destructive, while in tuberculoma there

ROENTGEN ASPECTS OF DISEASES OF THE COLON

is a predominant formation of granulation tissue and fibrosis. The luminal contour which the roentgenologist visualizes will be altered accordingly. The new tissue formation in the submucosa in the hyperplastic type will gradually push the mucous membrane into the lumen in folds so that there will be nodular intraluminal projections in the form of papillomatous masses. Meanwhile, the wall of the bowel becomes thickened and stiff so that an irregular boggy mass is palpable during the fluoroscopic examination.

The work of Stierlin (1911) and of Brown and Sampson (1919) in establishing the roentgen diagnosis of ulcerative intestinal tuberculosis is well known. The Stierlin sign, that is the lack of haustral segmentation, the irregular contour of the lumen, associated with hypermotility and marked hyperirritability of the cecum (so irritable that barium, whether given by mouth or enema, may not remain in the cecum long enough for satisfactory visualization), is no longer considered pathognomonic of intestinal tuberculosis. Similar evidence is found in any ulcerating process of the intestine, but may be sufficient for diagnosis in patients who are known to have pulmonary tuberculosis. As is the case in the study of all early lesions of the colon, the barium enema and the combined double contrast method, using either air or gas insufflation after the expulsion of the enema, gives evidence of the earliest anatomic change.

NON-SPECIFIC INFECTIOUS GRANULOMA OF THE INTESTINE

This condition which was established as a clinical entity by Crohn⁷ and which has many clinical names, such as "Regional Ileitis" (Crohn) and "Regional Enteritis" (Brown⁸), is very uncommon in our experience. Jones and Byrne⁹ have reported four of our cases. Crohn and Rosenak¹⁰ have recently reported sixty cases, in nine of which there were simultaneous inflammatory changes in the colon. This experience coincides with that of other observers who have found that the condition, although most frequently found in the terminal ileum, may be primary in any part of the small intestine, and there may be associated lesions in the colon. There has been some discussion as to which is the primary site when lesions are present in both the small and large intestine. The process is different in the two locations. "Primary ileitis is a granulomatous process, thick, hard, eventually with cicatrizing involvement of the ileum, as opposed to the flat, thin, superficial ulceration of colitis with ileac involvement; the latter never goes on to granuloma or to cicatrization or stenosis" (Crohn¹⁰).

The preoperative clinical differentiation is usually impossible. The patient may consult the physician during the early phase of the disease when there are symptoms which simulate recurring appendicitis, even

though the appendix has been removed, or during the ulcerating enteritis phase when the disease simulates chronic ulcerative colitis, or during the third or stenotic phase, when the signs are those of partial or intermittent complete intestinal obstruction. The formation of fistula, either internally to the adjacent colon or other visera, or externally, may be the predominant feature at any stage of the disease. Roentgen examination usually reveals the location of the disease process which, in the absence of positive roentgen chest findings (to exclude tuberculosis) makes this diagnosis highly probable. If the patient is seen during the stenotic phase, a plain film of the abdomen may reveal the approximate site of the obstruction. However, since the ulcerating phase is the one most commonly encountered, the roentgenologist usually makes the barium enema examination first when the symptoms are those of chronic ulcerative colitis. When the disease is limited to the small intestine, the barium enema will show a normal colon, which is very important negative evidence. If the lesion is limited to the terminal ileum, its most frequent site, the regurgitation of the barium enema through the ileocecal valve discloses evidence of ulceration at this site and this is positive evidence. Since the disease in the small intestine is a *slowly* cicatrizing process (the duration of symptoms may be several years), the barium meal usually can be administered without fear of producing complete obstruction. By making interval studies while the barium meal passes through the small intestine, the site of the lesion is usually determined. The roentgen evidence of an inflammatory process is the same whether the lesion is in the small or large intestine, and the evidence revealed depends on the character, severity, and extent of the pathologic changes present at the time of the examination. Mucosal destruction, narrowing as well as shortening of the lumen, mural thickening as determined by palpation during the fluoroscopic examination, together with either hypermotility or evidence of obstruction with dilatation of the intestine proximal to the lesion are the most commonly observed findings. If an external fistula is present, the simultaneous injection of an opaque medium at the time of the other roentgen studies often determines the course and distribution of the fistula. Since resection of the involved segment of small intestine is curative, it is hoped that in the future the condition will be discovered earlier in the course of the disease and that, when operation in the interval between suspected recurring attacks of appendicitis is done, exploration of at least the terminal segments of the ileum will be included.

MEGACOLON

The diagnosis of this condition, either when a diffuse or a localized involvement of the colon is present, is easily established by the roentgen examination, by the use of the barium enema.

ROENTGEN ASPECTS OF DISEASES OF THE COLON

FUNCTIONAL DISTURBANCES OF THE COLON

Functional gastro-intestinal disturbances with colon manifestations are the most frequent cause of chronic gastro-intestinal disability. They may simulate or may be secondary to any diseased state in the abdomen, if not elsewhere in the body. If such disturbances are primarily functional, the duration of the disability is usually longer than that in organic disease, except chronic ulcerative colitis and diverticulosis, but the possible occurrence of an organic lesion in association with the functional element must not be forgotten. Functional disturbances of the colon are most commonly due to improper bowel habits or to a hyper-sensitive nervous system in general, but they may be secondary to diseases elsewhere, such as a pathologic appendix or diseases in the gallbladder or urinary tract. The rôle of gastro-intestinal allergy is assuming increasing importance. There may be several causes for the disability. *Gastro-intestinal diagnosis often involves a process of exclusion.* Therefore, unless the symptoms are definitely localized to the colon, complete roentgen studies as well as other clinical studies are indicated.

As discussed elsewhere¹¹ our routine roentgen studies in these cases are as follows: Films of the gallbladder, kidney and urinary bladder are made first. If any abnormality is revealed in the urinary tract, the patient is then sent to the Genito-Urinary Department for examination. Intravenous urography or retrograde pyelography, if indicated, are done before the barium meal is given. This is followed by cholecystography, combined with a complete study of the gastro-intestinal tract, which includes the barium meal, fluoroscopic and film examinations of the stomach and intestine, as well as the barium enema examination of the colon. Finding an unsuspected organic lesion during a roentgen gastro-intestinal series' examination is not unusual. Therefore, the roentgenologist not only aids in determining the presence or absence of disease, but also determines the physiological activities of the gastro-intestinal tract. Motility studies may show unusual findings. The colon may be unusually irritable, regardless of the presence of unusual atonicity or spasticity. At any rate, probably the most helpful evidence in the localization of the disturbance is (1) the accurate reproduction of the patient's abdominal distress while the barium enema is administered, and (2) the relief experienced after the expulsion of the enema. *Symptoms due to disturbances in the colon may be referred to any part of the abdomen, including the epigastrium,* as demonstrated by Smith¹² and others. If evidence of an organic lesion is questionable, the roentgenologist should not hesitate to request reëxaminations after adequate preparation, just as other reëxaminations may be required in solving other clinical problems.

E. N. COLLINS

REFERENCES

1. Collins, E. N.: Sarcoma of stomach, report of case, *Cleveland Clinic Quart.*, 2:59-62. (April) 1935.
2. Fischer, A. W.: Frühdiagnose des Dickdarmkrebses, insbesondere seine Differentialdiagnose gegen Tuberkulose mit Hilfe der kombinierten Luft und Bariumfüllung des Dickdarms, *Deutsch. ges. f. innere. Med.*, 35:86-87, 1923.
3. Fischer, A. W.: Ueber eine neue röntgenologische Untersuchungsmethode des Dickdarms; Kombination von Kontrasteinlauf und Luftaufblähung, *Klin. Wchnschr.*, 2:1595-1598, 1923.
4. Weber, H. M.: Roentgenologic demonstration of polypoid lesions and polyposis of large intestine, *Am. J. Roentgenol.*, 25:577-589, (May) 1931.
5. Collins, E. N. and Jones, T. E.: Benign stricture of intestine due to irradiation of carcinoma cervix uteri, *Surg. Gynec. & Obst.*, 59:644-649, (October) 1934.
6. Brown, P. W.: Quoted by Rankin, Bagen and Buie, "The Colon, Rectum and Anus," Philadelphia, W. B. Saunders Co., 1932, 294-315.
7. Crohn, B. B., Ginzburg, L. and Oppenheimer, G. D.: Regional ileitis; a pathological and clinical entity, *J.A.M.A.*, 99:1323-1329, (October 15) 1932.
8. Brown, P. W., Bagen, J. A. and Weber, H. M.: Chronic inflammatory lesions of small intestine (regional enteritis) *Am. J. Digest. Dis. & Nutrition*, 1:426-431, (September) 1934.
9. Jones, T. E. and Byrne, R. V.: Chronic nonspecific granulomatous ileitis; report of 4 cases, *S. Clinics North America*, 15:1035-1045, (August) 1935.
10. Crohn, B. B. and Rosenak, B. D.: A combined form of ileitis and colitis, *J. A. M. A.*, 106:1-7, (January 4) 1936.
11. Collins, E. N.: Cholecystography, *Cleveland Clin. Quart.*, 2:16-22, (July) 1935.
12. Smith, Fred M., Paul, W. D. and Fowler, W. M.: Mechanism of the epigastric distress associated with irritable colon and chronic appendicitis, *Arch. Int. Med.*, 47:316-328, (February) 1931.