

THE ROENTGEN RAY TREATMENT OF TUBERCULOSIS OF THE MEDIASTINAL LYMPH NODES

URSUS V. PORTMANN, M.D.

Although roentgen irradiation has come to be recognized as the most satisfactory method of treating tuberculosis of the superficial lymph glands, little attention has been directed to the treatment of the same affection when it involves deeply situated glands, especially those which lie in and about the mediastinum. No doubt this is true because the latter pathological process is more obscure. However, not infrequently the pressure exerted by the inflammatory enlargement of the tracheo-bronchial and bronchial lymph nodes causes symptoms in many cases of tuberculosis at some stage of the disease. We have found that this difficulty may be relieved in selected cases and sometimes—particularly in children—the progress of the disease may apparently be arrested.

It seems that the rôle of the lymphatic glandular system in tuberculosis is not always fully appreciated by some clinicians, especially roentgenologists, because often the earliest signs of tuberculosis which are sought for and recognized by physical examinations or roentgenographic studies are the manifestations of the pathological processes which develop in the parenchyma of the lungs. However, it is often possible to determine with some degree of certainty, the presence of the infection in even earlier stages and possibly before pulmonary lesions have developed, if known facts about the pathogenesis and clinical course of tuberculosis are taken into consideration, and if clinicians are on the alert to interpret correctly the insidious early manifestations of tuberculosis.

It is generally recognized that tuberculosis is frequently contracted by inhalation, sometimes by ingestion, occasionally by inoculation and rarely by direct hereditary transmission of tubercle bacilli. In the vast majority of instances, tuberculosis is contracted during childhood, and the infection may become attenuated or destroyed; it may remain latent for varying periods of time or, under certain circumstances, it may become active and cause more or less severe pathological processes in various tissues of the body according to the number and virulence of the bacilli in relation to the susceptibility or resistive physiological influences of the host.

Numerous and extensive investigations have been made to determine the mode of dissemination of tubercle bacilli from their portal of entry to the tissues in which they may produce characteristic lesions. I do not intend to discuss the mode of dissemination of tubercle bacilli;

THE ROENTGEN RAY TREATMENT OF TUBERCULOSIS

however, in some instances, the organisms may be first taken up by the lymphatic vessels at the site of entry and conveyed immediately to the adjacent lymph nodes where pathologic processes may develop, or they may be carried in the lymph channels to the thoracic duct where they are emptied into the blood stream, pass through the pulmonary and general circulation and eventually are deposited in the end vessels of any tissue of the body. It has been demonstrated by autopsy material that no matter how tubercle bacilli enter the body, the lymph glands in the immediate neighborhood of the portal of entry or contiguous groups of nodes are promptly and primarily affected, although the subjective and objective manifestations of tuberculosis may not appear until some time after the invasion of the organisms, if they appear at all. Also, it is well established by postmortem examinations that few individuals escape infection by the tubercle bacillus and that no matter when or how the organism enters the body, it is the lymph glands in and about the mediastinum that are predominately affected, the intra-abdominal nodes in a large percentage of instances and the superficial groups much less frequently, and but rarely is the disease limited to only one group of glands.

Since tuberculosis is primarily a disease of childhood and of the lymphatic glandular system, and since the glands in and about the mediastinum are predominately affected, it may justifiably be assumed that many individuals have or have had some degree of involvement of the intrathoracic groups of lymph nodes. This is particularly true of children who may have been infected but in whom the disease may not yet have developed in the lungs or other organs. But of course, physical signs or symptoms of tuberculosis do not develop in every individual who becomes infected by tubercle bacilli, especially in the early stages while the disease is still confined to the lymphatic glandular system. However, there are others, who at an early stage of the disease, do have difficulties which may be attributed to mediastinal lymphadenopathy. It is this type of patient who, if the symptoms are correctly interpreted while the disease is still in its early stage, may be relieved of distress, the general condition may be improved and the disease arrested by roentgen therapy as an adjunct to other therapeutic procedures.

There are no pathognomonic signs or symptoms of tuberculous mediastinal lymphadenitis. The diagnosis must be made largely on the basis of the history, symptoms and roentgenographic evidences rather than by physical signs. The most frequent complaints are cough, persistent fever, malaise, poor appetite and loss or no gain in weight. The cough is irritating, nonproductive, spasmodic or even paroxysmal and most distressing at night. It recurs periodically, especially during

winter months or with frequent colds to which infected children are apparently particularly susceptible. The cough may be explained on the basis of inflammatory enlargement of the tracheobronchial and bronchial lymph glands which cause pressure and irritation on the trachea or bronchi. The fact that the cough recurs when colds are contracted is probably due to recurrence of the inflammatory swelling of the nodes because the resistance of the patient is somewhat lowered by the acute illness. The fever which is associated with the cough is seldom extremely high but ranges from only slightly above normal in the morning to about 102° F. or occasionally higher in the afternoon and evening, and it may be accompanied by night sweats. Often there is a definite family history of tuberculosis and such a record should carry considerable weight in making a diagnosis of the disease in children who present the symptoms mentioned. However, occasionally no such history can be obtained and when there is no evidence of possible contact infection, there is often positive reaction to the bovine tuberculin test; therefore, it may be assumed that these patients have contracted the disease by ingestion of bacilli, possibly from milk.

A number of children in whom we have made a diagnosis of tuberculosis of the hilum lymph glands have previously had tonsillectomy performed to relieve their cough and fever. No doubt these individuals had enlarged tonsils concurrent with the more or less generalized lymphadenopathy always associated with tuberculosis, but no relief from the symptoms resulted from the operations. In this connection, we can say that we have seldom, if ever, seen benefit derived from tonsillectomy performed because the cervical lymph nodes were enlarged due to tuberculosis. Even though the tonsils may be considered to be a portal of entry for tubercle bacilli, organisms promptly enter the cervical nodes and then the tonsils are no more a focus of infection than any one of the lymph glands, so that their removal will not halt the progress of the infection. We have observed also that cervical lymphadenitis is only rarely associated with involvement of nodes about the mediastinum. If the disease involves the glands in both these locations simultaneously, it indicates an extensive and generalized involvement of the lymphatic glandular system because disease in the cervical lymph nodes does not extend directly to the mediastinum as is sometimes supposed. This is explained on the basis of the lymph drainage in the neck. The lymphatic drainage from the regions of the upper respiratory tract, including the tonsils, is to the different groups of cervical lymph nodes and then into a jugular trunk which empties into the subclavian vein; therefore, there are no direct lymphatic trunks from the cervical to the mediastinal lymph node groups. Of course, the intrathoracic nodes or other

THE ROENTGEN RAY TREATMENT OF TUBERCULOSIS

tissues of the body may become involved from a focus in the cervical glands, but this must take place indirectly by way of the blood stream.

The physical examinations of the patients on whom we have made a diagnosis of tuberculous mediastinal lymphadenitis have given little information; at least, there have been no significant findings that consistently indicated the presence of enlarged mediastinal lymph nodes except in five adults with large masses of glands. Routine laboratory examinations, including repeated search of the sputum for tubercle bacilli, have likewise given little information. We have considered positive tuberculin reactions to be of diagnostic value and confirmatory evidence of the presence of tuberculosis according to the generally accepted criteria for these tests if both human and bovine tuberculin are employed. As previously suggested, some of our patients reacted to bovine but not to human tuberculin. Tuberculin tests should certainly be made in suspected cases in children; at least in those whose history gives no evidence of possible contact infection.

Although a positive diagnosis of active tuberculosis of the lymph nodes in and about the mediastinum should not be made from roentgenographic studies, we have found that the manifestations which are found are most suggestive in many cases when correlated with the clinical evidences of the disease. The stereoscopic posterior-anterior and lateral films of the lungs which should always be made, show an abnormal amount of hilar infiltration and often calcification out of proportion to the age of the patient. Occasionally enlarged tracheobronchial lymph nodes can be distinctly outlined in the hila, and in other instances there are irregular masses and calcifications of varying size about the hila from which infiltration extends well out into the lung fields. When healing takes place, calcifications increase in number and size, and tiny, pinhead-sized spots of calcified tubercles may be seen distributed in an irregular zone about the hila. The apices are clear in children and there are no evidences of parenchymal tubercles until after dissemination takes place to these regions through the pulmonary blood supply of the lung. When there is more extensive involvement, the mediastinal shadows are considerably widened from the hila upward and may simulate Hodgkin's disease or lymphatic leukemia. This is especially true in adults except that the outline of the nodes is not so irregularly nodular in appearance. As the disease becomes quiescent and healing takes place following treatment, a gradual increase of calcification occurs in the nodes, but if the disease progresses, tubercles may appear in the parenchyma of the lungs.

It has been suggested that in children with lymphadenitis in the hila, the roentgen appearance is that which is sometimes interpreted as a

condition due to allergy. Indeed, a fairly high percentage of our patients with lymphadenitis have been definitely allergic, but there is no reason why an individual may not be allergic and also have tuberculosis; in fact, we have reason to believe that in a great many cases in which the roentgenologic appearance and the symptoms have been explained on the basis of an allergic reaction in the chest, tuberculosis of the tracheobronchial groups of lymph nodes has been present.

We have treated another group of children who were originally referred for nose and throat examinations because it was thought that their symptoms might be caused by disease in the upper respiratory tract; indeed, the interpretation made by roentgenograms of their chests has sometimes been "upper respiratory tract infection." However, the examinations of their noses, sinuses and throats failed to reveal enough evidence of pathology to account for their difficulties. Eventually, these patients were found to have tuberculous tracheobronchial lymphadenitis. Certainly a diagnosis of "upper respiratory tract infection" by roentgen examination of the lungs is precarious in view of the fact that the lymphatic drainage from the upper air passages is not to the lungs or mediastinum. The hilar infiltrations which have been the basis for the roentgen interpretations of "upper respiratory tract infection" often present similar characteristics to what we think may often be tracheobronchial lymphadenitis.

The factors which should suggest the diagnosis of tuberculosis of the lymph glands lying in and about the mediastinum may be summarized as follows:

1. A complaint of chronic or persistent or periodic cough, unexplainable on the basis of acute infectious disease.
2. A persistent fever.
3. A history of contact with a tuberculous individual. In this connection it should be assumed that the lymphatic glandular system is primarily affected in any person who becomes infected with tubercle bacilli and that in such cases, the lymph nodes in and about the mediastinum are predominately affected.
4. Positive tuberculin tests for human or bovine tuberculosis.
5. Roentgenographic evidence of diseased lymph nodes in and about the mediastinum or of hilum tuberculosis.

Of course, it is possible for infections other than tuberculosis to cause lymphadenitis about the mediastinum, as for example whooping cough; however, these other infections are usually acute in onset and clinical course, so that there should be little difficulty in the differential diagnosis. Incidentally, it is not unlikely that the beneficial effects which

THE ROENTGEN RAY TREATMENT OF TUBERCULOSIS

result from the roentgen ray treatment of whooping cough are largely due to the reduction in size of swollen tracheobronchial lymph nodes, the pressure from which is a factor in producing cough.

After a diagnosis of mediastinal tuberculous lymph adenitis has been satisfactorily established, small divided doses of roentgen therapy may be administered *if parenchymal lesions are absent*. We have followed the general plan usually employed for the treatment of tuberculosis of the superficial lymph node groups. Our idea has been to try to reduce the size of the swollen tracheobronchial glands in order to relieve the distressing cough and also slowly to create a reactionary fibrosis and eventual calcification and healing in the affected nodes. We believe that sometimes this procedure may increase the resistance or at least eliminate one focus of infection so that the patient is better able to combat the disease. Although we have tried to avoid treating patients in whom lesions should be demonstrated in the parenchyma of the lungs, apparently in an occasional case unrecognized pulmonary tubercles were present, because after the patients improved and the disease seemingly was arrested, roentgenograms showed miliary spots of calcification in the lung fields in a zone about the hila as well as calcified tracheobronchial nodes.

We have given treatments from every three to seven days, depending upon the severity of the cough and over a period of from two to six weeks. The technical factors employed for children have been 140 K. V. with four to six millimeters of aluminum (A. U. 0.25) and for adults 190 K. V. with one-half millimeter of copper (A. U. 0.16). Sternal and dorsal fields are used with the radiation directed to the mediastinum, which we calculate receives about 150 roentgens at each dose.

The following cases have been selected to illustrate the effectiveness of roentgen therapy for the treatment of tuberculosis of the lymph nodes about the mediastinum.

Case 1: A little girl, five years of age, had been a normal child until acute pyelitis occurred at the age of two years. She recovered from this illness and at the age of four, she had a persistent cough and it was noticed that she had a daily afternoon fever. Her tonsils were removed. The fever and cough persisted, and thorough examinations were made by competent physicians. Studies of her genito-urinary system were made, and the possibility of recurrence of pyelitis was eliminated and a roentgenologist reported that her chest was normal. Cutaneous human tuberculin tests were negative, but later she was found to react to the bovine type. When we saw her, the temperature ranged from 102° to 105°F.; she did not have chills, but drenching night sweats occurred. There was no history of contact with a tuberculous individual. She weighed 42 pounds and had weighed about the same a year previously. There were no significant physical or laboratory findings. Wassermann and repeated tests for

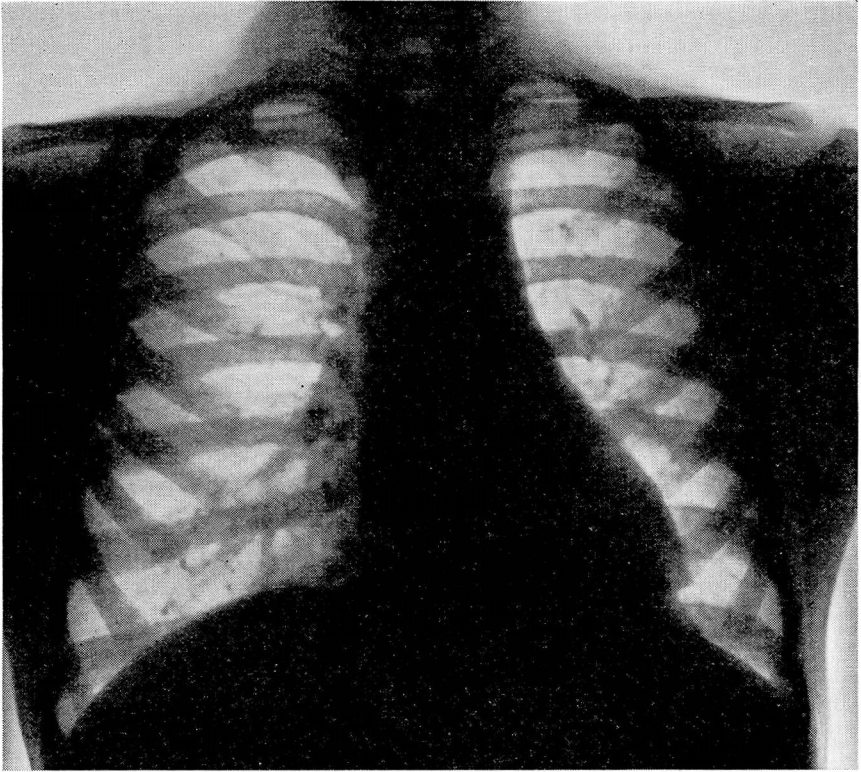


FIG. 1.—CASE 1: Tuberculosis of the tracheobronchial or hilum lymph glands in a child.

undulant fever were negative, and the bovine tuberculin test was moderately positive. Roentgenographic studies of the chest (Fig. 1) revealed that the right hilum lymph nodes were definitely enlarged and an unusual amount of calcification was present. Finally, a diagnosis of hilum tuberculosis was made and the child was given bed rest, cod-liver oil and a high vitamin diet for a month, but the cough and fever persisted. Roentgen therapy was administered in small doses every second day for four times and a second course was given two weeks later. Her fever became less after the second treatment and disappeared in thirteen days; it never was higher than 100° per rectum during the next two months and she gained weight rapidly. The cough also had been eliminated and did not return during our course of observation which, unfortunately, lasted only eight months.

Case 2: This boy was first seen at the age of four years, when he was referred to the Clinic for tonsillectomy. The history revealed that he had had frequent sore throats, a poor appetite, that he fatigued easily and that he had not gained in weight since an attack of whooping cough six months previously. His mother had once had pulmonary tuberculosis and his father suffered from tuberculous iritis. Roentgenograms made prior to operation gave positive evidence of fibrous and calcific infiltration in the right hilum with apparent enlargement of the lymph nodes, so that a roentgen diagnosis of purile tuberculosis was

THE ROENTGEN RAY TREATMENT OF TUBERCULOSIS

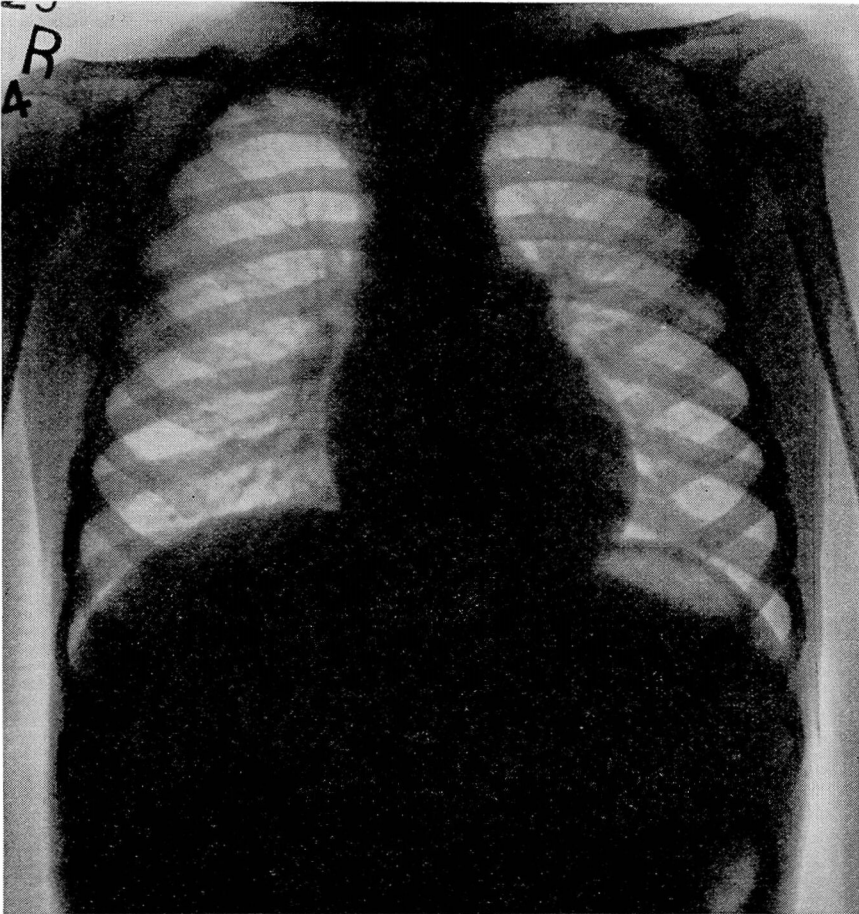


FIG. 2—CASE 2: Tuberculosis of the tracheobronchial or hilum lymph glands. Condition considered to be due to upper respiratory tract infection from tonsils.

made. But the physical and other examinations revealed no evidence of active disease, though he reacted positively to human tuberculin. Tonsillectomy was performed and following this, the temperature remained normal during three days' observation. However, rest in bed and general protective measures were advised and religiously carried out. When the patient was seen one year later, he had made no progress. He had not gained in weight, he was easily fatigued, he often had a temperature of 101.5°F., and sometimes he had night sweats and a cough. On examination, there were no significant physical findings except that the cervical lymph glands were palpably enlarged. Roentgenographic studies (Fig. 2) showed the same condition that had been described previously. At this time, there was satisfactory evidence of active tuberculosis of the tracheobronchial glands and, following the first treatment, a sharp febrile reaction (104°F.) took place, but the temperature promptly subsided in twenty-four hours, and during the next week was lower than at any time during the previous two weeks. The cough and night sweats disappeared entirely after the second

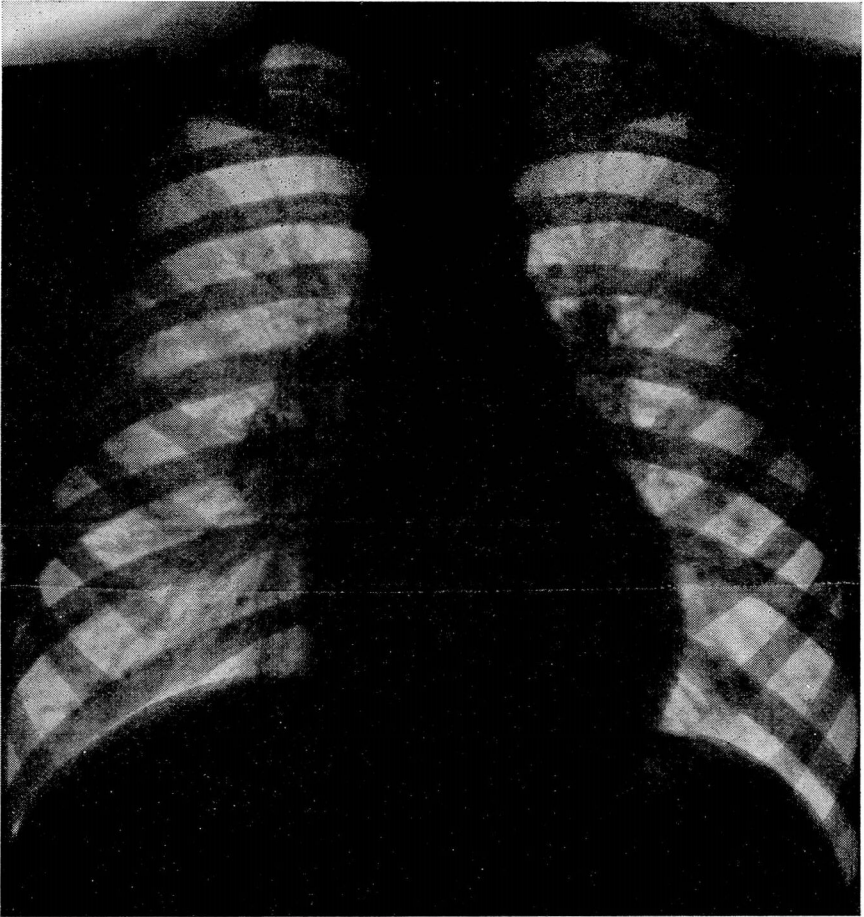


FIG. 3—CASE 2: Calcification of tuberculous tracheobronchial lymph nodes in the same patient after roentgen ray treatment. The condition is arrested or healed six years later.

treatment and his gain in weight was twelve pounds in six months. During the next year, he had one or two attacks of coughing associated with colds, and his parents promptly brought him in for treatment which was followed by relief. For three years, this patient has been without evidence of active disease and roentgenograms of his chest (Fig. 3) taken recently show calcified lymph nodes about the hilum of each lung.

Case 3: A girl of seven years was brought in because she had had periodic, severe attacks of paroxysmal, unproductive cough for the past four years. She had never had any other illness. Her grandfather is a physician, and therefore she had had numerous, complete medical examinations. There was no definite history of tuberculosis in the family. Her coughing attacks always came during the winter months, beginning in November. Each attack would last for several hours, usually coming on at night and persisting for four or five days, and they recurred about every three or four weeks. The temperature had never been

THE ROENTGEN RAY TREATMENT OF TUBERCULOSIS

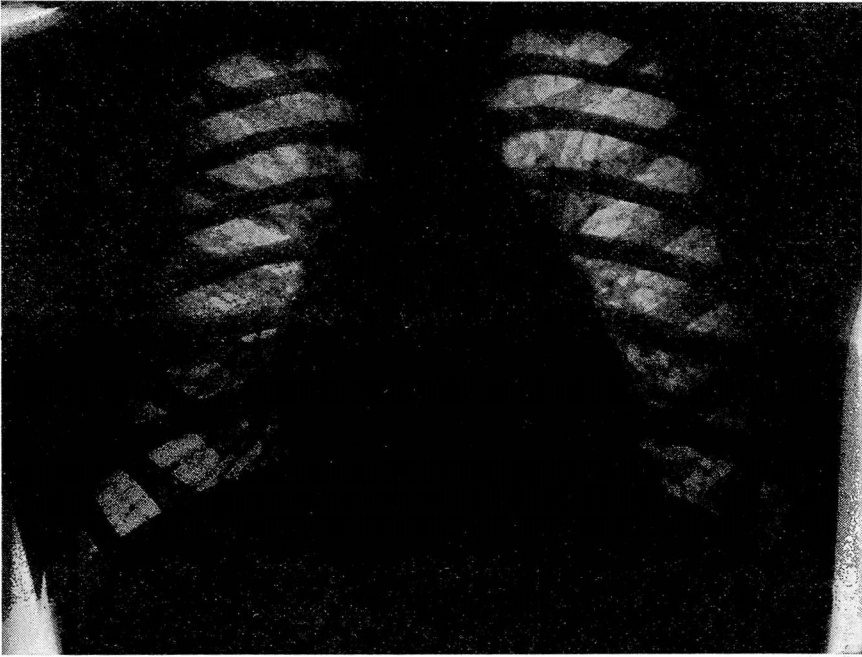


FIG. 4—CASE 3: Tuberculous tracheobronchial lymphadenitis that had been considered a condition due to allergy.

very high, but some fever always accompanied the attacks. Numerous tests had been made in an effort to explain her condition on an allergic basis, but without avail. She was referred to us because it was thought that she had sinus infections but this was not corroborated by our examination. The child was definitely undernourished, but complete physical and laboratory examinations gave no explanation for the condition. Bovine tuberculin tests were moderately positive. Roentgenographic studies of her chest (Fig. 4) showed some enlargement of the tracheobronchial groups of lymph nodes, and on this basis a diagnosis of tracheobronchial lymphadenitis was entertained. Roentgen therapy was administered at the beginning of her next cycle of coughing, and this attack was promptly aborted. Treatments were continued each week for three times and the winter passed without another attack of coughing or fever. The following winter, the child caught cold and began to cough, but a treatment the next day relieved her and the parents felt that another attack had been prevented. During the past three years, she has been entirely free from fever or cough and is developing satisfactorily without evidence of tuberculosis.

Case 4: A woman, 25 years of age, was first seen in 1930 and gave the history that her mother, father and sister had died from pulmonary tuberculosis. She had always had indifferent health and was known to be extremely allergic to several proteins. In 1928, a persistent fever developed, but many examinations by competent physicians gave no definite explanation for it, though tuberculosis was suspected. She gradually improved, but about one year later, she contracted a cold which was followed by a persistent nonproductive cough and fever. **More examinations were made, and she was told that she did not have**

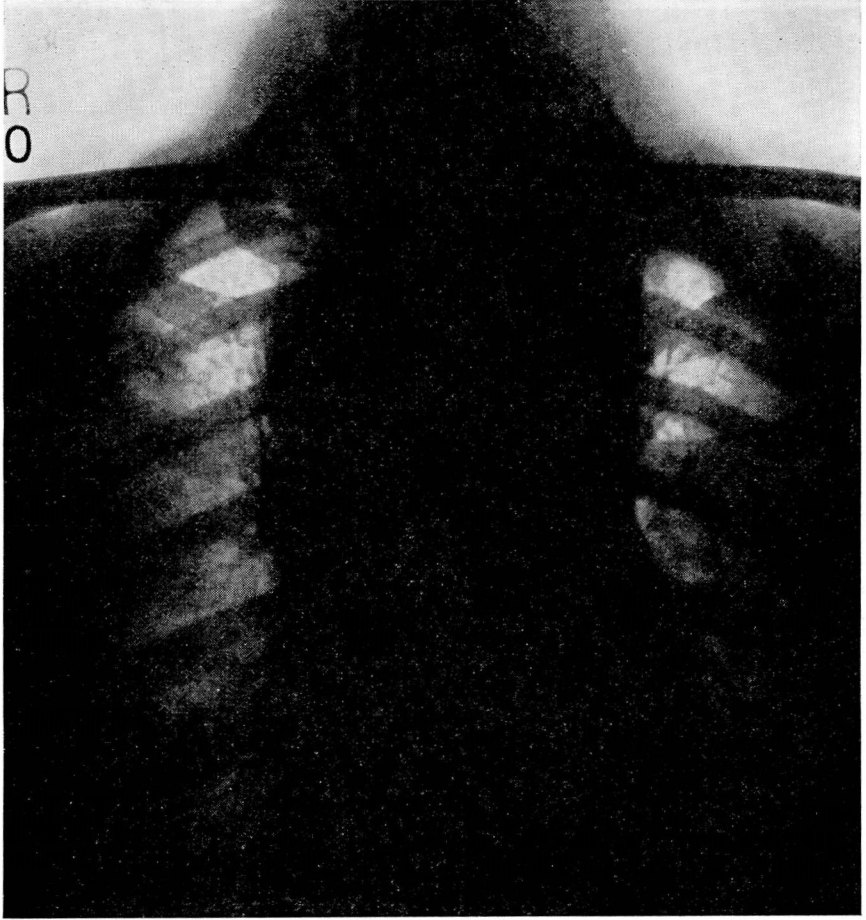


FIG. 5—CASE 4: Tuberculosis of the mediastinal lymph nodes in an adult. Simulates Hodgkin's disease or lymphatic leukemia. Before roentgen therapy in 1930.

tuberculosis. After she recovered from this attack of illness, she was married and soon became pregnant. The fever and cough returned, and tubercle bacilli were said to have been found in her sputum. A therapeutic abortion was performed and she entered a sanitarium. While there, she had several attacks of profuse menorrhagia but the condition gradually improved, the cough disappeared and she gained eleven pounds in weight. At this time, the cervical lymph nodes began to enlarge. Although her general health remained good for some weeks, she occasionally had fever and cough, and the cervical glands were often painful and they gradually enlarged. A roentgenogram of the chest which was made at this time showed a mediastinal mass and the possibility of Hodgkin's disease was suggested. A course of deep x-ray therapy was begun but after the first dose she became sick, she was nauseated, her fever rose and she was dyspneic, so the treatment was discontinued. We first saw her a few weeks later. There was no clinical evidence of parenchymal tuberculosis, but physical signs of a mediastinal mass were present. There were very large,

THE ROENTGEN RAY TREATMENT OF TUBERCULOSIS

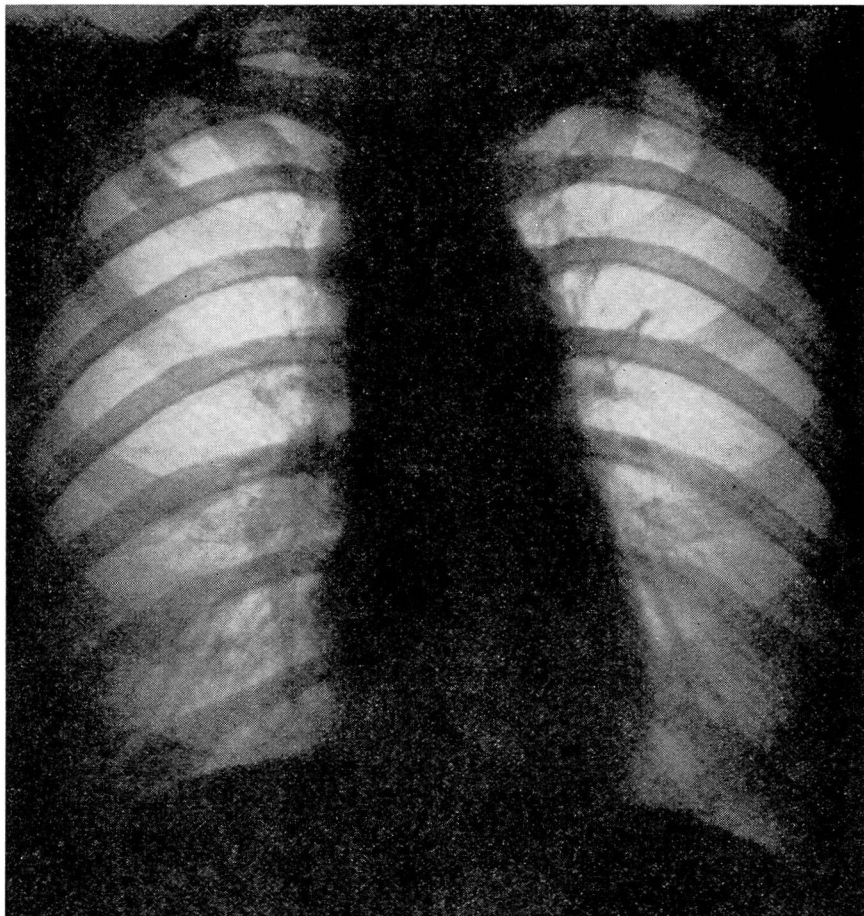


FIG. 6—CASE 4: Same patient four years after roentgen therapy and now without evidence of the disease.

nodular, coalescent masses of glands in both sides of the neck. Several examinations of the sputum showed no tubercle bacilli. Roentgenographic studies (Fig. 5) showed a large confluent mass in the mediastinum and about the roots of both lungs without evidence of parenchymal pulmonary disease. The temperature was about 102°F. at all times and a cough was present. A cervical node was excised and proved by microscopic examination to be tuberculous. Roentgen therapy was administered to the cervical and mediastinal areas in very small doses over a period of three weeks. The enlarged nodes were reduced in size, though drainage continued from the biopsy wound. The temperature returned to normal and the cough disappeared. She was returned home and continued roentgen therapy under Dr. J. F. McCullough of Pittsburgh. Within a few months, the drainage from her wound had ceased and the lymphadenopathy had practically disappeared as did any other evidence of tuberculosis, and she gained twenty pounds in weight. Although she has been very well for five years and recent roentgenograms of her chest (Fig. 6) show no evidence of

URSUS V. PORTMANN

disease, we do not believe she is completely cured, although she derived unquestionable benefit from her treatment.

CONCLUSIONS

Tuberculosis of the lymph nodes about the mediastinum should be suspected, especially in children who have persistent fever and cough. If the diagnosis of this condition can be made before parenchymal lung lesions develop, the disease is probably in a comparatively early stage and roentgen therapy will often relieve the symptoms and be a valuable adjunct to other therapeutic procedures in arresting the disease.