

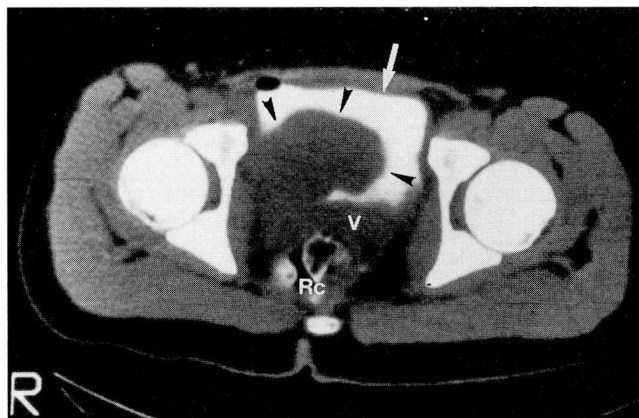
MOULAY A. MEZIANE, MD, EDITOR

## Headache and hypertension in a 15-year-old

RONALD J. LORIG, MD, PhD; KATHLEEN GLEASON BEAVIS, MD; EMMANUEL L. BRAVO, MD; ROBERT KAY, MD

**A** 15-YEAR-OLD girl presented to her physician for a routine physical examination required for cheerleading. She was doing well at the time, despite a history of throbbing occipital headaches since age 11. The headaches were accompanied by diaphoresis and sweating. At the time of the original complaint of headache, no significant workup was pursued.

On examination, the patient was found to be markedly hypertensive, with typical blood pressure of 180/140 mm Hg. Atenolol was prescribed, and she was sent home. Approximately 5 weeks later, she was admitted to her local hospital with severe hypertension. She reported symptoms of headache, sometimes related to mental or physical stress, and headache with occasional sweating and palpitations while voiding. Laboratory evaluation was normal, with the exception of a serum cholesterol of 248 mg/dL. While her electrocardiogram was normal, several premature atrial contractions were noted on the monitor. Her blood pressure fluctuated, and several antihypertensive medications were administered, including captopril, clonidine, and nitroprusside sodium drip. There was no family history of hypertension, renal disease, diabetes, or cardiac disease. Magnetic resonance imaging (MRI) of the abdomen performed at her local imaging center was negative, as was a computed tomography (CT) scan of the thorax. A CT scan of the pelvis (*Figure 1*) revealed the presence of a lobulated soft tissue mass



**Figure 1.** Axial CT scan through the pelvis at the level of the femoral heads. Contrast has been introduced into the bladder fluid (white arrow) via Foley catheter, allowing thorough opacification (white) of the bladder. Mass (black arrowheads) appears to arise from the right posterolateral margin of the bladder and to project into bladder lumen. Contrast has been placed in the rectum (Rc). V= vagina.

reported to be projecting within the bladder lumen. The mass was contiguous with the posterior and posterolateral aspects of the urinary bladder on the right. Pelvic ultrasound confirmed a mass in the right floor of the bladder. A clinical diagnosis of pheochromocytoma was proposed.

On transfer of the patient to the Cleveland Clinic, plasma norepinephrine measured 16,560 ng/L (normal 34 to 412 ng/L), and plasma epinephrine measured 40 ng/L (normal 15 to 78 ng/L). Urine metanephrine was 6.6 mg/24 hrs (normal 0 to 1.0 mg/24 h) and vanillylmandelic acid (VMA) was 45 mg/24 h (normal 0.6 to 2.0 mg/24 h).

From the departments of Diagnostic Radiology (R.J.L.), Pathology (K.G.B.), Heart and Hypertension Research (E.L.B.), and Urology (R.K.).

Address reprint requests to R.J.L., Department of Diagnostic Radiology, The Cleveland Clinic Foundation, One Clinic Center, 9500 Euclid Avenue, Cleveland, OH 44195.

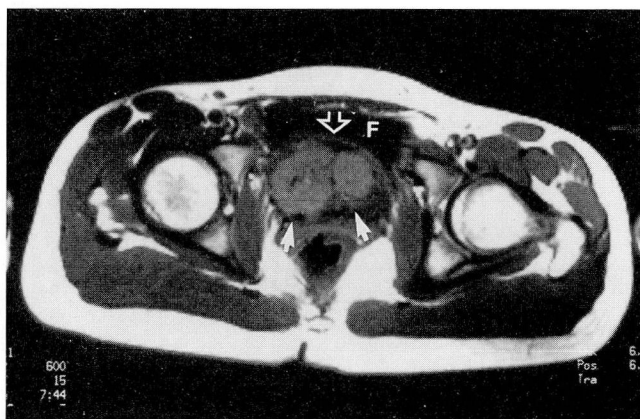


Figure 2. Axial T1-weighted (TR 400 msec, TE 15 msec) MR image corresponding to level through mass on CT (Figure 1). Fluid (F) in bladder is black. The mass (white arrows) is lobulated and displaces the bladder wall (open arrow), represented as a uniformly thin band anterior to mass.

Due to the limited definition provided on the CT and ultrasound, MRI of the pelvis (Figures 2–4) was performed; the MRI results significantly clarified the location of the tumor. Rather than having its epicenter within the bladder, the mass was noted to lie outside of the bladder, anterior to the bladder neck and inferior to the floor of the bladder, immediately adjacent to the symphysis pubis. No intravesical component could be identified, although involvement of the bladder wall remained a possibility. The mass extended slightly to the right.

An operative procedure was performed. A 5.8 x 4.7 x 4.0 cm encapsulated mass weighing 46.5 grams was received for frozen section examination. The mass consisted of gray-brown, firm tissue with multiple cystic areas up to 0.2 cm in diameter. A diagnostic procedure was performed.

---

#### DIAGNOSIS: BLADDER PARAGANGLIOMA

---

The mass removed at surgery was arising from the bladder neck. A 1.3 x 0.5 x 0.3 cm partial cystectomy revealed no evidence of malignant cells. The tumor was entirely excised, and the patient is doing well postoperatively, with a blood pressure of 120/74 mm Hg, a normal heart rate, and no evidence of incontinence.

---

#### DISCUSSION

---

Paragangliomas are tumors of the paraganglion system and are subclassified according to the anatomic site

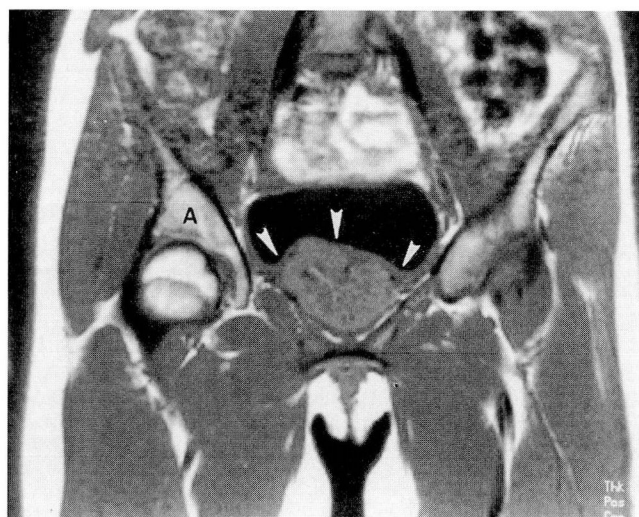


Figure 3. Coronal T1-weighted (TR 400 msec, TE 15 msec) MR image. The mass displaces the bladder wall (arrows) superiorly (A = acetabulum).

of origin (eg, branchiomeric, intravagal, aorticosympathetic, and visceral-autonomic). These tumors can be further subclassified as functional or nonfunctional; all paraganglia, including the chemoreceptors, contain catecholamines in dense-cored granules of the chief cells.<sup>1</sup> The term “paraganglioma” is generally preferred over the terms “chemodectoma” and “extra-adrenal pheochromocytoma.”<sup>1,2</sup> Although the tumors can arise in any of the paraganglia, the organ of Zuckerkandl (near the bifurcation of the aorta) is the most common site, followed by the pre-aortic region near the kidneys and the wall of the urinary bladder.<sup>3</sup>

The characteristic laboratory findings of abdominal paraganglioma include hypersecretion of catecholamines or their metabolites, metanephrine and VMA. The concentrations of these compounds drop dramatically following removal of the tumor. This patient’s plasma norepinephrine level decreased from 16,061 ng/L just prior to surgery to 1,539 ng/L on the day after surgery. Five weeks postoperatively, plasma norepinephrine was still slightly elevated, but had fallen to 616 ng/L.

The presence or absence of the brown chromaffin reaction in paragangliomas is often mentioned. A positive reaction depends on the oxidation of catecholamines and indole amines by chromic acid-producing brown polymers with incorporated chromium salts. Although a positive reaction in the gross specimen is highly specific for the presence of

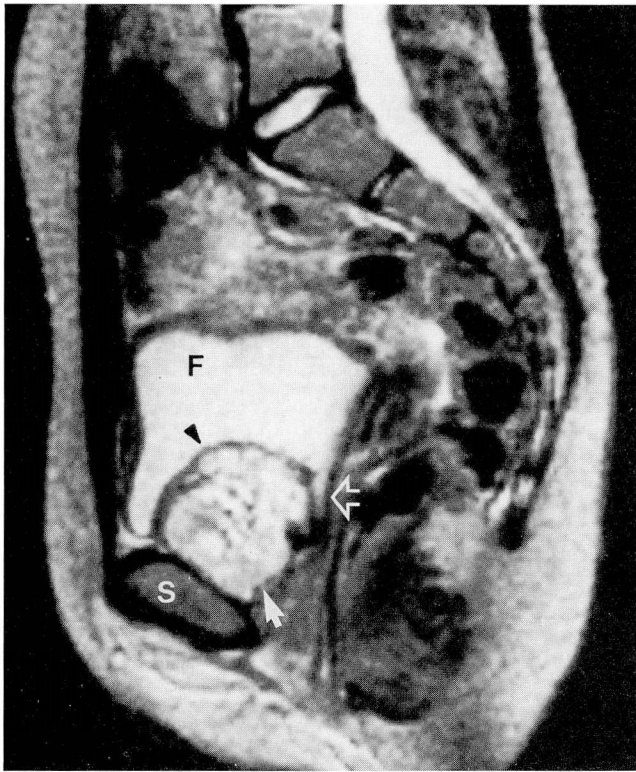


Figure 4. Sagittal T2-weighted (TR 2000 msec, TE 90 msec) MR image of the pelvis, through the center of the mass. Fluid in the bladder is visible (F). No contrast has been given. The mass (white arrow) is inferior to the bladder, closely applied to the symphysis pubis (S). The bladder wall (black arrowhead) is seen as a thin dark line lifted by the mass. A portion of the bladder neck (open arrow) is seen posterior to mass. The mass does not appear to enter the lumen of the bladder. The bright signal intensity of the mass is nonspecific, although consistent with pheochromocytoma.

catecholamines or indole amines, the chromaffin reaction is absent in most branchiomeric or intravagal paragangliomas and can even be absent in functional pheochromocytomas and abdominal paragangliomas.<sup>1</sup> The typical microscopic appearance is of cell balls (Zellballen) or nests of tumor cells separated by delicate fibrovascular septa (Figure 5). The cells can also be present in sheet-like and trabecular patterns. A reticulin stain outlines the alveolar pattern of the stroma; the Grimelius silver reaction highlights the electron-dense cytoplasmic granules.<sup>1</sup>

In addition to the use of special stains, electron microscopy can be valuable in identifying these tumors. The tumor cells, like the cells of the normal adrenal medulla, contain spherical membrane-bound secretory granules scattered throughout the

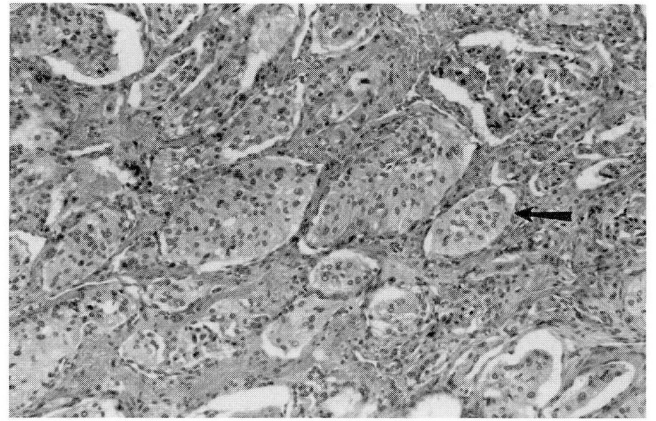


Figure 5. Photomicrograph illustrating the characteristic cell nests (arrow) surrounded by fibrovascular stroma (hematoxylin-eosin,  $\times 31$ ).

cytoplasm. These can be identified on electron microscopy (Figure 6).

The criterion for malignancy of a paraganglioma or pheochromocytoma is metastasis to a location ordinarily lacking chromaffin tissue; mitotic figures, venous and capsular invasion, and cellular and nuclear pleomorphism do not predict malignancy. The recurrence rate (10% to 50%) varies with the original location; approximately 10% metastasize widely and cause death.<sup>2</sup>

The first report of a bladder pheochromocytoma was made in 1953 by Zimmerman et al.<sup>4</sup> In the 38 years since then, only about 100 additional cases have been reported in the literature. The incidence is less than 0.06% of all bladder neoplasms. Occurrence in females is slightly greater than males, with a ratio of approximately 3:2. In a review of 100 published cases,<sup>5</sup> the mean age was 41 years with a range of 11 to 78 years, with a slightly higher incidence in the second decade of life. Masses ranged in size from 0.2 to 10 cm, with a mean of 2 cm. Most were solitary; however, other neoplasms can be associated, such as renal cell carcinoma and transitional cell carcinoma of the bladder.

Approximately 10% to 20% of pheochromocytomas are extra-adrenal. Radiographically, they are nonspecific in appearance; however, their bright signal characteristics on T2-weighted MRI make this modality extremely useful in locating paragangliomas and confirming the presence of an adrenal pheochromocytoma. In this case, MRI provided significantly more information due to its unique cross-sectional imaging and high soft-tissue contrast-rendering capabilities.

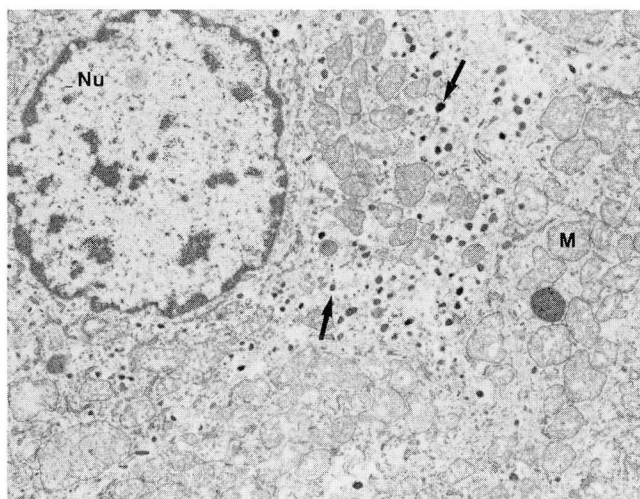


Figure 6. Electron micrograph illustrating the small, spherical, dense membrane-bound vesicles (arrows) containing catecholamines (Nu = nucleus, M = mitochondrion) (uranyl acetate, lead citrate,  $\times 13,000$ ).

Other imaging modalities have been valuable adjuncts to the complete evaluation of extra-adrenal pheochromocytoma. These include CT and radionuclide MIBG (iodine 131 meta-iodobenzylguanidine) evaluations.

Prior to the availability of MRI, the evaluation of vesicular pheochromocytoma included cystoscopy, urography, and, later, CT and ultrasound. Cystoscopy can be associated with a high risk of procedural hypertensive crisis, and has to be performed under strict hemodynamic control. While it identifies the intravesical component of a mass, any portion of the mass extending out of the bladder requires additional evaluation. Findings on cystoscopy include a mass beneath bladder epithelium, possibly associated with bleeding vessels.<sup>6</sup>

Cross-sectional CT imaging, which has been the mainstay of screening and pre-surgical evaluations in the last 20 years, is still an excellent modality for screening. It is limited to presentation of images in the axial plane and can suffer from volume-averaging effects. Because many masses are the same intensity as adjacent tissues on CT examination, it can be difficult to separate mass from normal structure and to fully evaluate tumor extension. However, CT can provide an assessment of the remainder of the abdomen and pelvis in a search for multifocal involvement.

MIBG labelled with iodine 131 provides a functional examination, as the compound is taken up by

adrenergic tissue. While MIBG yields less anatomic detail than CT or MRI, once the biochemical evidence supports the presence of a pheochromocytoma, it can be effective in localizing chromaffin masses. False positives occur, as MIBG can be taken up by medullary carcinoma of the thyroid and malignant carcinoid, which can coexist with pheochromocytoma. Its uptake can be inhibited by various drugs, including tricyclic antidepressants, cocaine, and labetalol, a combined alpha- and beta-adrenergic blocker which may be used in the treatment of pheochromocytoma.<sup>7</sup>

An additional problem of MIBG in the detection of bladder pheochromocytoma is the excretion of the radionuclide in urine, possibly masking the presence of the mass. Dilution of the urine and catheterization with full evacuation of urine during scanning may be necessary. Shapiro<sup>8</sup> reported a 10% false-negative rate in 400 cases of pheochromocytoma evaluated by MIBG. MIBG is expensive and requires several scans over 2 or 3 days. Localization may be poor, and because of this, injection of a second radionuclide such as technetium may be required to provide anatomic references. With classical symptoms of bladder pheochromocytoma, MIBG may only be indicated to confirm the presence of a single lesion.

MRI offers several advantages, despite a slightly higher cost than CT. The cost may be less than MIBG, although, if multiple sites are scanned, this may have less validity. Heyman<sup>6</sup> reported the value of MRI in a case similar to that presented here. The consistently high signal of pheochromocytoma on T2-weighted images allows their detection, even when relatively small. It also enables ready determination of tumor extent against a background of considerably lower signal intensity. In many cases it may be superior in surgical planning, because of the multiplanar imaging; sagittal and coronal views can help to separate tumor from adjacent structures, which, as in this case, may result in significantly less morbidity. In the bladder, natural contrast is exploited by the presence of intraluminal fluid; no injection or catheterization is required. MRI does not require exposure to ionizing radiation, a particular advantage for children and pregnant women.

Biochemical testing remains the method of choice in the initial evaluation of hypertensive patients with headache, palpitations, diaphoresis, and flushing. Exacerbation of symptoms on voiding is classical for localization to the bladder. No patient should undergo imaging studies prior to biochemical proof. However, once the diagnosis of pheochromocytoma has been

made biochemically, localization should commence. A combination of imaging procedures may be necessary for full evaluation, as each is complementary. When bladder pheochromocytoma is suspected, MRI is highly effective in yielding an understanding of location, size, and associated involvement of the mass.

---

#### REFERENCES

1. Glenner GG, Grimley PM. Tumors of the extra-adrenal paraganglion system (including chemoreceptors). Washington, D.C.: Armed Forces Institute of Pathology, 1974.
2. Cotran RS, Kumar V, Robbins SL. Robbins' pathologic basis of disease. Philadelphia: W.B. Saunders Company, 1989:1267.
3. Warner NE, Strauss FH. The adrenal. In: Silverberg SG, ed. Principles and practice of surgical pathology. New York: John Wiley & Sons, 1983:1477-1478.
4. Zimmerman IJ, Biron RE, McMahon HE. Pheochromocytoma of the urinary bladder. *N Engl J Med* 1953; **249**:25.
5. Das S, Bulusu NV, Lowe P. Primary vesicle pheochromocytoma. *Urology* 1983; **21**(1):20-25.
6. Velchik M, Alavi A, Kressel H, Engleman K. Localization of pheochromocytoma: MIBG, CT, and MRI correlation. *J Nucl Med* 1989; **30**(3):328-336.
7. Lenders JWM, Sluiter HE, Rosenbusch, Thien TH. A pheochromocytoma of the urinary bladder. *Eur J Radiol* 1987; **7**:274-275.
8. Warshawsky R, Bow SN, Walbaum RS, Cintron J. Bladder pheochromocytoma with MR correlation. *J Comp Assist Tomogr* 1989; **13**(4):714-716.
9. Heyman J, Cheung Y, Ghali V, Leiter E. Bladder pheochromocytoma: evaluation with magnetic resonance imaging. *J Urol* 1989; **141**:1424-1426.

---

#### ACKNOWLEDGMENT

The authors wish to thank Howard S. Levin, MD, for his help with the pathology discussion; James T. McMahan, PhD, for his assistance with the interpretation of the electron micrograph; Rad Clark, for the preparation of the electron micrograph; and Linda Jones, for assistance in the preparation of the manuscript.

