



The Clinical Picture

A 56-year-old man with palpitations

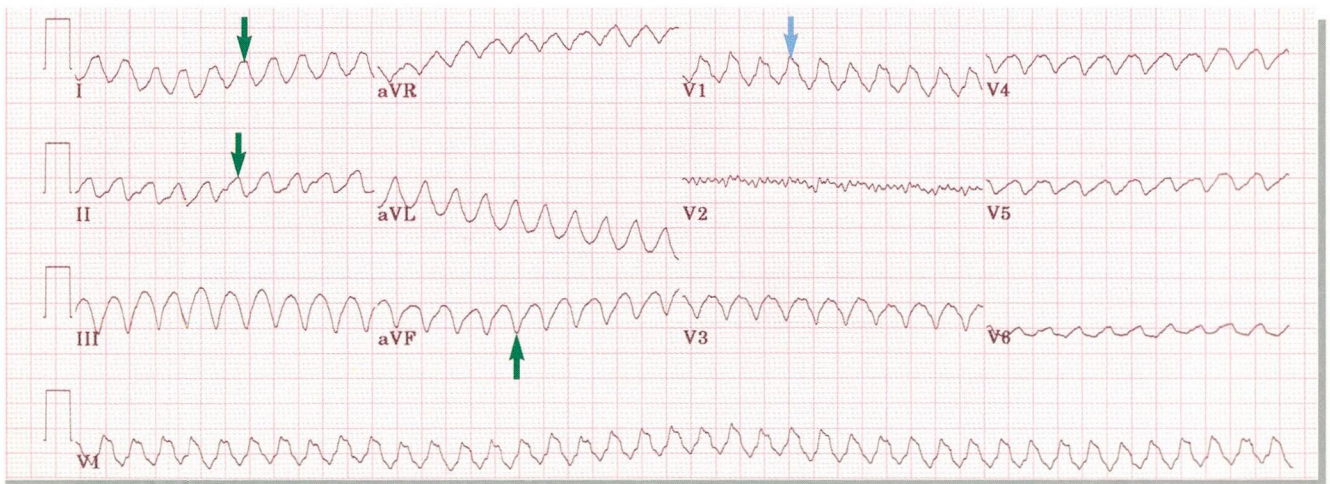


FIGURE 1

Q: A 56 YEAR-OLD MAN presented to the emergency department with palpitations, chest heaviness, light-headedness, and profound fatigue, which began abruptly 1 hour previously. He had suffered a myocardial infarction 3 years previously. A recent echocardiogram demonstrated a large myocardial infarction in the territory of the left anterior descending coronary artery, with an apical left ventricular aneurysm. FIGURE 1 shows his electrocardiogram (ECG) on presentation.

All of the following are true except which one?

- This patient's cardiac dysrhythmia is most likely related to preexisting coronary artery disease
- He has supraventricular tachycardia with aberrant conduction
- He needs urgent sedation and electrical cardioversion
- This clinical scenario is consistent with systemic hypotension and cerebral hypoperfusion.

A: The patient does not have supraventricular tachycardia with aberrant conduction. He does

have known coronary artery disease and a prior myocardial infarction and presents with symptomatic palpitations, symptoms of cerebral and peripheral hypoperfusion, and a wide-complex tachycardia. In ischemic heart disease, a wide-complex tachycardia most likely reflects ventricular tachycardia. Findings on this ECG that support the diagnosis of ventricular tachycardia include:

- A prolonged QRS complex interval of 170 ms
- A monophasic R wave in lead V₁ (blue arrow)
- Frontal plane left-axis QRS complex deviation, including a positive QRS complex vector in lead I, an isoelectric QRS complex vector in lead II, and a negative QRS complex vector in lead aVF (green arrows).

Other findings indicative of ventricular tachycardia (not seen in this case) include sinus capture complexes, fusion complexes, and atrioventricular dissociation.

Given this patient's symptoms on presentation, he should have sedation and synchronized electrical cardioversion as part of his acute management. Once normal sinus rhythm is restored, further evaluation is appropriate, including an assessment for inducible myocardial ischemia and a complete electrophysiologic evaluation. If no myocardial ischemia is found, an implantable cardiac defibrillator is most likely warranted.

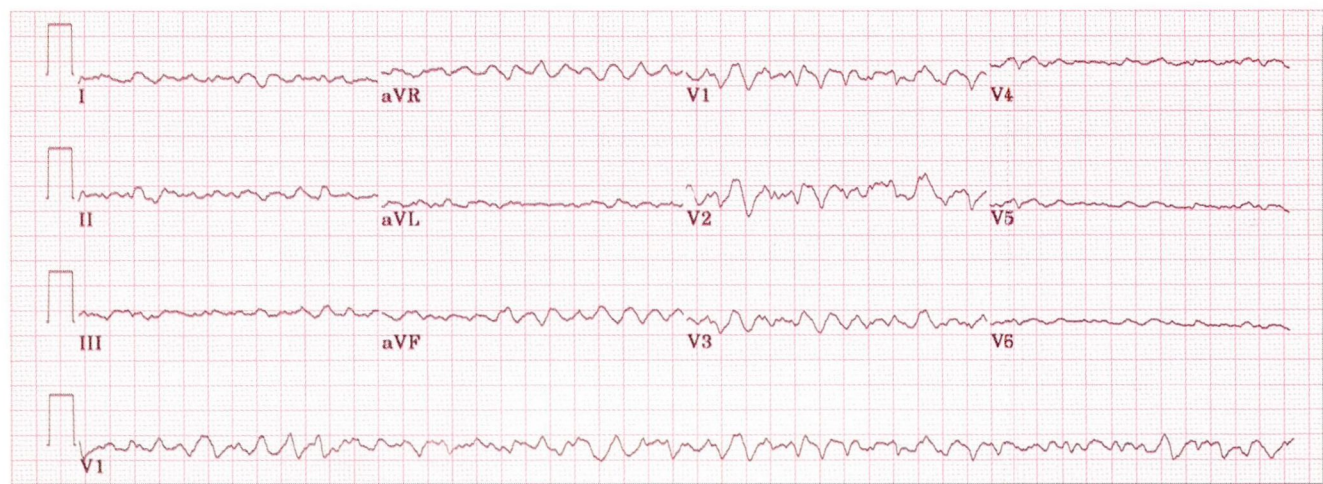


FIGURE 2

Q: The patient successfully underwent urgent cardioversion to normal sinus rhythm. However, he continued to experience recurrent ventricular tachycardia that was refractory to intravenous amiodarone. Further, he developed congestive heart failure and cardiogenic shock, necessitating placement of an intra-aortic balloon pump and a left ventricular assist device. His condition clinically improved and stabilized with the device; **FIGURE 2** is an ECG obtained during this period.

The best course of action would include which of the following?

- Intravenous amiodarone
- Urgent cardioversion
- Cardiopulmonary resuscitation
- Observation

A: This ECG demonstrates ventricular fibrillation, usually a rapidly fatal arrhythmia requiring urgent cardioversion and cardiopulmonary resuscitation. However, in this unusual case, the patient was awake and alert and needed only observation, as the left-ventricular assist device maintained the heart's pumping ability. Shortly thereafter a cardiac transplantation was performed successfully.

■ **SUGGESTED READING**

Brugada P, Brugada J, Mont L, Smeets J, Andries EW. A new approach to the differential diagnosis of irregular tachycardia with a wide QRS complex. *Circulation* 1991; 83:1649-1659.

McCarthy PM, Sabik JF. Implantable circulatory support devices as a bridge to heart transplantation. *Semin Thorac Cardiovasc Surg* 1994; 6:174-180.

Wellens HJJ, Bar FWHM, Lie KI. The value of the electrocardiogram in the differential diagnosis of a tachycardia with a widened QRS complex. *Am J Med* 1978; 64:27-33.

ADDRESS: Curtis M. Rimmerman, MD, Department of Cardiology, F15, The Cleveland Clinic Foundation, 9500 Euclid Avenue, Cleveland, OH 44195, e-mail rimmerc@ccf.org.

We Welcome Your Letters

WE ENCOURAGE YOU TO WRITE, either to respond to an article published in the *Journal* or to address a clinical issue of importance to you. You may submit letters by mail, fax, or e-mail.

MAILING ADDRESS

Letters to the Editor
Cleveland Clinic Journal of Medicine
 9500 Euclid Ave., NA32
 Cleveland, OH 44195
FAX 216.444.9385
E-MAIL ccjm@ccf.org

Please be sure to include your full address, phone number, fax number, and e-mail address. Please write concisely, as space is limited. Letters may be edited for style and length. We cannot return materials sent. Submission of a letter constitutes permission for the *Cleveland Clinic Journal of Medicine* to publish it in various editions and forms.