

Mastectomy with immediate reconstruction: issues and answers

RICHARD V. DOWDEN, MD, AND RANDALL J. YETMAN, MD

■ Immediate breast reconstruction at the time of mastectomy, whether it involves prosthetic implantation or a myocutaneous flap procedure, has become a standard option for the care of breast cancer patients. The advantages of breast reconstruction are well understood: it helps to eliminate many of the psychological burdens with which mastectomy patients must contend and allows patients to participate in a normal lifestyle. Immediate breast reconstruction eases much of the initial psychological trauma of mastectomy. For patients who require postoperative radiation, reconstruction is often far less complex if done immediately than if delayed, even though radiation increases the chances of capsular contraction. The knowledge that immediate breast reconstruction is available may reduce patients' reluctance to seek medical advice when they find a breast lump.

□ INDEX TERMS: MASTECTOMY; BREAST NEOPLASMS; TIME FACTORS; IMPLANTS, ARTIFICIAL □ CLEVE CLIN J MED 1992; 59:499-503

BREAST RECONSTRUCTION has been performed for more than 90 years, but only within the past 30 years has it become a standard part of the care of mastectomy patients.¹ And only in the past 10 years has breast reconstruction been routinely performed at the time of mastectomy, rather than after a post-mastectomy observation period of from 6 months to 5 years.

Breast reconstruction at the time of mastectomy—whether by prosthetic implantation or use of a myocutaneous flap—offers patients several advantages over waiting. In this article we discuss those advantages, principles of patient selection, available techniques, and associated problems.

From the Department of Plastic Surgery, The Cleveland Clinic Foundation.

Address reprint requests to R.V.D., Head of Section of Breast Surgery, Department of Plastic Surgery, The Cleveland Clinic Foundation, 9500 Euclid Avenue, Cleveland, OH 44195-5031.

PHYSICAL AND PSYCHOLOGICAL BENEFITS

In the 1960s, most patients were obliged to wait 5 years between mastectomy and reconstruction in order to “see whether the cancer would return.” This philosophy did not stand up to thoughtful analysis, because patients did not want to be denied the benefits of reconstruction for such a long period of time, regardless of whether their disease might recur. During the next decade, the interval was first reduced to 2 years, then 1 year, then 6 months. However, actuarial examination of expected local recurrence rates did not support imposing any waiting interval for oncologic purposes.² Since the late 1970s, we have performed breast reconstruction at the time of mastectomy: to date, more than 450 patients at our institution have had immediate breast reconstruction.

Breast reconstruction at the time of mastectomy offers several physical benefits when compared with delayed reconstruction: it eliminates the need for a

separate surgical procedure, the accompanying general anesthesia, and the subsequent hospitalization; and stretching of the mastectomized skin is accomplished before a layer of scar tissue forms between skin and pectoralis muscle. In addition, if it is delayed until after radiation therapy, breast reconstruction is generally much more difficult due to long-term tissue damage caused by the radiation.³

When reconstruction is performed with a submuscular implant, palpation for local recurrence by the patient or her physicians appears to be facilitated because the plane of likely recurrence (between skin and muscle) is thrust forward and spread out over a smooth convex surface for palpation.⁴ Moreover, surveillance mammography of the mastectomy site can be performed after this procedure, which would be impossible without reconstruction.

Reconstruction at the time of mastectomy also carries psychological benefits for the patient. Immediate reconstruction lends a positive aspect to the mastectomy experience and helps to offset some of the patient's fear of mutilation. Although the psychological trauma associated with cancer and mastectomy is profound, a significant part of this trauma is eased if reconstruction has already begun by the time the patient leaves the hospital.⁵

PATIENT SELECTION

Most patients who undergo mastectomy are good candidates for immediate reconstruction. However, some patients are not good candidates. For example, obese patients have a significantly higher postoperative complication rate. Therefore, in these patients breast reconstruction should be delayed, preferably until after weight loss. Smoking also raises the complication rate by impairing vascular perfusion, and should be discouraged. Advanced age itself is not a contraindication to immediate reconstruction. However, patients in poor health should not have reconstruction. In patients who have already undergone radiation therapy of the mastectomy site, reconstruction options are usually limited to procedures more complex than implantation alone.⁶

Virtually all mastectomy patients should be made aware of the possibility of immediate breast reconstruction and should be given the opportunity to discuss it with the plastic surgeon. Patients should be counseled that mastectomy will not disrupt a sound interpersonal relationship, and that breast reconstruction should not be chosen in an attempt to hold together a precarious

one. Of course, patients should not be pressured by well-meaning friends, relatives, or physicians to choose reconstruction.

Patients who are uncertain about reconstruction should not have immediate reconstruction. Some patients are unable to deal with the added complexity of information about breast reconstruction while at the same time trying to cope with understanding the implications of cancer and mastectomy. Some patients may not be able to commit themselves to the time and trouble involved, since reconstruction includes a series of office visits and small procedures spaced out over at least a year.

Once the decision is made to attempt reconstruction, the decision whether to proceed with immediate reconstruction takes place in the operating room after completion of the mastectomy. Reconstruction should be delayed if the condition of the skin flaps and the pectoral muscle is not satisfactory. Tumor size and location do not directly influence the decision to reconstruct, but they do determine the extent of skin and muscle resection, and therefore, they affect the feasibility of immediate reconstruction. Clinical and pathological lymph node status are not considered influencing factors, except in the rare occurrence of fixed axillary nodes which cannot be resected.

If reconstruction at the time of mastectomy is inadvisable, it can generally be performed 6 months later, when the intensity of fibrosis has subsided. Delayed reconstruction should not be performed during active chemotherapy, but immediate reconstruction does not prevent the patient from receiving postoperative or perioperative chemotherapy. Postoperative radiation treatment usually does not interfere with immediate reconstruction, although it can cause capsular contracture.

CURRENT TECHNIQUE

Mastectomy

To achieve the best result, the cancer surgeon and the plastic surgeon cooperate closely. As much skin as possible should be saved without increasing the risk for local recurrence or compromising the likelihood of ultimate cure; this is termed "skin-sparing" mastectomy. The plastic surgeon can then design a closure that is the optimum for purposes of reconstruction. Removal of the biopsy site and the nipple areola and affording access to the axilla may require a single incision, a T-incision, or two separate incisions. It is best if the biopsy site is located near the areola, near the

axilla, or close to a line joining the axilla to the areola.

During the procedure, the patient is positioned symmetrically on the operating table, and both sides of the chest are prepared to allow intraoperative comparison. Perioperative antibiotics are usually given, and intraoperative chemotherapy may be given if indicated. During the mastectomy, the cancer surgeon may proceed in the usual manner without compromising the likelihood of cure in any way.

Certain points of no consequence to the oncologic resection can have considerable impact on the feasibility of reconstruction. The first is to avoid elevating the skin flaps beyond the borders of the breast itself. There is sometimes a tendency, especially in patients with a thicker layer of subcutaneous fat, to elevate the skin inferiorly and medially farther than the limit of the breast tissue. One way the cancer surgeon can help confine this elevation within the limit of the breast is to preoperatively place deep percutaneous silk sutures at the periphery of the breast inferiorly and medially. These sutures will be obvious underneath the skin flaps when the boundary is reached. In bilateral reconstructions, care should be taken not to join the dissections across the midline.

The lateral thoracic fascia which overlies the serratus and pectoralis minor should be left intact if its removal is not necessary. Also, it is very important to avoid incising into the pectoralis muscle fibers near their origin along the sternum or rib cage, unless this is necessary for tumor clearance. Any of these circumstances can require delaying the reconstruction. Furthermore, the thoracodorsal vessels should be left intact if transection of them is not important to achieving cure.

Reconstruction with an implant

After the mastectomy, the plastic surgeon takes over, assessing the adequacy of the muscle and the viability of the skin. Most immediate reconstructions involve implants (*Figure 1*), often of the adjustable type, while others use a flap of skin, fat, and muscle from the lower abdomen which is transferred either upon a pedicle or by microvascular anastomosis (*Figure 2*).

The implant is generally placed behind the pectoralis major muscle. It may also be necessary to elevate all, or portions of, the pectoralis minor and serratus in order to completely protect the implant from the incisions. Most of the implants we use are adjustable, allowing accurate matching to the size of the other breast and affording a means of slowly stretching the skin to compensate for that removed at

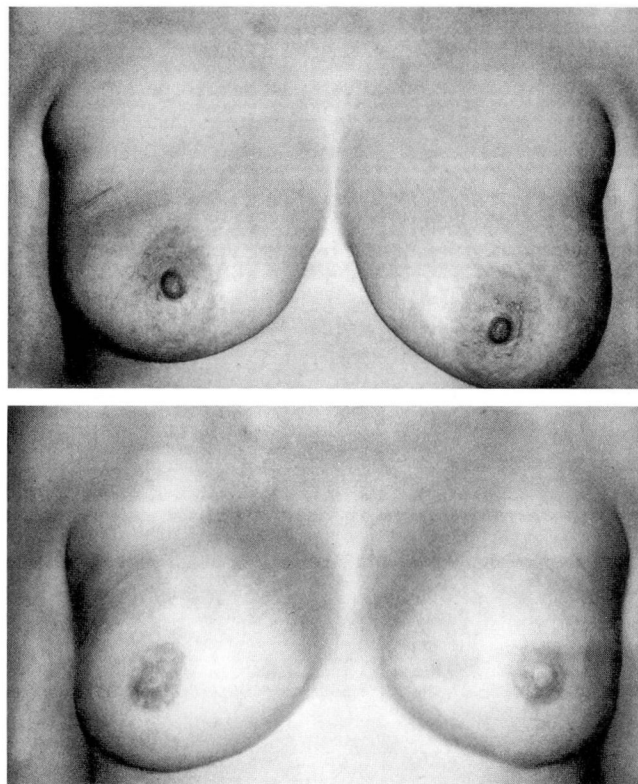


FIGURE 1. A patient before (top) and after (bottom) bilateral total mastectomy and immediate reconstruction with implants. The new nipples and areolae were formed at a later procedure.

mastectomy. If modification of the opposite breast is required, it can be performed at the same time as the reconstruction. Approximately one third of our patients have the opposite breast reduced, lifted, or augmented, or have bilateral mastectomy.

After reconstruction, the plastic surgeon oversees much of the postoperative care. The usual hospital stay is two or three nights after reconstruction with implantation and six or seven nights after flap reconstruction. Exercises using the full range of motion are started on the first postoperative day, but forceful use of the pectoralis muscle is prohibited. Patients are advised to not drive for approximately 2 weeks, but after 3 weeks full activity (including sports) can be resumed.

If an adjustable implant was used, it is expanded with saline solution injected through a detachable filling port; this is done at weekly intervals and is continued until the implant is larger than the desired final size. It is left overexpanded for several months, after which the excess saline is withdrawn (an office procedure), thus bringing the breasts to equal size. After another few

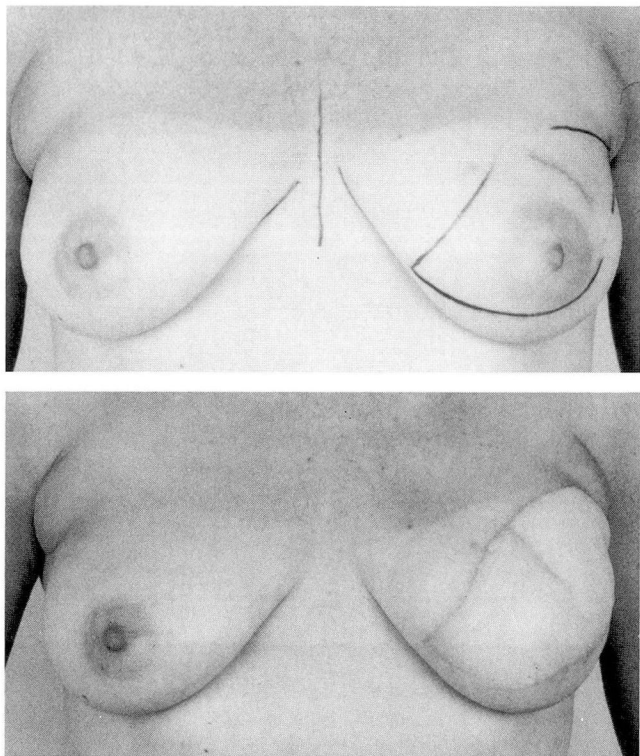


FIGURE 2. A patient before (top) and after (bottom) modified radical mastectomy and immediate reconstruction with a microvascular abdominal flap. Nipple and areola formation not yet performed.

months, the adjustable implant is exchanged for a regular implant or, more usually, the detachable filling port is removed. These procedures, performed under local anesthesia, are often combined with nipple reconstruction, which is accomplished using local flaps or small skin grafts. One to twelve months later the nipple-areola color is added by tattooing.

If a major flap procedure has been used for reconstruction, a second procedure is usually required 4 or 6 months later; this procedure, performed under local or general anesthesia, may consist of tailoring and contouring the flap to provide optimal shape and symmetry, or may involve the addition of an implant.

In the postoperative period, the patient is followed by both the general and plastic surgeons and is also returned to the care of her personal physician. Postoperative chemotherapy or radiation therapy can be started if indicated. The reconstructed breast is easily examined by palpation, and mammography is recommended for both the reconstructed breast and the opposite breast, in accordance with the American Can-

cer Society guidelines. Although mammography in the presence of implants requires special techniques for taking exposures and interpreting the radiographs, unreconstructed mastectomy flaps do not allow mammographic surveillance.

COMPLICATIONS AND CONCERNS

The main problem with implantable devices of any type is the formation of a surrounding scar tissue capsule which can tighten and contract. This is of little consequence in the case of a hip joint or pacemaker, but in the case of a breast implant it may lead to unacceptable firmness. This condition may require surgery, although the number of patients needing such surgery can be kept under 10% through daily exercises of external compression massage or the use of certain textured-surface implants.

Immediate reconstruction by any technique might be expected to have a higher rate of postoperative complications such as bleeding, infection, seroma, or flap necrosis than delayed reconstruction. Actually, mastectomy with immediate reconstruction has no higher risk of complications than mastectomy alone.⁷ Naturally, any intraoperative indication of jeopardy to the skin would lead to the decision to delay reconstruction.

Despite recent aggressively negative publicity about implants, they are considered safe and have been used in well over 1 million women over the past 30 years. Like heart valves, pacemakers, and most hip joints, breast implants are not fully certified by the US Food and Drug Administration, although they are approved for use. A significant percentage of laboratory rats develop soft-tissue sarcomas from implants, just as they do from hip joints, pacemakers, and all other implanted materials. This had given rise to concern that silicone gel implants could cause cancer in humans. However, breast implants over the past 30 years have caused no cancer in humans⁸; moreover, the rodent soft-tissue sarcoma does not occur in humans. At the Cleveland Clinic, we have not used polyurethane-covered implants, which have been discontinued. The implants we use contain only medical-grade silicone and/or saline.

Concerns were raised over a possible association between silicone devices and arthritis or other connective tissue diseases. Although this continues to be investigated, on February 20, 1992, the FDA Scientific Advisory Panel, after carefully studying all available data on silicone implants, concluded that there was no

evidence to indicate any connection with those diseases. Connective tissue disorders occur in over 10,000 per 1 million women per year *without* implants, and the rate is not higher in women with implants. Of course a number of women with these disorders will also have implants, but so far no cause-and-effect association has been found.^{9,10} Theoretically, such a link is possible, but if it occurs it must be rare.

About 3% of implants over the past 30 years have required replacement for breakage. However, because no systemic reaction has been observed in connection with either the silicone gel contents of the implant or the silicone polymer shell, there is as yet no evidence that a leaking or broken implant poses any danger to the health of the patient. In the United States, no cases of "silicone poisoning" have been reported in connection with any use of medical silicone.¹¹ Nevertheless, an endoscopy technique pioneered at the Cleveland Clinic enables the plastic surgeon to rapidly check the implant for leaks under outpatient local anesthetic. It is likely that implantation will continue to be the method

most frequently used for breast reconstruction, depending upon the availability of implants.

CONCLUSION

Since establishing immediate reconstruction as a standard part of care for our mastectomy patients,¹² we have noticed a considerable improvement in their peace of mind as they approach mastectomy. Moreover, some postoperative trauma is eased. Immediate reconstruction may also lead to earlier treatment of breast cancer, since knowledge that immediate breast reconstruction is available may reduce patients' reluctance to seek medical advice when they find a breast lump. Formerly, patients may have had negative feelings about the cancer surgeon and referring physician, who were associated with an experience that was entirely negative. The possibility of immediate breast reconstruction permits the referring physician, the cancer surgeon, and the plastic surgeon to participate actively in the patient's rehabilitation.

REFERENCES

1. Snyderman RK, Guthrie RH Jr. Reconstruction of the female breast following radical mastectomy. *Plast Reconstr Surg* 1971; **47**:565-567.
2. Dowden RV, Blanchard JB, Greenstreet RL. Breast reconstruction: selection, timing, and local recurrence. *Ann Plast Surg* 1983; **10**:265-269.
3. Houpt P, Dijkstra R, Storm van Leeuwen JB. The result of breast reconstruction after mastectomy for breast cancer in 109 patients. *Ann Plast Surg* 1988; **21**:516-525.
4. Dowden RV, Horton CE, Rosato FE, McCraw JB. Reconstruction of the breast after mastectomy for cancer. *Surg Gynecol Obstet* 1979; **149**:109-115.
5. Schain WS, Wellisch DK, Pasnuaro, Lansuer KJ. The sooner the better: a study of psychological factors in women undergoing immediate vs. delayed breast reconstruction. *Am J Psychiatry* 1985; **142**:40-46.
6. Gibbons WP. Caution in expanding radiated tissue [letter]. *Plast Reconstr Surg* 1987; **80**:871.
7. Vinton AL, Traverso LW, Zehring RD. Immediate breast reconstruction following mastectomy is as safe as mastectomy alone. *Arch Surg* 1990; **125**:1303-1307.
8. VanNatta BW, Thurston JB, Moore TS. Silicone breast implants—is there cause for concern? *Indiana Med* 1990; **83**:184-185.
9. Sergott TJ, Limoli JP, Baldwin CM Jr, Laub DR. Human adjuvant disease, possible autoimmune disease after silicone implantation: a review of the literature, case studies, and speculation for the future. *Plast Reconstr Surg* 1986; **78**:104-114.
10. Weisman MH, Vecchione TR, Albert D, Moore LT, Mueller MR. Connective tissue disease following breast augmentation: a preliminary test of the human adjuvant disease hypothesis. *Plast Reconstr Surg* 1988; **82**:626-630.
11. Food and Drug Administration. Background information on the possible health risks of silicone breast implants. Washington, December 18, 1990.
12. Dowden RV. The current approach to breast reconstruction. *Oncology* 1987; **1**:29-38.