**JOSH MILLER, DO**

Department of Pulmonary and Critical Care Medicine, Cleveland Clinic

JANET MAURER, MD

Head, Section of Lung Transplantation, Department of Pulmonary and Critical Care Medicine, Cleveland Clinic

ATUL MEHTA, MD

Head, Section of Bronchology; Vice Chairman, Department of Pulmonary and Critical Care Medicine, Cleveland Clinic

A 43-year-old woman with shortness of breath

A 43-YEAR-OLD WOMAN presents with shortness of breath while sitting or standing. The problem began approximately 3 months ago. Five months previously she underwent a right pneumonectomy to remove an adenocarcinoma of stage T2, with no lymph node involvement and no distant metastases. Ten days after surgery, her postoperative course was complicated by a stump leak requiring surgical correction. One month later she started to have episodes of shortness of breath, especially while bending forward. Her symptoms gradually progressed until now she can obtain relief only in the supine position.

The patient is confined to a wheelchair and is cyanotic. **TABLE 1** shows her arterial blood gas values in the lying and standing positions while breathing room air.

■ DYSPNEA WHILE STANDING

1 What term best describes dyspnea while standing?

- Trepopnea

- Orthopnea
 Orthodeoxia
 Platypnea

The patient has *platypnea*: shortness of breath in the upright or standing position. Her arterial blood gas values indicate she also has *orthodeoxia*, ie, significantly more oxygen desaturation when standing than when lying down. *Orthopnea* describes shortness of breath in the supine position, which is a clue that the heart may be involved. *Trepopnea* is dyspnea in the right or left lateral decubitus position, which can occur with intrapulmonary shunting or a ventilation/perfusion mismatch.

Case continued

The patient has already undergone a ventilation/perfusion scan, duplex ultrasonography of both lower extremities, pulmonary angiography, transesophageal echocardiography, and dobutamine echocardiography at another hospital, and all of the results were normal.

Catheterization of the right side of the heart reveals normal pulmonary artery pressures (20/10 mm Hg). As time goes on, the patient's platypnea grows worse, and she requires supplemental oxygen.

■ WHAT IS THE CAUSE OF HER SYMPTOMS?

2 Which of the following is the most likely cause of this patient's symptoms?

- Pulmonary embolism
 Primary pulmonary hypertension
 Severe restrictive impairment as a consequence of the pneumonectomy
 Coronary artery disease
 A right-to-left interatrial shunt

TABLE 1

The patient's arterial blood gas values on admission

MEASUREMENT	VALUE SUPINE	VALUE STANDING	NORMAL RANGE
pH	7.44	7.46	7.35–7.45
Pco ₂ , mm Hg	29.8	26.3	34–46
Pao ₂ , mm Hg	59.5	44.8	85–95
HCO ₃ , mmol/L	20.8	18.5	22–26
O ₂ saturation, %	88	77	95–98



The normal findings on her duplex studies, ventilation/perfusion scans, and pulmonary angiogram rule out pulmonary embolism, and her normal right heart pressures rule out primary pulmonary hypertension. Significant coronary artery disease and left ventricular dysfunction can be ruled out on the basis of the normal dobutamine stress echocardiogram.

The patient's pulmonary function tests showed a restrictive pattern, ie, a diminished vital capacity (VC) but a normal forced expiratory volume in 1 second (FEV₁). This finding could explain her dyspnea, but not necessarily her platypnea and orthodeoxia. Moreover, a pure restrictive impairment would lead to alveolar hypoventilation (increased P_{CO₂}), whereas this patient had partially compensatory respiratory alkalosis (decreased P_{CO₂}).

Of the given conditions, only a right-to-left interatrial shunt, especially in the upright position, cannot be excluded.

■ DIFFERENTIAL DIAGNOSIS

3 Which one of the following disorders does not cause platypnea and orthodeoxia?

- Hepatopulmonary syndrome
- Chronic obstructive pulmonary disease (COPD)
- Pulmonary arteriovenous shunts
- Intracardiac right-to-left malformations
- Idiopathic pulmonary fibrosis

Platypnea and orthodeoxia are primarily due to right-to-left shunting (ie, a process that allows deoxygenated blood to return from the right side of the heart to the left without undergoing oxygenation), occurring preferentially in the upright position.

This phenomenon is unlikely to occur in idiopathic pulmonary fibrosis. It has been reported in patients with the other conditions listed, although the physical basis is different in each of them.

For example, in hepatopulmonary syndrome, the shunting takes place in intrapulmonary vascular dilations, mainly in the lower lobes.¹

Intracardiac shunts involve actual anatomic abnormalities—defects in the atrial or ventricular septums. In the upright posi-

tion, gravity can enlarge the opening, making the shunting worse.²

Pulmonary arteriovenous malformations also cause anatomic abnormalities. Approximately 65% occur in the lower lobes, perhaps because blood flow and pressure are highest there, particularly in the upright position.³

Although most patients with COPD experience the opposite problem—orthopnea—a very few experience orthodeoxia and platypnea. Altman and Robin⁴ ascribed this paradoxical situation to a diffuse zone 1 phenomenon. (The lungs can be divided into three zones on the basis of alveolar and vascular pressures. In zone 1 the alveolar pressure exceeds the pulmonary artery pressure, and the alveoli therefore collapse the surrounding pulmonary capillaries, creating areas of respiratory dead space, ie, ventilated but underperfused segments of lung. Elevation of the thorax when standing would further lower the pulmonary arterial pressure in the upper lungs, accentuating the decrease in pulmonary blood flow there. In zone 2 the alveolar pressure is less than the pulmonary artery pressure but greater than the pulmonary vein pressure, and in zone 3 the alveolar pressure is less than the pulmonary vein pressure.)

■ WHAT FURTHER TESTS ARE NEEDED?

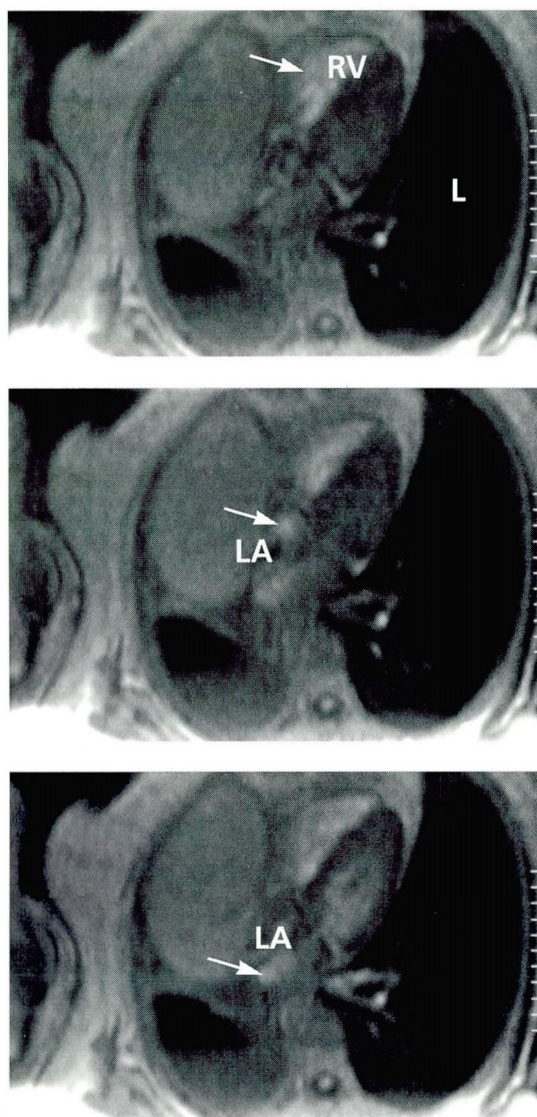
4 Which of the following tests can aid in the diagnosis of an interatrial shunt?

- Echocardiography with a bubble study
- Magnetic resonance imaging of the heart
- Perfusion lung scan
- Computed tomography
- Arterial blood gasses while breathing 100% oxygen

One can detect intracardiac shunts by means of an echocardiogram with a bubble study—a technique that uses microscopic bubbles injected into the venous circulation as a contrast medium. The bubbles normally diffuse out into the alveoli and thus do not traverse the lungs. Thus, if they appear in the left atrium, a shunt probably is present.

Magnetic resonance imaging (MRI) with a contrast dye (the turbo fast low-angle shot—turboFLASH—technique) can also reveal

From 16% to 24% of the general population has a patent foramen ovale



TurboFLASH MRI can demonstrate a cardiac shunt

FIGURE 1. Three magnetic resonance imaging scans (sequential from top to bottom), performed using the turbo fast low-angle shot (turboFLASH) technique. Note the movement of the contrast material (arrow) from the right ventricle (RV) in the first image to the left atrium (LA) in the second and third images. The failure of the contrast to enter the lung (L) is evidence of a right-to-left shunt.

intracardiac shunts. This type of MRI allows the radiologist to assess the first-pass effect of the contrast to determine if there is a shunt and also to estimate the flow through the shunt.

A perfusion lung scan will not show any perfusion defects if an intracardiac shunt is

present; however, it will show increased uptake of radioactive microaggregates in the brain and kidneys suggestive of a right-to-left intracardiac shunt.

Measuring arterial blood gas levels on 100% oxygen is a simple way to calculate the shunt fraction.

CT scanning has not been shown to help in the diagnosis of an intracardiac shunt.

Our patient underwent a turboFLASH MRI scan (FIGURE 1), which showed enhanced mobility of the right atrium and a patent foramen ovale, which was asymptomatic prior to the pneumonectomy. Another transesophageal echocardiogram using color contrast was performed, which revealed right-to-left flow. The shunt was more pronounced when the patient assumed the upright position from a supine position.

■ PATENT FORAMEN OVALE

5 What is the prevalence of a patent foramen ovale in the general population?

- 1% to 3%
- 4% to 8%
- 10% to 15%
- 16% to 24%

Studies have shown that 16% to 24% of the population have a patent foramen ovale.²

The patient underwent surgical correction of the patent foramen ovale, and her symptoms resolved completely.

■ RIGHT-TO-LEFT INTERATRIAL SHUNT FOLLOWING RIGHT PNEUMONECTOMY

Loss of alveolar volume, restrictions of the vascular bed, chest wall pain, and diaphragmatic dysfunction are common causes of shortness of breath after a pneumonectomy. Right-to-left interatrial shunts are a rare cause, with only 18 other reported cases in the literature.⁵⁻¹¹ However, with the high prevalence of patent foramen ovale in the general population, this complication is likely to occur frequently, and we suspect it is underdiagnosed.

The exact mechanism of platypnea and orthodeoxia is not fully understood. One explanation may be that right atrial pressures



exceed left atrial pressures, owing to increased pulmonary vascular resistance due to changes produced by the surgery. The increased pressure would reroute the flow of blood preferentially through the patent foramen ovale. However, this does not seem to be the case, as in most of the reported cases the patients had normal right heart pressures.⁹

LaBresh et al⁶ and van Rossum et al⁸ believe that postoperative changes in mediastinal structures lead to anatomic alterations in the relationship of the two atria, causing distortions of the foramen ovale while the patient is standing and cause preferential shunting of blood from the inferior vena cava even in the face of lower right atrial pressures.

Merko et al¹⁰ concur that a "streaming" of blood from the inferior vena cava through a patent foramen ovale is the cause of the shunt. The mediastinal shift that occurs after pneumonectomy and the weight of the heart while standing pulls the interatrial septum downward, causing the foramen ovale to widen or newly open.

■ CONCLUSION

A right-to-left intracardiac shunt can cause platypnea and orthodeoxia as described in this case. The most likely cause of right-to-left intracardiac shunting after a right pneumonectomy is a change in the mediastinal anatomy that leads to direct streaming of blood from the inferior vena cava through a patent foramen ovale even in the face of normal right heart

pressures. Surgical correction of the defect is the only treatment. A high degree of suspicion is needed to diagnose this condition. MRI, transesophageal echocardiography with color contrast, or both are the tests of choice to establish the diagnosis. ■

■ REFERENCES

1. Lange PA, Stoller JK. The hepatopulmonary syndrome. *Ann Intern Med* 1995; 122:521-529.
2. Bedford DE. The anatomical types of atrial septal defect: their incidence and clinical diagnosis. *Am J Cardiol* 1960; 6:568.
3. Goodenberger DM. Pulmonary arteriovenous malformations. In: Fishman A, editor. *Fishman's Pulmonary Diseases and Disorders*, 3rd ed. New York: McGraw-Hill; 1998:1375-1385.
4. Altman M, Robin ED. Platypnea (diffuse zone I phenomenon?) *N Engl J Med* 1969; 281:1347-1348.
5. McLeroy MB, Bates DV. Respiratory function after pneumonectomy. *Thorax* 1956; 11:303-311.
6. LaBresh KA, Pietro DA, Coates EO, Khuri SF, Folland ED, Parisi AF. Dyspnea after left pneumonectomy. *Chest* 1981; 79:605-607.
7. Seward JB, Hayes DL, Smith HC, et al. Platypnea-orthodeoxia: clinical profile, diagnostic workup, management, and report of seven cases. *Mayo Clin Proc* 1984; 59:221-231.
8. van Rossum P, Plokker HW, Ascoop CA. Breathlessness and hypoxia in the upright position after pneumonectomy. *Eur Heart J* 1988; 9:1230-1233.
9. Smeek FW, Twisk SP, Berreklouw E, Gooszen HC, Postmus PE. Dyspnea after pneumonectomy. *Eur Respir J* 1991; 4:243-245.
10. Mercho N, Stoller JK, White RD, Mehta AC. Right-to-left interatrial shunt causing platypnea after pneumonectomy. A recent experience and diagnostic value of dynamic magnetic resonance imaging. *Chest* 1994; 105:931-933.
11. Bakris NC, Siddiqi AJ, Fraser CD Jr, Mehta AC. Right-to-left interatrial shunt after pneumonectomy. *Ann Thorac Surg* 1997; 63:198-201.

We suspect this problem is underdiagnosed

We Welcome Your Letters

WE ENCOURAGE YOU TO WRITE, either to respond to an article published in the *Journal* or to address a clinical issue of importance to you. You may submit letters by mail, fax, or e-mail.

MAILING ADDRESS

Letters to the Editor
Cleveland Clinic Journal of Medicine
9500 Euclid Ave., NA32
Cleveland, OH 44195

FAX

216.444.9385

E-MAIL ccjm@ccf.org

Please be sure to include your full address, phone number, fax number, and e-mail address. Please write concisely, as space is limited. Letters may be edited for style and length. We cannot return materials sent. Submission of a letter constitutes permission for the *Cleveland Clinic Journal of Medicine* to publish it in various editions and forms.