

THE TREATMENT OF LYMPHOID HYPERPLASIA OF NASOPHARYNX BY RADIUM

H. E. HARRIS, M.D., and E. L. MONTGOMERY, M.D.

Department of Otolaryngology

Many patients have developed excessive hyperplasia of lymphoid tissue in the pharynx and nasopharynx, predisposing them to frequent colds, deafness, otitis media, chronic nasal congestion, and postnasal discharge. Why this hyperplasia occurs in some persons and not in others is not clearly understood. The condition is usually seen in patients who have had repeated attacks of upper respiratory infections and their complications.

Surgical removal of tonsils and adenoids has been an accepted form of treatment for many years and of unquestionable value in properly selected cases. However, in many of these cases the hyperplasia has continued to develop postoperatively. Repeated attempts at surgical removal of lymphoid tissue have often been hazardous to the patient, as too extensive removal of lymphoid tissue can result in scar tissue formation, and damage to the eustachian tube orifice may result in permanent closure.

The most rational approach to the treatment of lymphoid hyperplasia in the nasopharynx has been advocated by Dr. S. J. Crowe of Johns Hopkins Hospital.

The main problem is to remove the hyperplastic lymphoid tissue, which is often diffusely spread throughout the entire nasopharynx and postnares or localized in the fossa of Rosenmüller or eustachian tube orifice. These regions are inaccessible for surgical removal. As lymphocytes are very radiosensitive, a small dosage of gamma and beta rays is sufficient to inhibit mitosis in the germinal centers and thus stop the formation of new lymphocytes. The dose is small, therefore there is no danger of damage to the nasopharyngeal mucous membrane. Crowe's observations lead him to believe that lymphocytes, like skin cells, have a brief cycle and that under irradiation no new lymphocytes are formed to replace the old. The lymphoid mass shrinks and finally disappears, leaving the area covered by mucous membrane.

As Crowe has pointed out, it is not so much the size but the location of lymphoid nodules that is important. Small nodules in the fossa of Rosenmüller, about the pharyngeal orifice, or the area between the tubal orifice and the posterior end of the middle turbinate, may seriously impair the ventilating function of the eustachian tubes.

The nasopharynx is the most important location of a primary focus of infection in the upper air passage. This is due to the rich content of lymphoid tissue in the mucous membrane and to the proximity of the nasopharynx to the nasal passages, accessory nasal sinuses, and eustachian tubes.

Complications encountered with lymphoid hyperplasia of the nasopharynx are: recurrent colds, chronic rhinitis, chronic tracheobronchitis, sinusitis, asthmatic bronchitis, deafness, chronic or recurrent otitis media, and mastoiditis. In addition there are those due to purely mechanical causes, chiefly aero-otitis or barotrauma, which was encountered so extensively in our air force during the war.

Examination of Nasopharynx

This portion of the upper air passage is not easily examined. In most adults and some children a satisfactory view can be obtained with a mirror. However, in many the nasopharyngoscope is essential for a complete inspection. Occasionally in children with impaired hearing general anesthesia has been used to obtain a satisfactory examination. It is important to shrink the nasal mucous membrane and to remove all excess nasal secretions before applying a local anesthetic, as less topical anesthetic will then be necessary. The insertion of the pharyngoscope through a perforation in a napkin or piece of folded gauze will afford some protection to the examiner.

During the examination the orifices of the eustachian tubes should be clearly seen, as should the vault of the nasopharynx, posterior end of the septum, and the area both anterior and posterior to the tubal orifices.

The fact that the tonsils and adenoids have been removed or that the tonsillar fossae and pharynx appear normal does not mean that lymphoid tissue is absent in the nasopharynx. If a very large adenoid is present it is safer to remove the mass surgically and follow with irradiation, since less radium treatment will then be necessary. In the presence of an acute infection, irradiation should be postponed for approximately four weeks. In cases of marked degrees of chronic infection the first treatment is given in two doses one week apart. If these precautions are observed acute otitis media will rarely develop immediately after the radium treatment.

Lymphoid tissue in the nasopharynx, especially when located near the eustachian tube orifice, interferes with proper functioning of the tubes and predisposes the patient to frequent colds, chronic rhinopharyngitis, chronic closure of the eustachian tubes, otitis media, and deafness. Crowe and his associates in a study of 1365 children between 8 and 13 years of age found that more than 75 per cent had a pronounced

LYMPHOID HYPERPLASIA OF NASOPHARYNX

recurrence of lymphoid tissue in the nasopharynx following tonsillectomy and adenoidectomy. This was due to the inability to remove completely the lymphoid tissue by surgical means.

Because of the complications that frequently accompany the presence of this lymphoid tissue, it should be eradicated by the most effective means which will produce no harm to the patient. Both x-ray therapy and irradiation by radium have been used.

It is difficult to deliver enough roentgen rays to the nasopharynx, as approximately one-half of the rays delivered to the neck are absorbed by the soft tissues before they reach the nasopharynx. Several portals must be used in order to prevent skin irritation. This excessive dosage subjects the ossification centers of the skull and face bones to a large amount of radiation. It is also difficult to keep young children in a position for accurate cross-firing for the entire treatment. Good results cannot be expected unless the maximum intensity of treatment is delivered in and around the orifice of the eustachian tube.

In contrast to the x-ray, the radium nasal applicator can be placed on the exact spot where the treatment is most needed (fig. 1). Under local anesthetic the applicator is passed along the floor of the nose until the tip touches the posterior pharyngeal wall. Because of the sensitivity of lymphocytes to beta and gamma irradiation, the dosage employed is so small that there is no danger of a burn or of drying the mucous membrane.

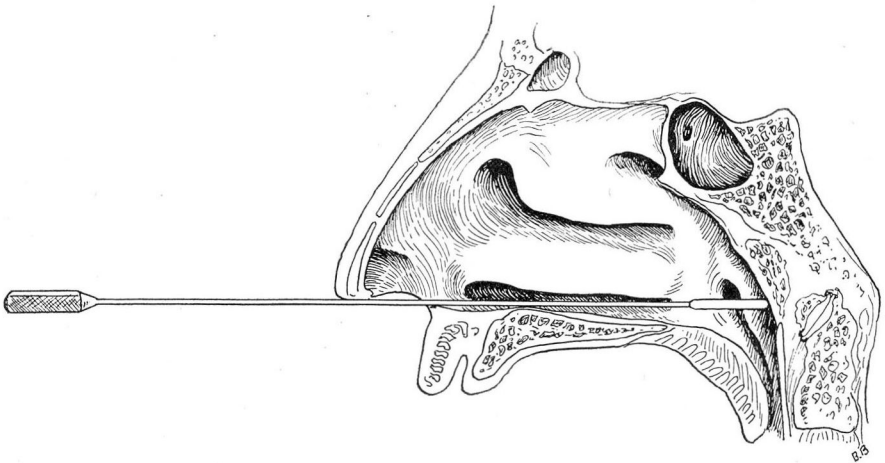


FIG. 1. Schematic illustration of nose and nasopharynx showing position of radium applicator during a treatment.

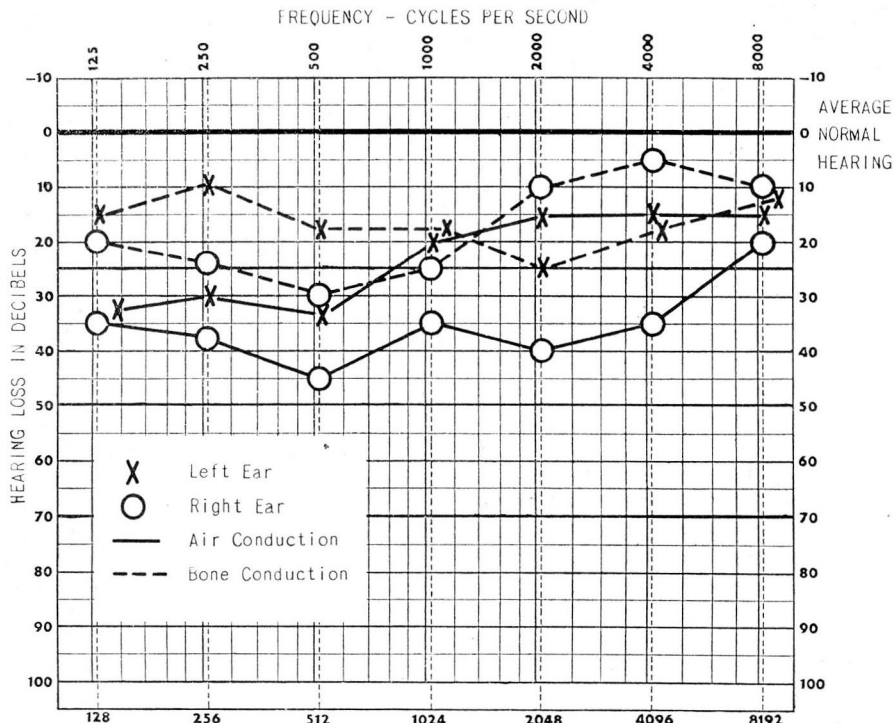


FIG. 2. Case 1. Audiogram before treatment reveals bilateral conductive deafness more marked in right ear.

Case Reports

Case 1. A 9-year-old girl was brought to the Clinic with the chief complaint of deafness of two months' duration. There was no history of otitis media or unusual childhood disease. Physical examination was negative except for lymphoid hyperplasia of the nasopharynx and moderately retracted membrana tympani. Tonsils and adenoids had been removed. Audiogram revealed bilateral conductive deafness (fig. 2).

The patient was given 3 applications of radium to the nasopharynx at monthly intervals. An audiogram six weeks later revealed normal hearing bilaterally (fig. 3).

Case 2. A 12-year-old boy was brought to the Clinic with the complaint of discharging right ear of one week's duration. This had been preceded by a severe upper respiratory infection. Past history revealed numerous similar attacks since early childhood, even though tonsillectomy and adenoidectomy had been performed. Physical examination was negative except for a diffuse lymphoid hyperplasia of the nasopharynx and a reddened, edematous, bulging right tympanic membrane.

The acute phase was treated by chemotherapy, and four weeks later the patient was given his first radium treatment, although the ear was still draining. An audiogram taken at the time of the first treatment revealed bilateral conductive deafness (fig. 4).

LYMPHOID HYPERPLASIA OF NASOPHARYNX

Four weeks after the first radium treatment the right ear was no longer draining. After 3 radium applications the eustachian tubes were found to be well open to the insufflation of air, and the audiogram taken one month after the third treatment revealed normal hearing bilaterally (fig. 5).

Case 3. A 9-year-old boy was brought to the Clinic with the complaint of deafness of the right ear of nine months' duration. There was no history of otitis media. Physical examination revealed the tonsils large and the orifices of the eustachian tubes obscured by the adenoids. Tympanic membranes were retracted. Eustachian tubes were not well open to the insufflation of air. Audiograms revealed a mixed type of deafness of the right ear (fig.6).

The enlarged tonsils and adenoids were surgically removed and subsequent radium applications given to preserve as much hearing as possible. An audiogram immediately following the fourth treatment showed improvement of hearing in the right ear (fig. 7).

During the past two years a total of 144 patients have been treated at Cleveland Clinic for lymphoid hyperplasia of the nasopharynx according to the method advocated by Crowe and his associates.

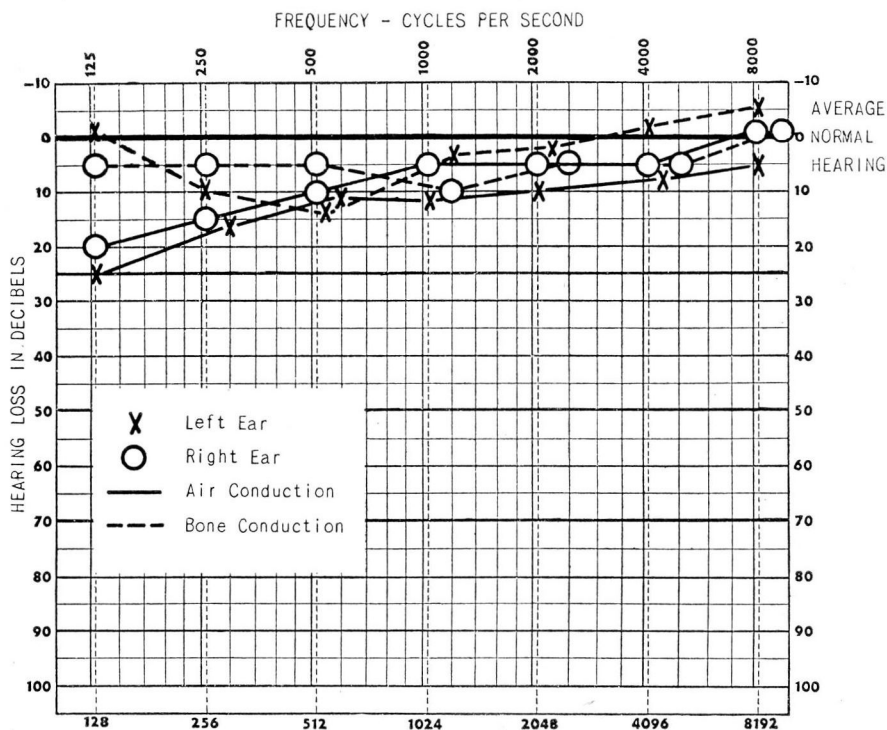


FIG. 3. Case 1. Audiogram reveals essentially normal hearing six weeks following third radium treatment.

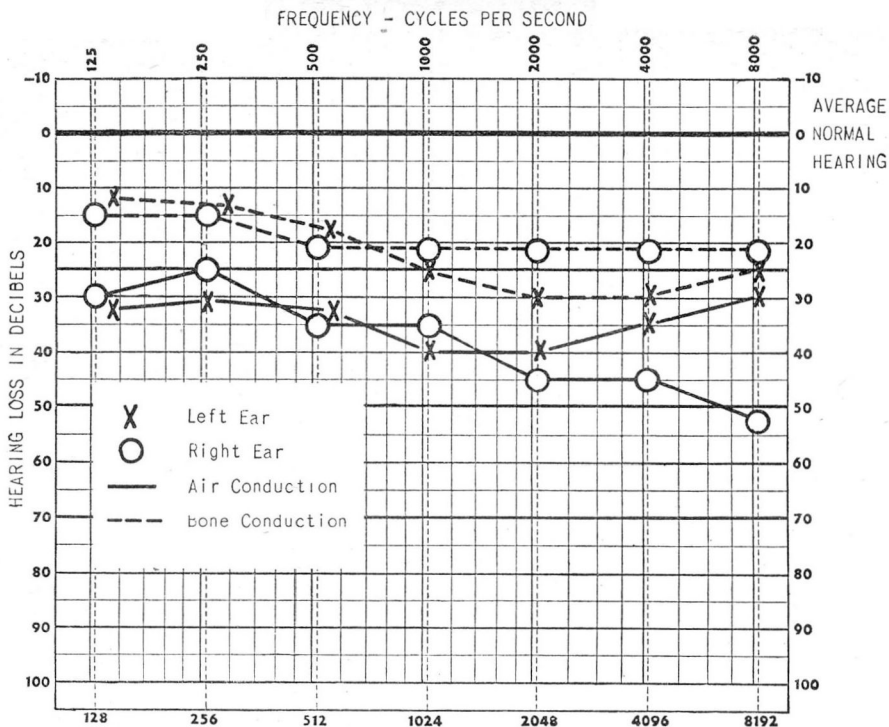


FIG. 4. Case 2. Audiogram reveals bilateral conductive deafness with air conduction at 30 to 40 decibel level in both ears.

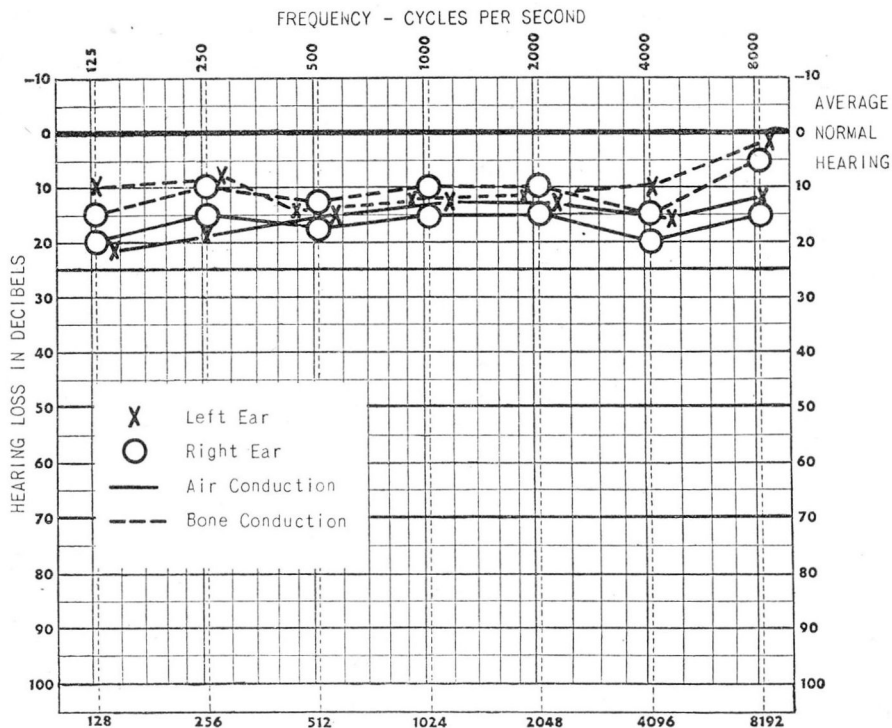


FIG. 5. Case 2. Audiogram one month after third radium treatment reveals hearing has returned to normal range.

LYMPHOID HYPERPLASIA OF NASOPHARYNX

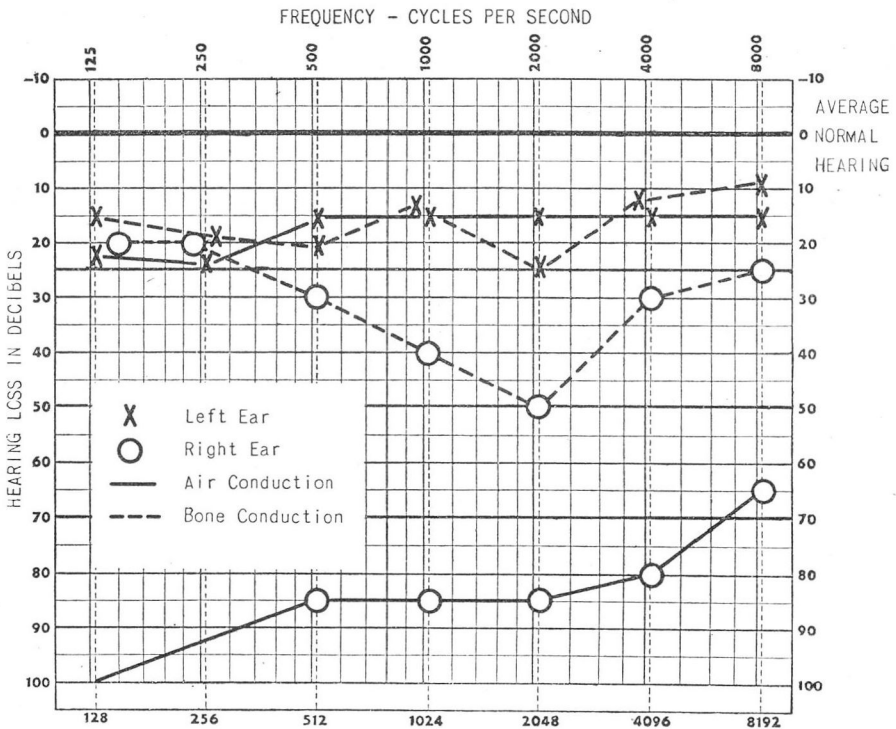


FIG. 6. Case 3. Audiogram reveals pronounced hearing loss of the mixed type in the right ear. Normal hearing in the left ear.

The dosage used was 2 gram minutes to each side of the nasopharynx, repeated for 3 to 4 treatments at monthly intervals. The first 42 cases were treated with an applicator having a brass filter of 1 mm. thickness prepared by Dr. Otto Glasser of the Research Division. This was later replaced by a smaller applicator of monel metal 25 cm. long and having a radium containing chamber 15 mm. in length and 2.3 mm. in diameter. This contained 50 mg. of radium. The latter instrument allows passage of more beta rays than the 1 mm. of brass in the radon applicator, but the results are as good and the dosage is constant, eight and one-half minutes on each side. The tip should be held momentarily under a faucet of running water, then dipped in alcohol, again washed with running water, and dipped in oil before inserting it into the patient's nose.

The operator should wear rubber gloves and avoid wiping the applicator with gauze because of exposure to the hands. When the applicator is not in use it should be kept in a lead cylinder.

Cases should be carefully selected for this type of treatment. Indiscriminate use of radium should be avoided. It is not a panacea for all nasal and ear complaints. Whether it will improve the hearing in a given case depends on the type of obstruction of the eustachian tube and the duration of the impairment. Its greatest value is in re-establishing the patency of an eustachian tube which is closed by lymphoid tissue and in preventing repeated attacks of otitis media.

The results have been gratifying in mildly and moderately deaf children, but less so in adults or extremely deaf children.

Using Crowe's method, uniformly good results have been obtained, particularly in children with deafness associated with partial or complete obstruction of the eustachian tubes. There has been a notable decrease in the number of upper respiratory infections and their complications in the patients treated.

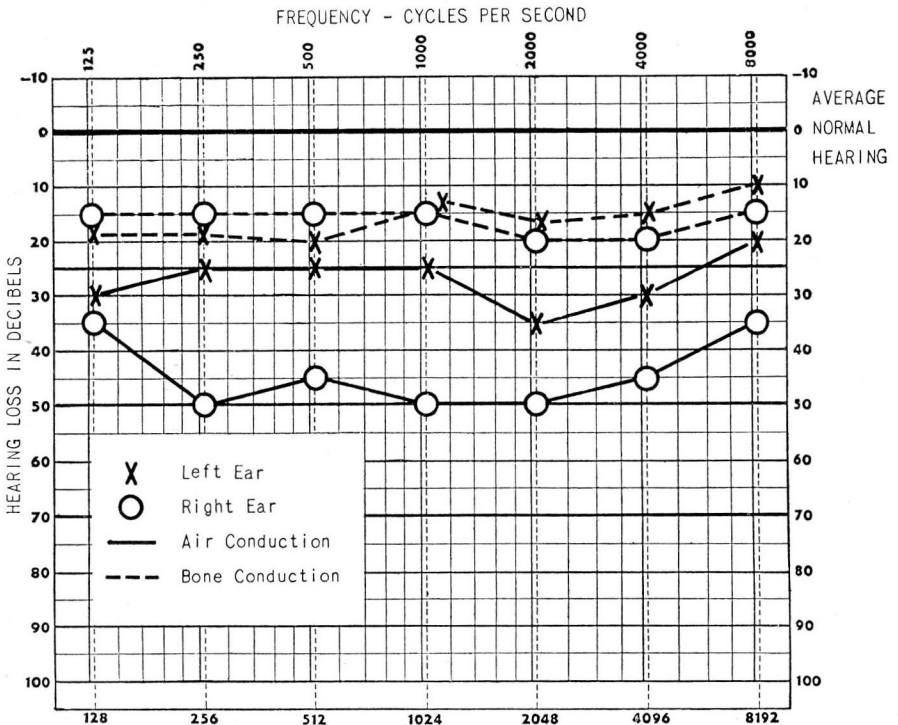


FIG. 7. Case 3. Following the fourth radium treatment the audiogram showed definite improvement in the right ear but not to normal range.