

THE CLINICAL PICTURE

JASON M. RIZZO, BS

Department of Dermatology, School of Medicine and Biomedical Sciences, University of Buffalo, NY

LESLEY C. LOSS, MD

Department of Dermatology, School of Medicine and Biomedical Sciences, University of Buffalo, NY

ILENE L. ROTHMAN, MD

Department of Dermatology, School of Medicine and Biomedical Sciences, University of Buffalo, Buffalo, NY; Department of Dermatology, Women and Children's Hospital of Buffalo, NY

The Clinical Picture

Hyperpigmented patches on the neck, shoulder, and back

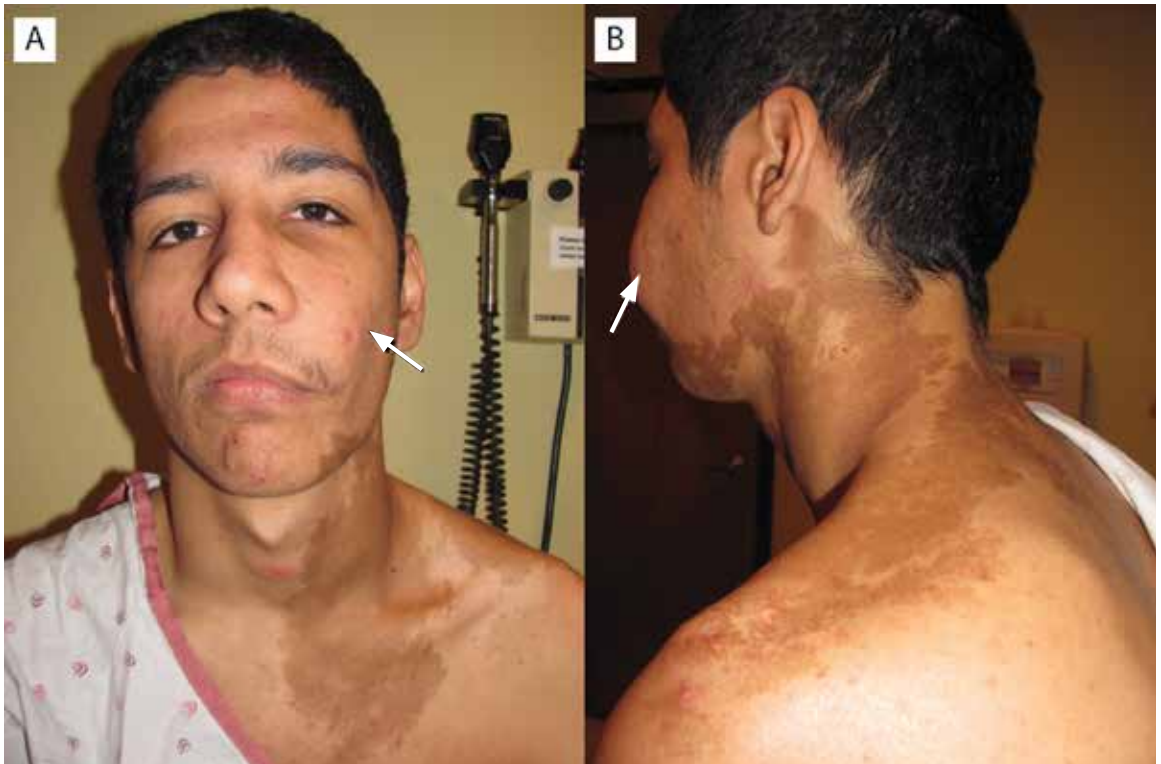

FIGURE 1. Hyperpigmented patches with irregular borders on the left neck, shoulder, and back. The prominence of the zygoma (arrows) reflects underlying fibrous dysplasia.

DURING A ROUTINE EXAMINATION, a 17-year-old boy was noted to have unilateral hyperpigmented patches on his left neck, shoulder, and back. The lesions had been present since birth, had not changed in size or color, and were asymptomatic. His mother had noted an increase in the size of his left jaw starting at age 1.

doi:10.3949/ccjm.80a.12033

The hyperpigmented patches had irregular borders (**FIGURE 1**). The skin was otherwise clear. Laboratory testing from 5 years earlier showed normal levels of dehydroepiandrosterone, prolactin, parathyroid hormone, thyroxine, and thyroid-stimulating hormone. Computed tomography showed a “ground-glass” appearance of the bones at the base of the skull, consistent with polyostotic fibrous dysplasia (**FIGURE 2**).

Q: Which is the most likely diagnosis?

- Neurofibromatosis
- Congenital melanocytic nevus
- McCune-Albright syndrome
- Tuberous sclerosis

A: This patient had typical features of McCune-Albright syndrome (or Albright syndrome), the classic triad of fibrous dysplasia of bone, large unilateral café-au-lait macules or patches, and precocious puberty or other endocrinopathy.¹ The syndrome is rare, with an estimated prevalence of 1/100,000 to 1/1,000,000.² It results from somatic mutation of the *GNAS* gene (chromosome 20q13) during embryonic development, which causes constitutive activation of intracellular cyclic adenosine monophosphate (cAMP) signaling and cellular dysplasia.³

■ THE DIAGNOSIS IS CLINICAL

McCune-Albright syndrome is a clinical diagnosis based on the presence of at least two features of the classic triad.^{1,4}

Other conditions, such as neurofibromatosis, also cause café-au-lait macules in children; but the lesions of McCune-Albright syndrome are fewer in number, larger, and darker and may follow Blaschko lines, with a linear or segmental configuration.⁵ McCune-Albright lesions tend to have jagged, “coast-of-Maine” borders, as opposed to the smoother “coast-of-California” borders of the lesions of neurofibromatosis.¹

Nevertheless, because café-au-lait macules of McCune-Albright syndrome are sometimes indistinguishable from those of neurofibromatosis, the endocrine and skeletal manifestations are essential to making the diagnosis.⁵

■ SIGNS OF GENETIC MOSAICISM

The somatic (postzygotic) nature of the *GNAS* mutation means that patients have normal and abnormal cell lines, ie, mosaicism. Therefore, the extent of disease depends on the precise stage in development during which the mutation occurred. This determines which tissues contain mutated cells and the proportion and distribution of affected cells at these loci.^{1,4}

In addition, differential sensitivity to

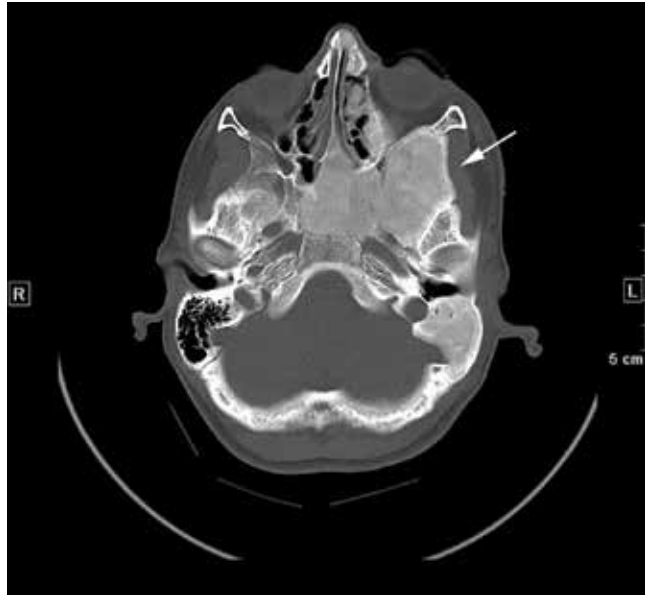


FIGURE 2. Axial computed tomography shows “ground-glass” opacity of the bones at the base of the skull, including the left maxillary sinus, left sphenoid bone, and mastoid portions of both temporal bones (arrow). This is consistent with polyostotic fibrous dysplasia.

cAMP signaling between cell types and tissue-specific imprinting of *GNAS* may contribute to the phenotypic variation seen in McCune-Albright syndrome.⁴ This means that the clinical features often vary, and the classic clinical triad is not always present.⁶

The most common clinical features are fibrous dysplasia, which occurs in 46% to 98% of patients, and café-au-lait macules, which occur in 53.1% to 92.5% of patients.^{1,2} Fibrous dysplasia is typically polyostotic, ie, it involves multiple skeletal sites, with the proximal femur and skull base being the most common.⁶ It presents as bone pain, asymmetry, or pathologic fracture (or a combination of these) and shows a characteristic “ground-glass” appearance on computed tomography (FIGURE 2).¹ Café-au-lait lesions present at birth or shortly thereafter are often unappreciated as a potential presenting sign.¹ These hyperpigmented lesions are typically large and unilateral, often favoring the forehead, nuchal area, sacrum, and buttocks.^{5,6}

Precocious puberty is the most common endocrinopathy in McCune-Albright syndrome, seen in 64% to 79% of cases, and is more common in girls than in boys.² Other

The diagnosis is clinical, based on the presence of at least two features of the classic triad

associated endocrinopathies include hyperthyroidism (20% to 30%), excess growth hormone, renal phosphate wasting, and Cushing syndrome.^{1,6}

■ SCREEN FOR OTHER MANIFESTATIONS

McCune-Albright syndrome can involve a broad spectrum of tissues. Therefore, once the diagnosis is made, the patient should be thoroughly evaluated for other manifestations.¹ The evaluation may include imaging studies and biochemical testing and may necessitate referral to an endocrinologist, a radiologist, and an orthopedic surgeon.

Young girls with premature vaginal bleeding or recurrent follicular cysts should always be evaluated for McCune-Albright syndrome, since ovarian enlargement can be mistaken for an ovarian tumor.⁷ Likewise, adults with isolated fibrous dysplasia or large unilateral café-au-lait macules should also be evaluated, since patients with McCune-Albright syndrome have a normal life span and so may present later in life.^{4,6}

■ TREATMENT

Drug treatment of this syndrome aims to block the effects of prolonged exposure of end-organs to sex steroids. Since precocious puberty of McCune-Albright syndrome is typically periph-

eral in origin, it is unresponsive to gonadotropin-releasing hormone agonist drugs; instead, aromatase inhibitors (testolactone) with antiestrogens (tamoxifen) may be used in girls, or antiandrogens (spironolactone) in boys.⁸

Unfortunately, despite our advanced mechanistic understanding of this disease, medical management remains challenging, with poor long-term efficacy and few studies on long-term outcomes, such as skeletal growth.

■ GENETIC TESTING HAS LIMITED VALUE

Although genetic testing for *GNAS* mutations is available, the mosaic nature of McCune-Albright syndrome makes the detection of mutant alleles in affected tissues and circulating cells exceedingly difficult.^{1,4} These constraints, coupled with high costs, have limited the clinical utility of genetic testing at present. In addition, the lack of a known genotype-phenotype correlation in this syndrome limits the value of genetic testing.¹ In the future, improvements in molecular techniques may make genetic testing more useful in the diagnosis and management of McCune-Albright syndrome, especially if clinically relevant genotype-phenotype correlates are identified.⁴ At this time, although genetic testing is not a standard of care, genetic counseling should be offered to all patients with this syndrome. ■

■ REFERENCES

1. Dumitrescu CE, Collins MT. McCune-Albright syndrome. *Orphanet J Rare Dis* 2008; 3:12.
2. Aycan Z, Önder A, Çetinkaya S. Eight-year follow-up of a girl with McCune-Albright syndrome. *J Clin Res Pediatr Endocrinol* 2011; 3:40–42.
3. Weinstein LS, Shenker A, Gejman PV, Merino MJ, Friedman E, Spiegel AM. Activating mutations of the stimulatory G protein in the McCune-Albright syndrome. *N Engl J Med* 1991; 325:1688–1695.
4. Lietman SA, Schwindinger WF, Levine MA. Genetic and molecular aspects of McCune-Albright syndrome. *Pediatr Endocrinol Rev* 2007; 4(suppl 4):380–385.
5. Bologna JL, Jorizzo JL, Rapini RP, editors. *Dermatology*.

2nd ed. St. Louis, MO: Mosby/Elsevier; 2008.

6. Spitz JL, editor. *Genodermatoses: A Clinical Guide to Genetic Skin Disorders*. Philadelphia: Lippincott Williams & Wilkins; 2005.
7. Nabhan ZM, West KW, Eugster EA. Oophorectomy in McCune-Albright syndrome: a case of mistaken identity. *J Pediatr Surg* 2007; 42:1578–1583.
8. Haddad N, Eugster E. An update on the treatment of precocious puberty in McCune-Albright syndrome and testotoxicosis. *J Pediatr Endocrinol Metab* 2007; 20:653–661.

ADDRESS: Ilene L. Rothman, MD, Women & Children's Hospital of Buffalo, 219 Bryant St., Buffalo, NY 14222; e-mail: irothman@kaleidahealth.org