

## RECURRENT DISLOCATION OF THE PATELLA

JAMES A. DICKSON, M.D.

The subject of slipping or dislocated patella is one regarding which much has been written and it has been discussed on so many occasions that one almost feels that an apology should be offered for an attempt to add anything to what has been said already regarding this condition. However, there are still several controversial points, and it is felt that our personal experience may prove of interest.

Slipping patella is the result of an abnormal laxity of the supporting structures about the knee which permits the occasional displacement of the patella to the outer side of the external condyle of the femur. The underlying predisposing causes may be (1) acquired or traumatic, (2) structural or congenital. The true congenital dislocations are those in which the patella develops away from its normal position and are not considered in this communication.

Trauma may be the original cause of a dislocation of the patella. In such cases, following a severe injury which is accompanied by a rupture of the quadriceps muscle, expansion on the inner aspect of the patella causes the knee to remain insecure, especially on extension against resistance, as for example, in descending stairs. But by far the greater number of dislocations of the patella occur without any such injury and are associated with predisposing structural conditions. The first and most important of these is a genu valgum deformity in which the pull of the quadriceps tends to displace the patella outward. Other such structural conditions may be an underdevelopment of the lateral condyle of the femur, abnormal lateral displacement of the tibial tubercle, relaxation of the capsular ligaments on the inner side of the knee, or of other patellar attachments. The relaxed patellar tendon is a very important predisposing factor in the production of dislocation of the patella. The cases which follow infantile paralysis fall into this group.

Conservative treatment with braces and supports has given temporary relief but has never been successful in effecting a cure.

Many types of operation have been suggested, such as those of Goldthwait, Krogus, Gallie, Soutter, Wagner and Albee. Some of these operations are directed toward the tightening and reinforcement of the relaxed structures on the medial side of the patella. In others, the attempt is made to straighten the direction of the pull of the extensor mechanism, while in Albee's operation the lateral condyle of the femur is raised.

The operation that I have found very satisfactory is based on the principles laid down by the above authors except that I have not found

## RECURRENT DISLOCATION OF THE PATELLA

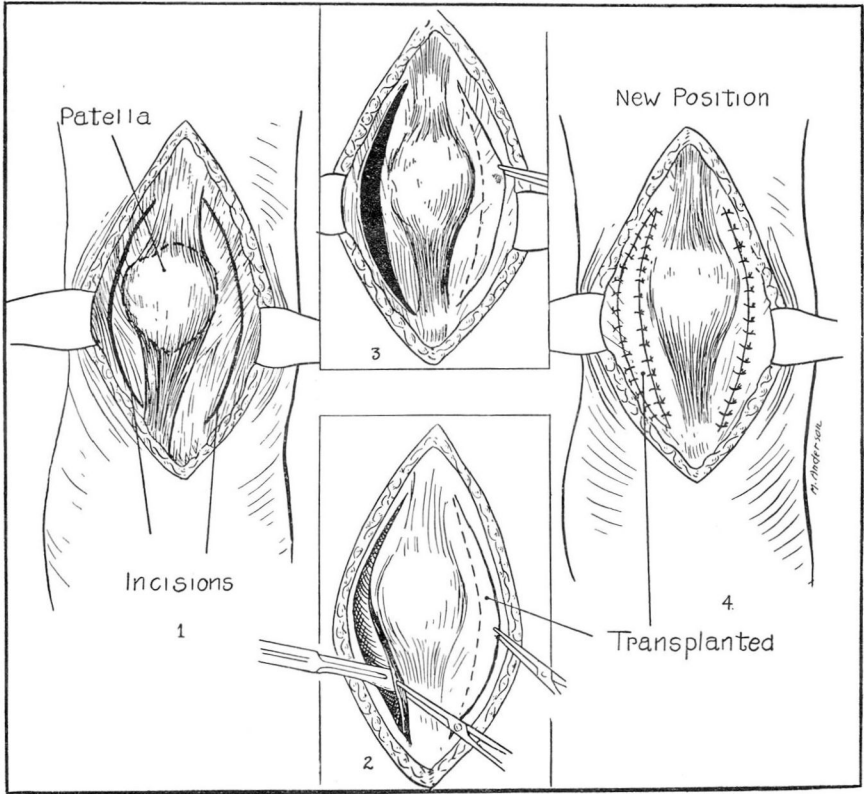


FIGURE 1:1.—Exposure of patella showing the usual lateral attachment of the patellar tendon and the position of incisions in the capsule.

FIGURE 1:2.—Lateral incisions through capsule and freeing of patellar tendon sufficiently to allow proper medial displacement.

FIGURE 1:3.—Extensor apparatus brought into a straight line in order to determine the necessary amount of internal capsule to be excised.

FIGURE 1:4.—Extensor apparatus in proper position and transplanted portion of capsule in place.

it necessary to resort to the Albee operation. The operative treatment is aimed to bring about a condition that will allow the extensor apparatus to pull in a straight line and at the same time will correct the relaxation of the medial capsular ligament.

A tourniquet is applied, a slightly curved incision is made to the inner side of the patellar tendon and the skin and subcutaneous tissues are retracted. The capsule then is divided on both sides of the patella without disturbing the synovial membrane (Fig. 1:1). The patellar tendon is divided with its periosteal attachments and the periosteum is stripped up from the tibia (Fig. 1:2). The patella then is moved inward and the lateral incisions prolonged upward until the extensor apparatus is pulling in a straight line. The patellar tendon is given a

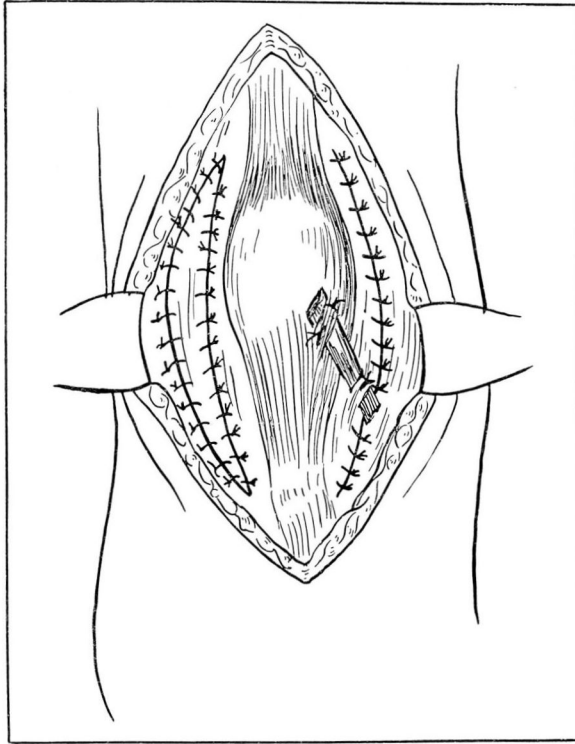


FIGURE 2.—Completed operation when strip of fascia lata is used to reinforce internal lateral ligament.

new attachment medially and is firmly sutured to the periosteum in this position. Enough of the redundant portion of the internal capsule then is excised to hold the patella in its proper position (Fig. 1:3). The excised portion of the capsule is transplanted and used to fill in the defect on the outer side of the joint (Fig. 1:4).

After this stage of the operation is completed, it has been felt advisable in some cases to add a fascial band to support the internal lateral ligament, along the lines advocated by Gallie and by Soutter (Fig. 2). Each of these modifications has been used with satisfactory results. I have not used these operations alone because I felt that it was of paramount importance to correct the mechanical pull of the patellar tendon before all else. When the operation is completed, the tourniquet is removed, and the skin is closed in the usual manner. A plaster of paris cast is applied for a period of three weeks, after which physiotherapy and exercises for the quadriceps are started. The patient is encouraged to walk in about six weeks.

The capsuloplasty operation which I have described has been performed in ten cases. In two cases, the internal lateral ligament was

## RECURRENT DISLOCATION OF THE PATELLA

reinforced with fascia according to the Gallie procedure and in one according to the Soutter method. In two cases of severe knock-knee, the deformity was corrected by osteotomy before the capsuloplasty was done.

The results in all cases have been exceedingly gratifying and there have been no recurrences of the dislocation. It is possible in some of the cases that one of the less radical operations might have proved effective. However, as failures and recurrences are reported by those who have employed the various methods cited above, I feel that the more painstaking operation is warranted.