

MARY K. SAMPLASKI, MD
Glickman Urological and Kidney
Institute, Cleveland Clinic

BRIAN H. IRWIN, MD
Assistant Professor of Surgery, Division
of Urology, University of Vermont College
of Medicine, Burlington, VT

MIHIR DESAI, MD*
Professor of Urology, Institute of Urol-
ogy, University of Southern California,
Los Angeles

Less-invasive ways to remove stones from the kidneys and ureters

ABSTRACT

Less-invasive interventions for upper tract urolithiasis are extracorporeal shock-wave lithotripsy, ureteroscopy, and percutaneous nephrolithotomy. Each has advantages and disadvantages, depending on the location, size, and composition of the stone and on the patient's renal anatomy, body habitus, and comorbidities.

KEY POINTS

Stones that obstruct the flow of urine or that are associated with infection (ie, struvite or "staghorn" stones) should be removed promptly.

For small stones in the distal ureter, medical therapy is an option: pain control, hydration, and control of ureteral spasms with calcium channel blockers and alpha-blockers help the patient pass the stone spontaneously.

Extracorporeal shock-wave lithotripsy is the mostly commonly used option, but it is less effective for large stones and in obese patients.

The ureteroscope can now be used to extract stones as high up as the kidney. Catheters that contain lasers and lithotripsy devices can break up large stones in situ for removal.

Percutaneous nephrolithotomy is very effective for large stones in the kidney and is especially indicated for struvite stones.

*The author has disclosed receiving consulting fees from Baxter and Hansen Medical companies, and owning stock in Hansen Medical.

doi:10.3949/ccjm.76a.09014

VERY FEW PATIENTS UNDERGO surgery for stones in the kidney or ureters anymore, now that less-invasive interventions are available, such as extracorporeal shock-wave lithotripsy, ureteroscopic stone removal, and percutaneous nephrolithotomy. Each of these options has advantages and disadvantages, depending on the characteristics of the stone or stones, such as size, number, location, and composition, as well as patient factors such as renal anatomy, body habitus, and comorbidities.

See related article, page 583

This article reviews the current interventional management of upper tract urolithiasis.

NOT ALL STONES NEED INTERVENTION

From 10% to 15% of people in the United States develop a stone at some point in their life,^{1,2} and this number is increasing.³ Not all of them need intervention (TABLE 1).

In a patient who has symptoms of urinary obstruction or sepsis, the decision to intervene is obvious. Stones that obstruct the flow of urine often cause symptoms due to distension of the ureter, the renal pelvis, or the renal capsule in a relatively predictable and characteristic pattern of pain originating in the flank and often radiating to the groin, testicle, or labia. And untreated struvite ("staghorn") stones, a result of infection, can lead to life-threatening sepsis.

However, in patients with asymptomatic stones, the decision may not be clear-cut. Approximately 32% of patients with asymptomatic renal calculi go on to develop symptoms in the next 2.5 years, increasing to 49% at 5

years.³ Of the patients who develop symptoms, half will require a procedure to remove the stone, while half will pass the offending stone spontaneously.³

If even a small amount of stone is left in the kidney after surgery or other intervention, a large stone can form again, and ultimately, the function of that renal unit can decline. For this reason, most renal calculi should be treated or at least followed for signs of progression with serial imaging studies.

Today, although some patients are followed with kidney-ureter-bladder radiographic studies, most undergo computed tomography, which has the advantages of clearly delineating the stone location and size, the presence of small ureteral stones, and the presence and magnitude of hydronephrosis.

If the patient has no refractory symptoms related to obstruction and no signs of infection or of parenchymal damage, then observation with close follow-up is reasonable. However, infection with urinary tract obstruction, urosepsis, intractable pain or vomiting, acute kidney injury, obstruction in a solitary or transplanted kidney, or bilateral obstructing stones are all indications for urgent intervention.

Additionally, some patients who have asymptomatic stones should undergo evaluation and treatment because of their occupation. Examples are airline pilots and soldiers, in whom an episode of intractable renal colic could prove dangerous.

Stones in women

Women who are pregnant or of childbearing age and have an asymptomatic renal stone are not at any higher risk of stone growth and so should be treated the same as any other patient—except that ultrasonography should be used for imaging to minimize radiation exposure. Urine should be sent for culture. From 50% to 80% of these patients will pass their stones spontaneously with hydration and analgesia.⁴

If intervention is required, percutaneous nephrostomy and placement of ureteral stents can be done to expose the patient to the least possible amount of anesthesia or radiation.⁵

Ureteroscopic stone extraction in pregnant patients has also been shown not to cause pregnancy-related complications, and it entails minimal fluoroscopic exposure.⁶

TABLE 1

Acute management of renal colic

Computed tomography (CT) shows obstruction or hydronephrosis, and the patient has signs of infection (white blood cell count > 15 × 10⁹/L, chills, sweats)

- Admit to hospital
- Give broad-spectrum antibiotics
- Drain kidney via percutaneous nephrolithotomy with ureteral stent
- Take urine culture from renal pelvis

CT shows obstruction or hydronephrosis, but the patient has no signs of infection

- Send home
- Prescribe oral pain medication
- Prescribe an alpha-blocker
- Follow up with a urologist

CT shows no obstruction or hydronephrosis, but the patient has a solitary kidney or persistent pain or vomiting

- Admit to hospital
- Give intravenous fluids at maintenance rate
- Control pain
- Drain kidney if it is solitary

CT shows no obstruction or hydronephrosis, and the patient has two kidneys and no persistent pain or vomiting

- Send home
- Prescribe oral pain medication
- Prescribe an alpha-blocker
- Follow up with a urologist

BASED ON INFORMATION PRESENTED IN PEARLE MS. MANAGEMENT OF THE ACUTE STONE EVENT. AUA UPDATE SERIES 2008; 27:281–291, WITH SOME ADDITIONS BY THE AUTHORS.

Although lithotripsy has been used inadvertently in pregnant patients, its routine use in pregnant patients remains contraindicated.⁷

MEDICAL EXPULSIVE THERAPY

Conservative management, consisting of oral or intravenous hydration and analgesia, can be tried in patients with renal calculi whose condition is otherwise stable. Typically, intravenous hydration is given at a maintenance rate.⁸ Analgesia can be provided with both nonsteroidal anti-inflammatory drugs (NSAIDs) and narcotics, although NSAIDs, in particular ketorolac (Toradol), provide the best pain control.⁹

Calcium channel blockers and alpha-blockers inhibit ureteral spasms and promote the spontaneous passage of ureteral calculi.¹⁰

Compared with hydration alone, nifedipine (Procardia) has been shown to lead to an absolute increase of 9% in stone passage rates, and alpha-blockers have produced an absolute increase of 29%.¹¹ These drugs can be given in conjunction with corticosteroids to reduce ureteral edema, which may contribute to stone retention in the ureter.¹²

As of this date, medical expulsive therapy is well established only for stones in the lower (distal) ureter. The applicability of this treatment for stones in the proximal ureter and kidney is still being investigated. In patients who have stones smaller than 1 cm in diameter and whose symptoms are under control, observation with medical expulsive therapy may well be appropriate. However, after 4 weeks, intervention is indicated, as the risk of complications and renal deterioration increase.

■ STONE SURGERY HAS BECOME RARE

Before the advent of lithotripsy and ureteroscopy (see below), most patients with symptomatic upper tract calculi underwent open surgical lithotomy. Many variations of pyelolithotomy and nephrolithotomy were performed, even bench surgery with autotransplantation (ie, removing the kidney, removing the stone, and then reimplanting the kidney). However, lithotripsy and ureteroscopic extraction have dramatically reduced the role of open stone surgery: it is currently done in only 0.3% to 0.7% of cases.^{13,14}

Laparoscopic surgery for renal calculi is also rarely done. Although almost every type of stone procedure has been done laparoscopically,¹⁵⁻¹⁹ this approach is indicated only in situations in which lithotripsy or ureteroscopic treatment is expected to fail.

■ LESS-INVASIVE OPTIONS

Lithotripsy for small renal stones

Lithotripsy breaks up urinary calculi. In this noninvasive outpatient procedure, a generator creates a shock wave that is propagated toward a fixed focus centered on the stone (FIGURE 1).

Soon after it became available, lithotripsy became immensely popular because of its ability to break up stones without surgery. Ureteroscopic treatment has assumed a bigger role

in recent years because it is more versatile, but lithotripsy remains the most common treatment for urolithiasis.

Advantages, uses. Lithotripsy is generally indicated for renal stones smaller than 2 cm,²⁰ especially those not located in the calyx in the lower pole. It is most effective for stones in the renal pelvis (76% of patients become stone-free), and least effective for stones in the lower pole (59% stone-free).²¹ For this reason, for stones in the lower pole, only those smaller than 1 cm in diameter are treated with lithotripsy.

In the past, lithotripsy was also favored in patients who had stones in the proximal ureter, an area that was technically difficult to access with a ureteroscope. Recent advances in ureteroscope design have all but eliminated this difficulty.

Disadvantages. Lithotripsy can damage nearly any structure in the trajectory of the shock wave, causing bleeding, inflammation, or perforation. It can also cause disturbances in cardiac electrical signal transmission, leading to cardiac arrhythmias during treatment. Long-term concerns include a possible link between lithotripsy and the development of diabetes and hypertension.²² Lithotripsy is contraindicated in pregnancy and coagulopathic states and is less effective in morbidly obese patients.

Lithotripsy is more likely to fail if the skin-to-stone distance is more than 10 mm, if the lower pole forms an acute angle with the ureter, or if the body mass index is greater than 30 kg/m² (ie, if the patient is obese).²³

Percutaneous nephrolithotomy for large or staghorn stones

Percutaneous nephrolithotomy is highly effective for renal calculi but is associated with more complications than lithotripsy or ureteroscopy. It involves inserting a needle through the skin into the renal collecting system and then dilating the tract to approximately 1 cm. Instruments are then inserted through this tract to break up and remove stones. In contrast to laparoscopy, no insufflation is used; the percutaneous tract provides direct access to the kidney for stone removal.

Advantages, uses. Outcomes of percutaneous nephrolithotomy are uniformly favorable

Today,
most patients
with stones
undergo
computed
tomography

Urinary stones: Choice of intervention

In upper-tract urolithiasis, less-invasive interventions have nearly replaced classic lithotomy surgery. The choice of intervention depends on the size, number, and location of the stone or stones, on the type of stone present, and on patient factors.

Percutaneous nephrolithotomy

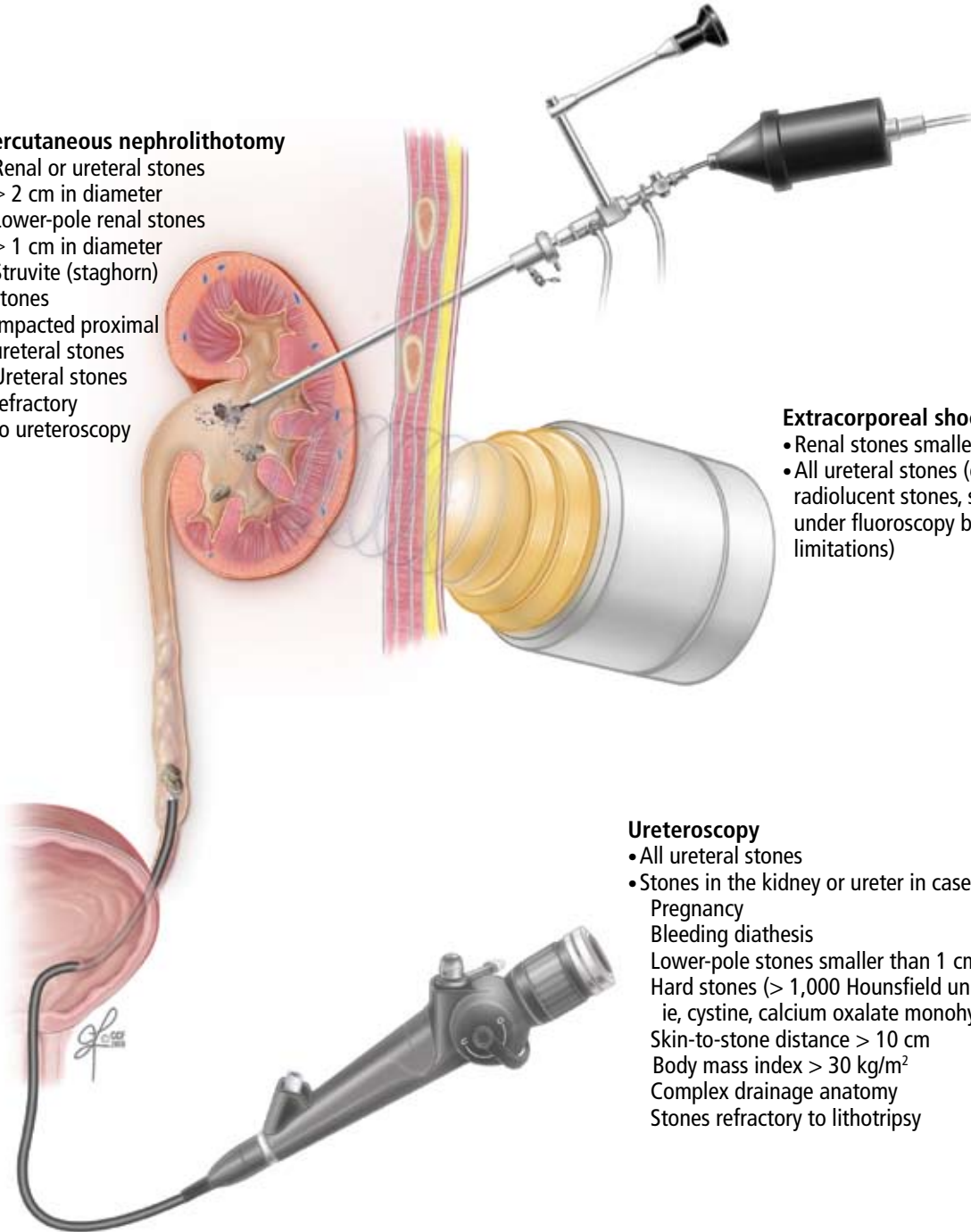
- Renal or ureteral stones > 2 cm in diameter
- Lower-pole renal stones > 1 cm in diameter
- Struvite (staghorn) stones
- Impacted proximal ureteral stones
- Ureteral stones refractory to ureteroscopy

Extracorporeal shock-wave lithotripsy

- Renal stones smaller than 2 cm
- All ureteral stones (except cystine stones, radiolucent stones, stones not visualized under fluoroscopy because of anatomic limitations)

Ureteroscopy

- All ureteral stones
- Stones in the kidney or ureter in cases of:
 - Pregnancy
 - Bleeding diathesis
 - Lower-pole stones smaller than 1 cm
 - Hard stones (> 1,000 Hounsfield units), ie, cystine, calcium oxalate monohydrate
 - Skin-to-stone distance > 10 cm
 - Body mass index > 30 kg/m²
 - Complex drainage anatomy
 - Stones refractory to lithotripsy



CCF
Medical Illustrator: Jeff Loerch ©2009

FIGURE 1

across a wide spectrum of stone sizes, compositions, and locations.

Percutaneous nephrolithotomy is indicated in patients who have renal or ureteral stones larger than 2 cm or lower-pole stones larger than 1 cm (FIGURE 1).^{24,25}

Staghorn stones, commonly associated with infection, lead to renal destruction with significant risk of morbidity and even death if left untreated.²⁶ Because they must be completely removed, which is often difficult or impossible to do with ureteroscopy or lithotripsy, percutaneous nephrolithotomy is the first-line treatment.²⁴

Disadvantages. Percutaneous nephrolithotomy is invasive and carries the associated risks of any major surgical procedure, including sepsis, perirenal hematoma or bleeding, and inadvertent injury to adjacent organs, including the pleurae, lungs, bowel, or spleen.

Ureteroscopy has improved

With improvements in design, stone treatment with flexible and semirigid ureteroscopy have become major options for urinary calculi, even those as far up as the kidney (FIGURE 1).

Advantages, uses. Ureteroscopy offers a low risk of complications (similar to that of lithotripsy), and stone-free rates approach those of percutaneous nephrolithotomy for small to moderate-sized renal stones.^{27,28} Outcomes are best for stones smaller than 1 cm, with residual fragments being seen with larger stones.

New flexible ureteroscopes that deflect up to 270° allow stones in the lower pole to be treated successfully.²⁹ In conjunction with laser lithotripsy, ureteroscopy can be used to successfully treat hard stones (density > 1,000 Hounsfield units), stones in obese patients, and stones refractory to lithotripsy.

Rates of complications and second procedures are low, and, compared with lithotripsy, ureteroscopy takes less time to clear the stone.³⁰ Ureteroscopy can also be used to treat stones in kidneys with complex anatomy, in which poor clearance of fragments may be a problem.²⁸ It may also be used in coagulopathic, pregnant, or morbidly obese patients, in whom lithotripsy or percutaneous nephrolithotomy is less effective or contraindicated.

Disadvantages. Of note, ureteroscopy is a surgical skill, and better outcomes are ob-

tained by surgeons with more experience.³¹

Complications of ureteroscopy include ureteral stricture, perforation, thermal injury, avulsion, intussusception, infection, or steinstrasse (obstruction with fragments of stones). In addition, after ureteroscopy, a temporary ureteral stent is often placed: the stent may cause discomfort and requires a minor adjunctive procedure for removal.

FACTORS THAT AFFECT THE CHOICE OF TREATMENT

Size and location of the stone

The most important predictors of spontaneous passage of ureteral stones are size and location. In general, small stones are more likely to pass spontaneously than large ones, and distal stones are more likely to pass than stones more proximal in the urinary tract.

Stones are typically classified as either ureteral (proximal, middle, or distal) or renal (pelvic or calyceal), depending on their location.

In the ureter. Most ureteral stones smaller than 5 mm in diameter pass spontaneously within 4 weeks of the onset of symptoms.^{25,32} In patients who have stones smaller than 1 cm, whose pain is controlled, and who show no evidence of sepsis or renal insufficiency, a period of observation is a reasonable option.¹¹ Medications such as tamsulosin (Flomax) and nifedipine have been shown to reduce the need for analgesia and to reduce the time to stone passage.^{33,34}

Lithotripsy and ureteroscopy are the two primary interventions for ureteral calculi.

Regardless of size, stones in the ureter can usually be removed by ureteroscopy. This may involve laser or pneumatic lithotripsy within the ureter or simple ureteroscopic basket retrieval of the intact stone. In situ lithotripsy is an option for proximal ureteral calculi and may be favored by patients who wish to avoid placement of a ureteral stent at the time of intervention. Percutaneous nephrolithotomy is reserved for large (> 2-cm) or impacted proximal ureteral stones, or for cases in which ureteroscopy has failed.³⁵

For stones in the proximal ureter, no difference has been shown in stone passage rates between lithotripsy and ureteroscopy. For proxi-

Drug therapy is well established, but only for small stones in the lower (distal) ureter

mal stones smaller than 1 cm, lithotripsy has a higher stone-free rate, and for stones larger than 1 cm, ureteroscopy has been shown to have superior stone-free rates.¹¹

For mid-ureteral and distal ureteral stones of all sizes, ureteroscopy has been shown to have superior stone-free rates, although the difference is statistically significant only for distal stones.¹¹

In the kidney. Large renal stones (> 2 cm) or staghorn calculi within the renal collecting system are best treated with percutaneous nephrolithotomy, whereas renal stones smaller than 1 cm can usually be treated ureteroscopically or with lithotripsy.

Stones within the renal collecting system measuring between 1 and 2 cm in diameter can be treated with ureteroscopy, lithotripsy, percutaneous nephrolithotomy, or a combination, depending on the location and composition of the stone and the wishes of patient.

Stone composition

Cystine stones and calcium oxalate stones are hard, with a density greater than 1,000 Hounsfield units. Lithotripsy has a high failure rate with these types of stones.³⁶

Uric acid stones are softer and do not show up well on x-ray imaging. While it is technically feasible to perform lithotripsy under ultrasonographic guidance, most practitioners prefer to use fluoroscopy to locate the stone. For this reason, patients with radiolucent stones (ie, uric acid stones) are also not good candidates for lithotripsy.

Struvite (staghorn) stones are by defini-

tion infected, with bacteria residing within the stone itself. Thus, it is imperative to remove all stone fragments during treatment to prevent sepsis and stone reformation. Over time, an untreated staghorn calculus will lead to failure of the renal unit.

Although lithotripsy, ureteroscopy, and percutaneous nephrolithotomy can all be used to treat staghorn calculi, percutaneous nephrolithotomy has the best stone-free rate (78%), and lithotripsy has the lowest (54%).²⁴ Therefore, percutaneous nephrolithotomy is recommended as the first treatment for these stones, and if combination therapy is used, then percutaneous nephrolithotomy should be done last to ensure that the stone is completely removed.²⁴ If lithotomy is to be used, drainage of the renal unit must be done in advance with either percutaneous nephrostomy or a ureteral stent, to ensure that all infected stone fragments will be flushed out.²⁴

PREVENTING RECURRENCES

Metabolic abnormalities that increase the risk of urolithiasis can be identified and treated in up to 95% of patients who form recurrent stones.³⁷ Most of these patients require simple dietary modifications, and just 15% require pharmacotherapy. (For more on this topic, see the review by Dr. Phillip Hall in this issue of the *Journal*.³⁸) As urolithiasis is common and often recurrent, the appropriate interventional management, combined with dietary prophylaxis, should minimize patient morbidity and preserve renal function. ■

REFERENCES

1. Sierakowski R, Finlayson B, Landes RR, Finlayson CD, Sierakowski N. The frequency of urolithiasis in hospital discharge diagnoses in the United States. *Invest Urol* 1978; 15:438-441.
2. Norlin A, Lindell B, Granberg PO, Lindvall N. Urolithiasis. A study of its frequency. *Scand J Urol Nephrol* 1976; 10:150-153.
3. Glowacki LS, Beecroft ML, Cook RJ, Pahl D, Churchill DN. The natural history of asymptomatic urolithiasis. *J Urol* 1992; 147:319-321.
4. Denstedt JD, Razvi H. Management of urinary calculi during pregnancy. *J Urol* 1992; 148:1072-1074.
5. Swanson SK, Heilman RL, Eversman WG. Urinary tract stones in pregnancy. *Surg Clin North Am* 1995; 75:123-142.
6. Watterson JD, Girvan AR, Beiko DT, et al. Ureteroscopy and holmium:YAG laser lithotripsy: an emerging definitive management strategy for symptomatic ureteral calculi in pregnancy. *Urology* 2002; 60:383-387.
7. Frankenschmidt A, Sommerkamp H. Shock wave lithotripsy during pregnancy: a successful clinical experiment. *J Urol* 1998; 159:501-502.
8. Springhart WP, Marquet CG, Sur RL, et al. Forced versus minimal intravenous hydration in the management of acute renal colic: a randomized

- trial. *J Endourol* 2006; 20:713-716.
9. Holdgate A, Pollock T. Systematic review of the relative efficacy of non-steroidal anti-inflammatory drugs and opioids in the treatment of acute renal colic. *BMJ* 2004; 328:1401.
10. Hollingsworth JM, Rogers MA, Kaufman SR, et al. Medical therapy to facilitate urinary stone passage: a meta-analysis. *Lancet* 2006; 368:1171-1179.
11. Preminger GM, Tiselius HG, Assimos DG, et al; American Urological Association Education and Research, Inc; European Association of Urology. 2007 Guideline for the management of ureteral calculi. *Eur Urol* 2007; 52:1610-1631.
12. Pearle MS, Calhoun EA, Curhan GC; Urologic Diseases of America Project. Urologic diseases in America project: urolithiasis. *J Urol* 2005; 173:848-857.
13. Matlaga BR, Assimos DG. Changing indications of open stone surgery. *Urology* 2002; 59:490-493.
14. Paik ML, Wainstein MA, Spirnak JP, Hampel N, Resnick MI. Current indications for open stone surgery in the treatment of renal and ureteral calculi. *J Urol* 1998; 159:374-378.
15. Raboy A, Ferzli GS, Ioffreda R, Albert PS. Laparoscopic ureterolithotomy. *Urology* 1992; 39:223-225.

STONE INTERVENTIONS

16. **Winfield HN, Donovan JF, Godet AS, Clayman RV.** Laparoscopic partial nephrectomy: initial case report for benign disease. *J Endourol* 1993; 7:521–526.
17. **Ruckle HC, Segura JW.** Laparoscopic treatment of a stone-filled, caliceal diverticulum: a definitive, minimally invasive therapeutic option. *J Urol* 1994; 151:122–124.
18. **Deger S, Tuellmann M, Schoenberger B, Winkelmann B, Peters R, Loening SA.** Laparoscopic anastrophic nephrolithotomy. *Scand J Urol Nephrol* 2004; 38:263–265.
19. **Harmon WJ, Kleer E, Segura JW.** Laparoscopic pyelolithotomy for calculus removal in a pelvic kidney. *J Urol* 1996; 155:2019–2020.
20. **Abdel-Khalek M, Sheir KZ, Mokhtar AA, Eraky I, Kenawy M, Bazeed M.** Prediction of success rate after extracorporeal shock-wave lithotripsy of renal stones—a multivariate analysis model. *Scand J Urol Nephrol* 2004; 38:161–167.
21. **Lingeman JE, Coury TA, Newman DM, et al.** Comparison of results and morbidity of percutaneous nephrostolithotomy and extracorporeal shock wave lithotripsy. *J Urol* 1987; 138:485–490.
22. **Krambeck AE, Gettman MT, Rohlinger AL, Lohse CM, Patterson DE, Segura JW.** Diabetes mellitus and hypertension associated with shock wave lithotripsy of renal and proximal ureteral stones at 19 years of followup. *J Urol* 2006; 175:1742–1747.
23. **Pareek G, Hedican SP, Lee FT Jr, Nakada SY.** Shock wave lithotripsy success determined by skin-to-stone distance on computed tomography. *Urology* 2005; 66:941–944.
24. **Preminger GM, Assimos DG, Lingeman JE, Nakada SY, Pearle MS, Wolf JS Jr; AUA Nephrolithiasis Guideline Panel.** Chapter 1: AUA guideline on management of staghorn calculi: diagnosis and treatment recommendations. *J Urol* 2005; 173:1991–2000.
25. **Grasso M, Conlin M, Bagley D.** Retrograde ureteropyeloscopic treatment of 2 cm. or greater upper urinary tract and minor Staghorn calculi. *J Urol* 1998; 160: 346–351.
26. **Blandy JP, Singh M.** The case for a more aggressive approach to staghorn stones. *J Urol* 1976; 115:505–506.
27. **Fabrizio MD, Behari A, Bagley DH.** Ureteroscopic management of intrarenal calculi. *J Urol* 1998; 159:1139–1143.
28. **Grasso M, Lang G, Loisesides P, Bagley D, Taylor F.** Endoscopic management of the symptomatic caliceal diverticular calculus. *J Urol* 1995; 153:1878–1881.
29. **Grasso M.** Ureteropyeloscopic treatment of ureteral and intrarenal calculi. *Urol Clin North Am* 2000; 27:623–631.
30. **Peschel R, Janetschek G, Bartsch G.** Extracorporeal shock wave lithotripsy versus ureteroscopy for distal ureteral calculi: a prospective randomized study. *J Urol* 1999; 162:1909–1912.
31. **Anagnostou T, Tolley D.** Management of ureteric stones. *Eur Urol* 2004; 45:714–721.
32. **Segura JW, Preminger GM, Assimos DG, et al.** Ureteral Stones Clinical Guidelines Panel summary report on the management of ureteral calculi. The American Urological Association. *J Urol* 1997; 158:1915–1921.
33. **Pearle MS.** Nifedipine versus tamsulosin for the management of lower ureteral stones. *Int Braz J Urol* 2004; 30:337–338.
34. **Dellabella M, Milanese G, Muzzonigro G.** Medical-expulsive therapy for distal ureterolithiasis: randomized prospective study on role of corticosteroids used in combination with tamsulosin-simplified treatment regimen and health-related quality of life. *Urology* 2005; 66:712–715.
35. **Albala DM, Assimos DG, Clayman RV, et al.** Lower pole I: a prospective randomized trial of extracorporeal shock wave lithotripsy and percutaneous nephrostolithotomy for lower pole nephrolithiasis-initial results. *J Urol* 2001; 166:2072–2080.
36. **Pareek G, Armenakas NA, Fracchia JA.** Hounsfield units on computerized tomography predict stone-free rates after extracorporeal shock wave lithotripsy. *J Urol* 2003; 169:1679–1681.
37. **Straub M, Hautmann RE.** Developments in stone prevention. *Curr Opin Urol* 2005; 15:119–126.
38. **Hall PM.** Kidney stones: formation, treatment, and prevention. *Cleve Clin J Med* 2009; 76:583–591.

ADDRESS: Mary K. Samplaski, MD, Glickman Urological and Kidney Institute, Cleveland Clinic, 9500 Euclid Avenue, Cleveland, OH 44195; e-mail samplam@ccf.org.



Looking for quality CME?
Look no further.



The Cleveland Clinic is proud to be one of the largest providers of online continuing medical education.

Visit our newly redesigned web site to find hundreds of CME offerings in more than **30 medical specialties**. Our new medical news feature provides up-to-the-minute summaries of the day's most significant clinical developments.

We've also updated our popular online medical textbook – The Disease Management Project – with new chapters in 15 specialties.

VISIT OUR SITE TODAY:

www.ClevelandClinicMedEd.com