

FRAGILITAS OSSEUM. BRITTLE BONES AND BLUE SCLERA. HEREDITARY MESENCHYME HYPOPLASIA

B. H. NICHOLS, M. D.

I have seen recently at the Clinic a case which I consider to be a mixed picture of fragilitas osseum, osteitis fibrosa cystica, and Paget's disease, which began with blue sclerotics and brittle bones. I believe this supports the theory that these lesions have a general relative etiology, and the findings in this case demonstrating various stages of the same disease indicate that it is not due to parathyroid disease.

CASE STUDY

The patient was a man 31 years of age when admitted to the Clinic. He had been a normal child until at the age of $7\frac{1}{2}$ years when the skull became abnormal in shape and the left maxilla became enlarged. He had a series of fractures beginning at the age of 17 years, which occurred with slight trauma and continued until the age of 24 years. He broke

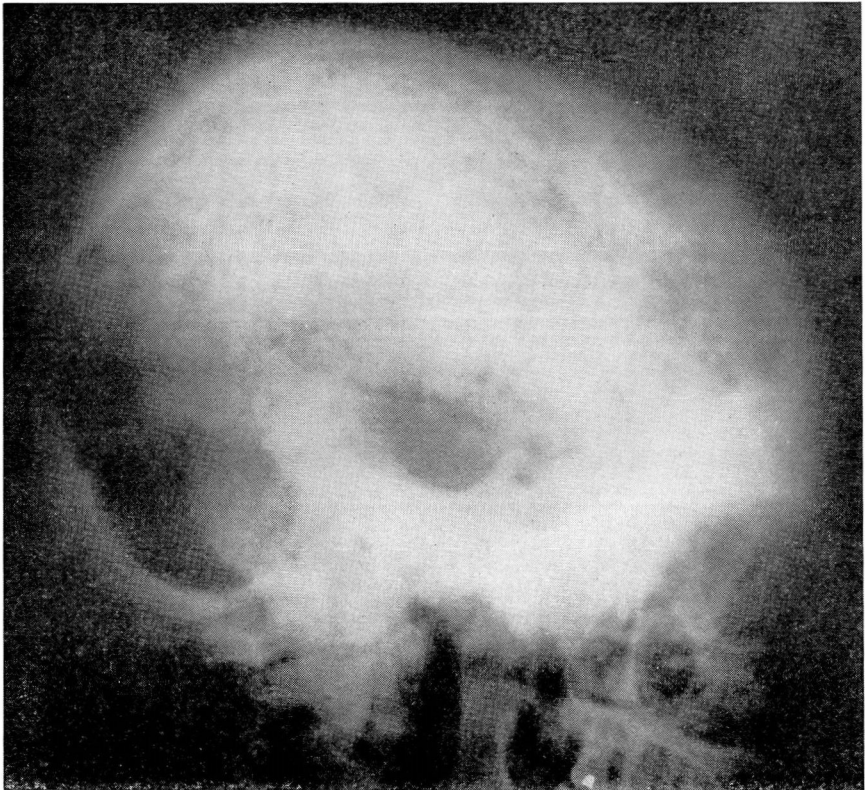


FIGURE 1A. This skull represents the usual findings of a Paget's disease.

FRAGILITAS OSSEUM

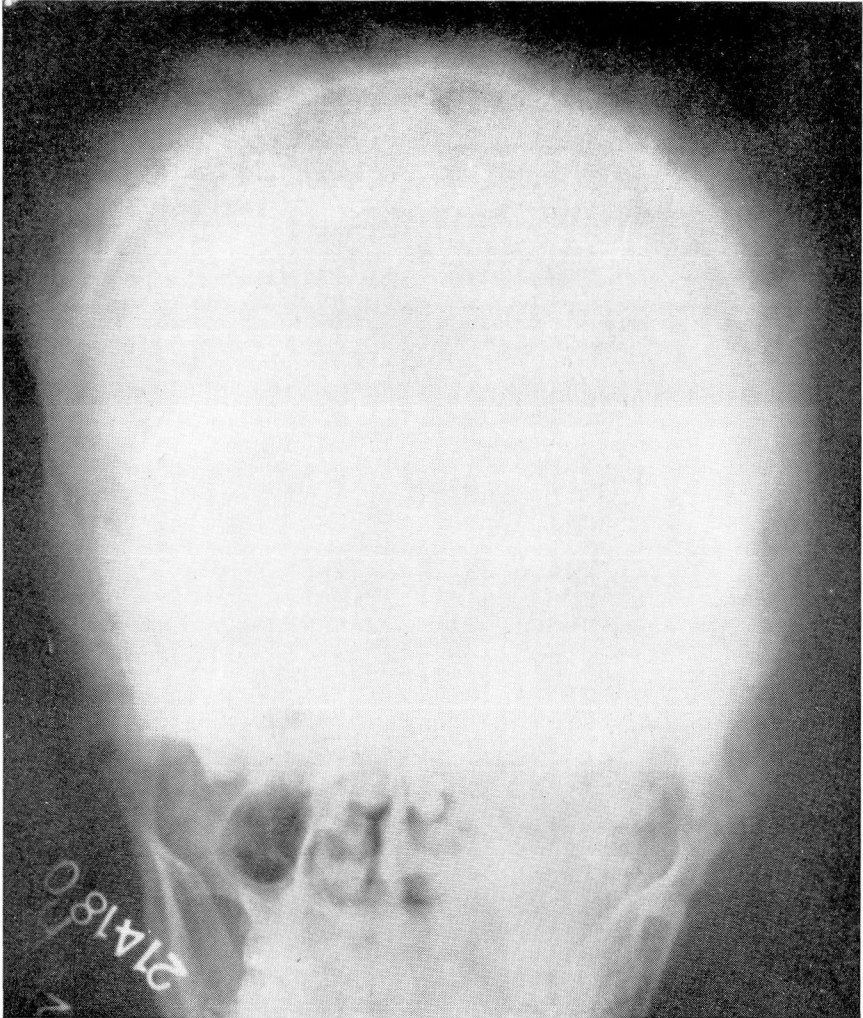


FIGURE 1B. A posterior anterior view of the same skull as in 1A.

ribs by sneezing and putting on his shirt. He fractured the sternum in a friendly boxing bout. He has fractured both clavicles and the right femur by insignificant trauma. He has had pains in the leg and many "painful bones." There has been frequent nasal bleeding.

Physical examination revealed a man 63 inches in height and weighing 122 pounds. He was poorly developed and had blue sclerotics. He had had some dental extractions but the remaining teeth were excellent. There was marked pigeon breast deformity and scoliosis of the right mid-dorsal region. A systolic murmur was heard. The examination of the abdomen gave negative findings. The left maxilla and entire cranium

B. H. NICHOLS

were markedly enlarged, and the patient wore a size 8 hat. There were large parietal bosses. The skull was deformed from left to right and there was marked enlargement of the left mastoid process. Although the joints were freely movable, he had a marked deformity of the fibula due to bony exostosis and lumbar lordosis. The right leg was 4 cm. shorter than the left. Bony exostoses of the left ear canal were present and hearing was diminished in the left ear. The skin showed moderate pigmentation.

Clinical diagnosis: Osteogenesis imperfecta tarda and leukoderma.

Laboratory: Preoperative blood calcium 9.6-13; Phosphorus 1-3. Phosphatase was five times that of normal.

Operation: One parathyroid, which was $2\frac{1}{2}$ times that of normal size, was removed at operation. The remaining parathyroids were normal.

Pathologic sections: Pathologic sections revealed a normal parathyroid.

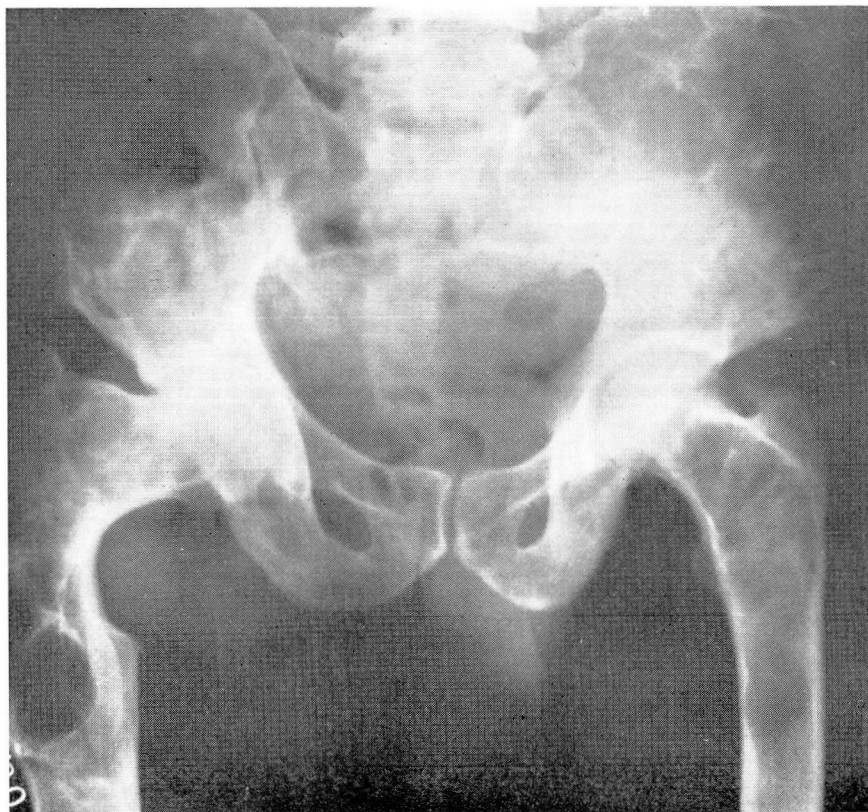

FIGURE 2. The pelvis and upper femurs show the typical cyst formation as seen in osteitis fibrosa cystica. There has been an old pathologic fracture in the upper right femur.

FRAGILITAS OSSEUM

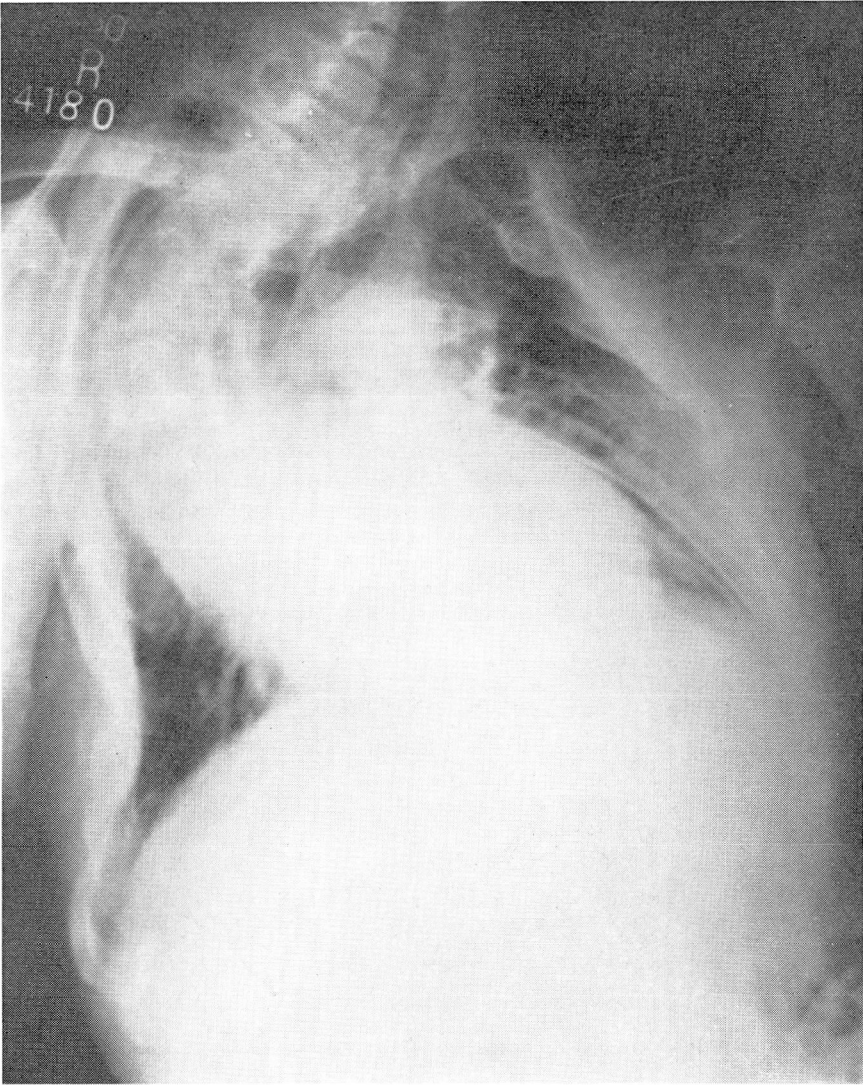


FIGURE 3. The dorsal spine shows marked right dorsal scoliosis, and cystic formation in the ribs.

Convalescence was uneventful except for slight Chvostek's sign which disappeared in three days. On postoperative examination calcium was 8.75. The patient was discharged 8 days after the operation. One month later the blood calcium was 9.6; phosphorus 3.22. The patient was feeling well and stated that he had no pains.

Eight months after the operation the blood calcium was 10.1 mgm.; phosphorus, 3.71 mgm. The patient stated that he was freer of pain and was enjoying better health than ever before. A month after this

visit, nine injections of endocalcium chloride were given intravenously elsewhere. The patient developed pains around the sternum and ribs. However, after cessation of injections the pain subsided but left residual burning around the sternum.

A week later a comparison of roentgenograms showed no advancement of the process although Dr. E. Perry McCullagh thought it apparent that some areas had improved.

A letter received from the patient nearly 10 months following operation stated that he was practically free of pain and fractures since parathyroidectomy.

However, a month after the first communication, another letter from him stated that he had dyspnea and decreased vitality. The blood calcium was 10.1; phosphorus, 3.1. The patient was morbid about his condition, wanted his money back and said his "bones felt as bad as ever." Four months after this, he stated that he had no pains, felt well and had no fractures. Roentgenograms showed no increase in lesions. The calcium was 9.7; phosphorus, 2.27 and phosphatase 4.81 (increased). Then, in three months, a large cystic formation of the left femur developed and he was unable to walk and had severe pain. Cal-

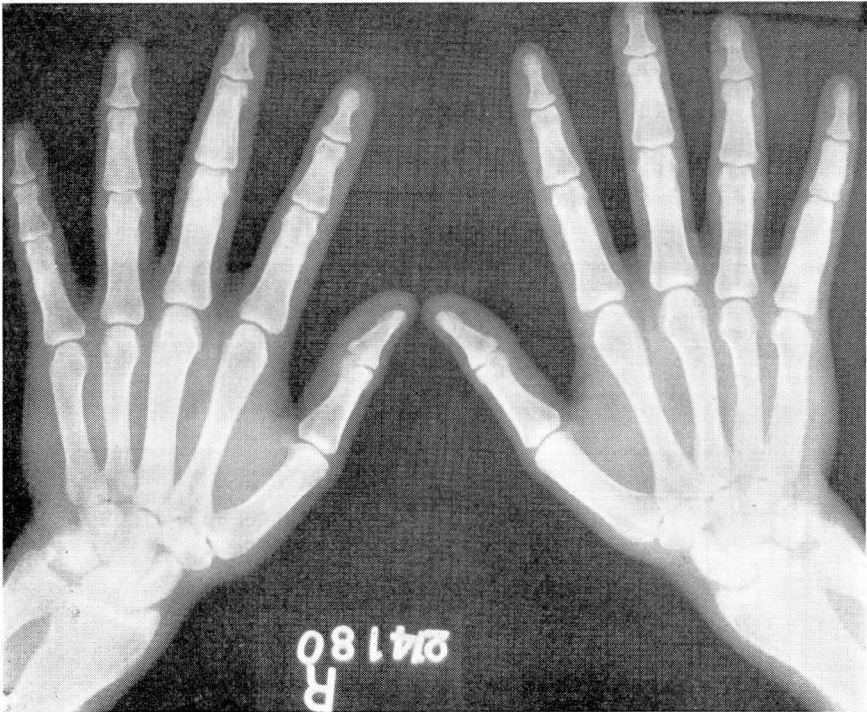


FIGURE 4. The hands which formerly showed considerable generalized malacia are now much improved.

FRAGILITAS OSSEUM

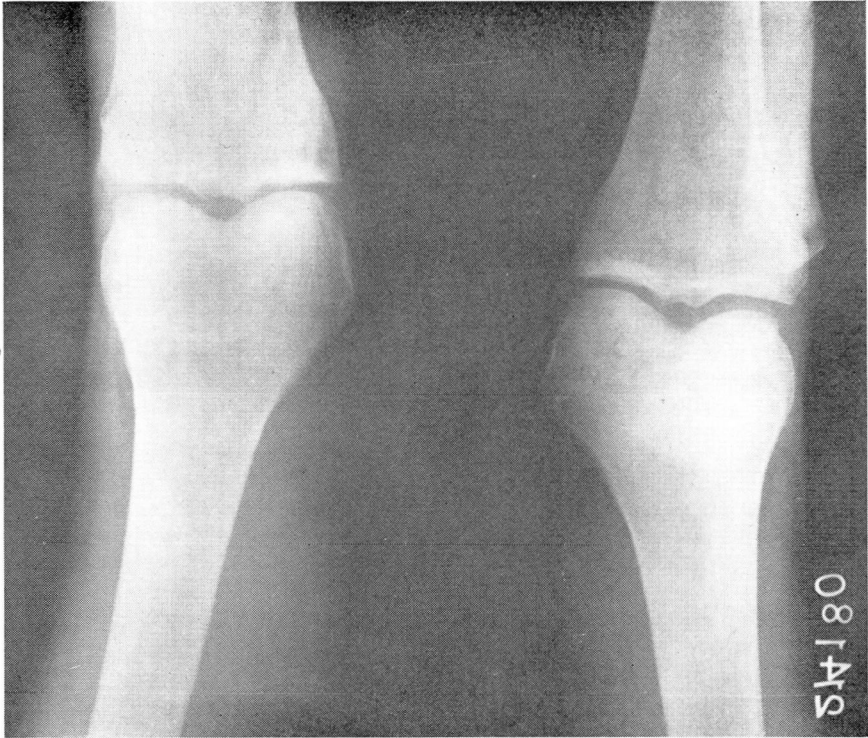

FIGURE 5. There is rarefaction of the malacia type in the bones about the knees.

cium at that time was 9.3 and phosphorus 2.7. Three weeks later the patient was in a wheel chair due to the large cyst of the left femur. Then followed a pathologic fracture which after four months showed very little callus. Eight months after the fracture he was still confined because of it. Phosphatase (Bodanski) was 4.25; calcium 9.2.

The following year exploration of the parathyroids was done but revealed no abnormality. Following this examination, marked improvement was noted in subjective symptoms even though no parathyroid or parathyroid tissue was removed. Fatigability had diminished and pain in the legs disappeared. Roentgenograms showed no change in the bones. Serum calcium was 9.5-12.5; phosphorus 2.9-3.4; phosphatase 21.5-28.2 (Bodanski). The basal metabolism was +7 per cent. Chronaxia was normal with a definite negative calcium balance.

Painless fractures continued with slight trauma until the patient became hopelessly discouraged. Two months after the exploratory operation he broke a rib by lying in an awkward position in bed.

This case was reviewed by Dr. I. Seth Hirsch¹ in which he makes the following comments on the roentgen examination:

“X-ray examinations of this patient have been made at three distinct periods during the past 15 years. In a general way, therefore, it may be stated that the lesions in the metacarpals and phalanges have shown a tendency to repair in the last 15 years and that no new lesions have appeared. In other words, it would appear that the activity of the lesions in the hands had already ceased at the age of 16. This is borne out by a comparative study of the other bones. There is one exception, however—the skull. Here the changes have been progressive.”

In 1913 the following report was made on the cranial bones. They were markedly thickened, especially the frontal and occipital and superior maxillary bones. The differentiation between the tables and the diploe was lost over the frontal area but could be made out in the rest of the bones. The occipital bones, however, showed numerous cystic areas running parallel with the curvature of the bone. The left superior maxillary and the anterior region of the left side was occupied by a bony mass consisting of irregularly formed lamellae of increased density with widened intra-lamellar spaces. The entire base of the skull showed these productive changes.

The sella turcica was very small and its walls were thickened. There was an upward displacement of the posterior portion of the base of the skull, particularly in the region of the foramen magnum. With increasing age, the skull changes in this case progressed until the entire skull was involved, leaving the inner table distinctly clear, but with irregular masses of bone scattered throughout the widely thickened cranial bones. The pelvic bones in 1931 showed cystic areas in both the iliac bones, in the wings, and in the sacral portions. There were large cystic areas in the ischium and pubis without bone expansion, however.

Following a period from 1913 there was considerable increase in extent of the cystic change with little evidence of healing. The patient showed an old oblique fracture at a point two inches below the lesser trochanter with repair in a somewhat deformed position. There had been a pathological fracture through this cystic area, involving the right femur. The spine showed a definite marked lateral curvature with some cystic changes in the vertebrae. The ribs also showed expansion with cystic involvement. The right humerus was involved and extensive cystic changes in the right scapula were noted. Dr. Hirsch comments on the fact that this case is by no means unique and cites references in the literature where a protuberance in the facial or skull bones in young individuals has directed attention to this disease which gradually progresses to complete general bone involvement. His opinion of this case was that it was one of generalized osteitis fibrosa of cystic metaplastic malacia type.

FRAGILITAS OSSEUM

A report recently received from the United States Marine Hospital on Staten Island, New York, makes the following report on this patient. His death occurred in the Marine Hospital eight years after he had first been seen at the Clinic. No necropsy was performed. The cause of death was given in this communication as one of hyperparathyroidism and osteitis fibrosa cystica. This case was followed in the Clinic by Dr. E. Perry McCullagh as a probable case of parathyroid disease with accompanying cystic bone degeneration. I am reviewing this case, however, with the history of early fragile bones and fractures.

The following points might be stressed as in favor of a fragilitas osseum:

1. Normal birth and a normal childhood to 7 $\frac{1}{2}$ years.
2. Blue sclerotics.
3. Exostoses of the middle ear.
4. Osteosclerotic deafness in early adult life.
5. Absence of optic atrophy.
6. Small stature.
7. Easily fractured bones with prompt healing during childhood, the fractures decreasing with age and with increased healing time.
8. Free motility of the joints.
9. Calcification in the vestibular area.
10. Normal range of blood calcium to an increase of calcium to slightly above normal.
11. Eccentric atrophy of the long bones, with slightly striated cortex of these bones.
12. Carpal bones also rarefied with particular rarefaction at diaphyseal ends.
13. Many pathological fractures.
14. No bending of the long bones.
15. Slender ribs.

Points in favor of an osteitis fibrosa cystica are as follows:

1. Thickening of the jaw.
2. A progressive Paget's disease of the skull.
3. Multiple cystic formation.
4. Pains in the legs.
5. Spinal shortening.
6. Disturbed calcium balance.
7. Tendency of the ribs to fracture.

REFERENCE

1. Hirsch, I. Seth: Generalized osteitis fibrosa, *Radiology*, 12:505-516, (June) 1929.