



STEVEN P. MARSO, MD
Department of Cardiology, Cleveland Clinic

STEPHEN G. ELLIS, MD
Department of Cardiology, Cleveland Clinic

RUSSELL RAYMOND, DO
Department of Cardiology, Cleveland Clinic

Intracoronary stenting: An overview for the clinician

ABSTRACT

Intracoronary stenting reduces restenosis rates and effectively treats abrupt vessel closure, two frequent complications following percutaneous coronary angioplasty (PTCA). But it has drawbacks, such as in-stent restenosis, high cost, and lack of long-term follow-up data. This paper discusses current indications and the future role of stenting.

KEY POINTS

Stents provide scaffolding for the vessel wall to prevent abrupt vessel closure and early elastic recoil after PTCA.

Data from small randomized trials and preliminary data from large-scale multicenter trials suggest that primary stenting is efficacious during acute myocardial infarction.

The broad use of stents in a less-select patient cohort—ie, patients with long, complex, or ostial lesions or lesions involving a bifurcation—is not likely to result in such good outcomes as in the original stent trials.

ORIGINALLY DEVELOPED to prevent or treat two major complications (abrupt closure and restenosis) of percutaneous transluminal coronary angioplasty (PTCA), intracoronary stent implantation has come to be employed in over 60% of PTCA procedures performed in more than 700,000 US patients each year. The development of new stent types is a booming business.

Randomized clinical trials show that intracoronary stent implantation is an effective means of preventing and treating abrupt vessel closure and restenosis following balloon angioplasty.^{1,2} But as the use of stents continues to increase and clinical experience with intracoronary stent implantation accumulates, key questions remain:

- Does the risk of complications from intracoronary stenting outweigh the benefits?
- Are the high medical costs of intracoronary stent implantation justified?

In this article we discuss intracoronary stent implantation with respect to complications and issues of concern to primary care clinicians, who are involved in the routine follow-up care of patients who have undergone PTCA procedures, including stent implantation. **FIGURE 1** summarizes the rationale for stent implantation and the current management of its complications.

IMPETUS FOR DEVELOPMENT OF INTRACORONARY STENTS

During percutaneous revascularization with balloon angioplasty, intraluminal balloon inflation causes dissection of the vessel wall. This leads to restenosis in 30% to 50% of



STENTS PROVIDE SCAFFOLDING for the vessel wall to prevent abrupt vessel closure and early elastic recoil after PTCA. Stents are either balloon-delivered or self-expanding and are commonly composed of stainless steel, tantalum, or nitinol (a shape-memory alloy of nickel and titanium). Metals used to make stents are not ferromagnetic and therefore do not interfere with magnetic resonance imaging.

Common stent types include coil, slotted tube, mesh, and ring.

Coil stents are made from a single strand of wire formed into a repeating pattern. These stents are highly flexible, thus improving "trackability" (maneuvering the stent within coronary arteries). Unfortunately, coil stents do not expand uniformly in areas of increased resistance. Therefore, attaining a smooth arterial lumen by predilating with PTCA or debulking with atherectomy devices is important prior to placing a coil stent. Furthermore, the flexibility of coil stents make them more prone to recoil after they are deployed.

Slotted-tube stents such as the Palmaz-Schatz are cut from a single piece of metal and are less flexible than coil stents. As a result, they are less likely to recoil, but they are also less trackable, making them difficult to deploy in a tortuous vessel.

Stainless steel self-expanding mesh stents were among the first stents to undergo clinical evaluation. Mesh stents are made from overlapping wire. They are designed to shorten considerably, and they make access to side branches difficult.

New stents. Development of new stents is evolving rapidly. Currently, the US Food and Drug Administration has approved 10 stents for routine use (GRI, GRII, Palmaz-Schatz, Crown, Multi-link, AVE M2, AVE GFX, Duett, Radius, and Wiktor), and 28 companies manufacture more than 55 stent types (including custom designs). Many more stent types are available for clinical use in Europe than in the United States. Custom-designed stents allow access to lesions that are difficult to treat, such as lesions at a vessel bifurcation and lesions adjacent to a significant side branch artery. Stents with autologous (usually venous) vascular coatings present a novel approach for treating vessel rupture that promotes vessel wall healing.

Researchers are currently exploring the use of stents as a method of local and sustained drug delivery, primarily via other stent coatings such as heparin, fibrin, and biodegradable gel polymers. Although investigation is at an early stage, local drug delivery via endovascular stents appears to be a promising technique.

patients. The mechanism for restenosis is multifactorial and likely results from a combination of elastic recoil of the vessel wall, platelet-mediated thrombus formation, proliferation of smooth muscle cells, and late remodeling. Restenosis following PTCA with balloon angioplasty is frequently associated with myocardial ischemia requiring hospital admission and subsequent revascularization procedures. Abrupt vessel closure occurs in 4% to 10% of patients who undergo PTCA.

Intracoronary stent implantation appears to limit abrupt vessel closure, initial elastic recoil, and late remodeling, leading to improved short-term and long-term vessel patency. On the other hand, stenting does not limit and likely stimulates smooth muscle cell proliferation, leading to vessel renarrowing.

■ CURRENT APPLICATIONS FOR INTRACORONARY STENTING

As is often the case with new interventions, randomized controlled trials of intracoronary stenting have lagged behind clinical applications. But recent data from the Evaluation of Platelet IIb/IIIa Inhibitor for Stenting (EPI-STENT) trial³ narrow this information gap, providing a firmer basis for clinical indications for placing a coronary stent. Current indications and applications for intracoronary stenting include the following:

- Abrupt vessel closure after PTCA ("bailout" stenting)
- De novo lesions in native arteries
- Saphenous vein graft disease
- Prevention of restenotic lesions after PTCA

- Chronic total occlusion
- Acute myocardial infarction.

Abrupt vessel closure: bailout stenting

Abrupt vessel closure, resulting from vessel dissection or early vessel recoil immediately after PTCA, is a catastrophic event that often leads to myocardial infarction and death and requires urgent coronary artery bypass surgery in 30% to 40% of cases.⁴ Now, sufficient data demonstrate that “tacking up” the dissected vessel wall and reestablishing coronary flow by deploying an intracoronary stent in these patients improves outcome compared with PTCA alone.⁵

De novo lesions in native arteries

Four large randomized trials involving more than 3,800 patients have compared elective stenting with PTCA for the primary prevention of restenosis: the Belgian Netherlands Stent Study I (BENESTENT I),¹ the Stent Restenosis Study (STRESS I and II),⁶ Stent vs Angioplasty Restenosis Trial (START),⁷ and Evaluation of Platelet IIb/IIIa Inhibitor for Stenting (EPISTENT) trial.³ The BENESTENT, STRESS, and START trials demonstrated the superiority of stenting in new, short lesions in large (> 3.0-mm) native vessels compared with conventional balloon angioplasty.^{1,3,7} EPISTENT had broader inclusion criteria and represents a more “real world” patient population. Stenting decreased the need for additional revascularization procedures at 6 months in these trials, and a 30% reduction in the angiographic restenosis rate was seen, which translated into a nearly 50% relative reduction in the need for target-vessel revascularization for the group undergoing intracoronary stenting.

Saphenous vein graft disease

Recurrent ischemia following coronary artery bypass grafting is common and poses a difficult treatment problem. The attrition rate for saphenous vein grafts during the first year after bypass surgery is 15%, and by 10 years 50% of vein grafts are occluded. Repeat bypass surgery is technically more difficult and results in a higher perioperative mortality and myocardial infarction rate. Unfortunately, although

PTCA is often initially successful, long-term restenosis and event-free survival rates have been disappointing.⁸

The Saphenous Vein De Novo (SAVED) trial,⁹ a multicenter randomized comparison of Palmaz-Schatz stent placement with balloon angioplasty in vein graft stenosis, demonstrated an improved 6-month event-free survival rate (ie, freedom from myocardial infarction, need for revascularization, or death) for the stent group vs the PTCA group. The combined event rates in the stent and PTCA groups were 24% vs 36%, respectively. The difference in the composite endpoint favoring the stent group was primarily driven by an increased need for repeat revascularization procedures in the PTCA group.

Preventing restenosis after PTCA

Restenosis is a significant shortcoming of PTCA, occurring in 30% to 50% of patients who undergo PTCA.^{10,11} Given the improved outcome of stenting for de novo lesions, the Restenosis Stent trial (REST)¹¹ compared stenting with PTCA in restenotic lesions. Stenting was associated with a decrease in the need for target-vessel revascularization (10% in the stent group vs 27% in the PTCA group) and in the occurrence of angiographic restenosis (18% in the stent group vs 32% in the PTCA group).

Chronic total occlusions

Treatment of chronically occluded vessels with conventional balloon angioplasty is technically difficult: 30% to 50% of blockages cannot be opened initially, and the late failure rate is high due to restenosis. The Stenting in Chronic Coronary Occlusion (SICCO) trial demonstrated an improved event rate for stenting vs PTCA.¹² The improved outcome for stenting was primarily noted in the decreased rate of target-vessel revascularization (22.4% vs 42.4%, respectively).

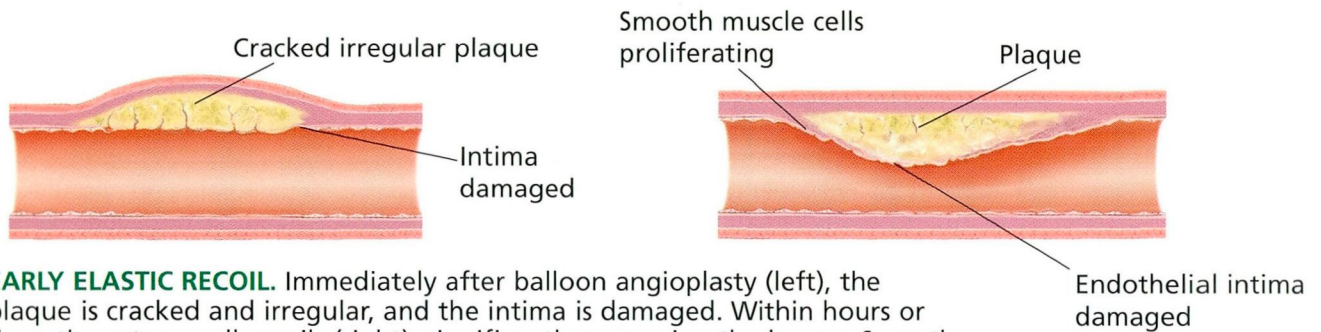
Acute myocardial infarction

Reperfusion therapy after myocardial infarction, whether by fibrinolysis or balloon angioplasty, has been extensively evaluated in randomized controlled trials. Experts were initially concerned about the thrombogenicity of

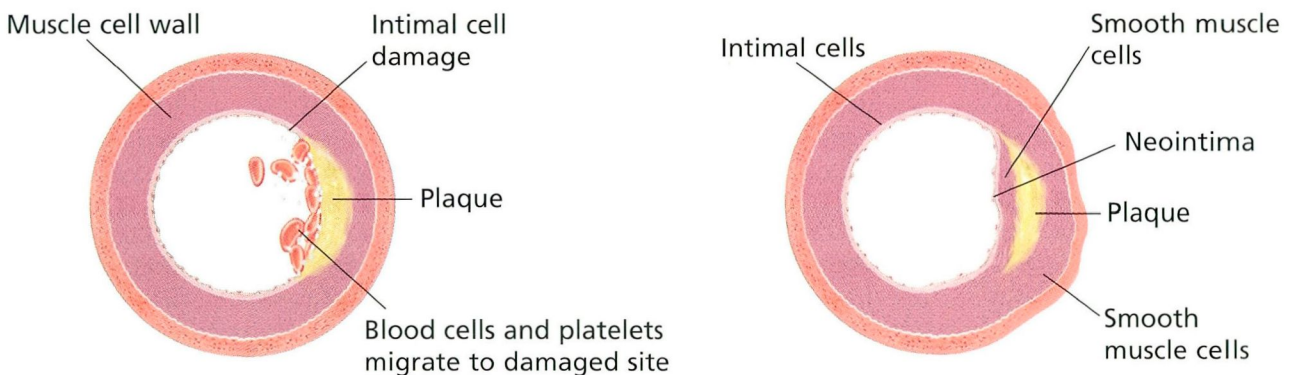
Controlled trials of stents have lagged behind clinical applications



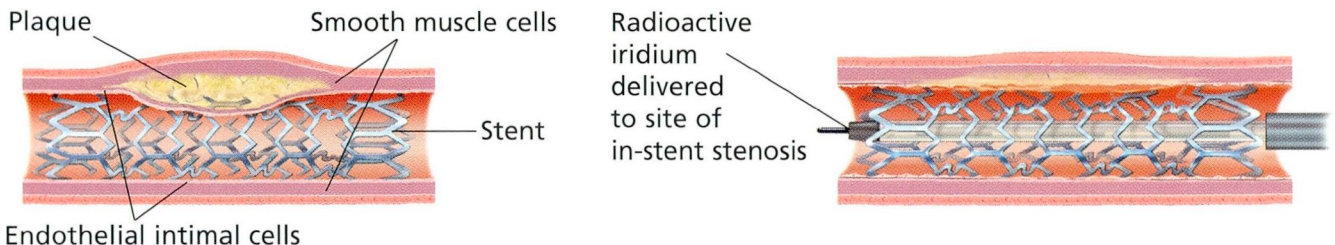
Rationale for intracoronary stent implantation and management of in-stent restenosis



EARLY ELASTIC RECOIL. Immediately after balloon angioplasty (left), the plaque is cracked and irregular, and the intima is damaged. Within hours or days, the artery wall recoils (right), significantly narrowing the lumen. Smooth muscle cells proliferate. The endothelial intima is damaged and incomplete.



LATE REMODELING AND RESTENOSIS. (Left) Later, blood cells and platelets collect at the site of intimal damage. (Right) Smooth muscle cells migrate in, proliferate, and form the neointima.



IN-STENT RESTENOSIS. (Left) Stenting may result in a larger vessel diameter compared with balloon angioplasty alone and may prevent early elastic recoil and late remodeling. But it also causes vessel wall injury, which in turn leads to a proliferation of the neointima at the stenting site. (Right) The ideal revascularization strategy has yet to be determined, but emerging data suggest that radiation therapy involving delivery of iridium-192 directly to the stenting site may reduce in-stent restenosis.

FIGURE 1

stents and the risk of acute coronary syndromes. Recently, however, data from small randomized trials and preliminary data from large-scale multicenter trials suggest that primary stenting is efficacious during acute myocardial infarction.

The Primary Angioplasty in Myocardial Infarction (PAMI) stent trial¹³ randomized 900 patients either to intracoronary stenting with a heparin-coated stent or to primary PTCA within 12 hours of acute myocardial infarction. At 6 months, the stent group had a 20.3% incidence of death, recurrent myocardial infarction, stroke, or target-vessel revascularization vs 32.5% for the PTCA group.¹³

■ SHORTCOMINGS OF STENTING

Although stent implantation has been shown to reduce clinical and angiographic restenosis rates, it has several drawbacks:

- Uncertainty about long-term results
- Subacute thrombosis
- Restenosis within the stent
- High costs.

Other complications are seen with intracoronary stenting, and questions regarding the efficacy of stenting in the “real world” remain unanswered.

Uncertainty about long-term results

Although more than 1 million stents have been placed in patients worldwide, long-term follow-up data are available for only 0.5% of cases. Lesions in STRESS and BENESTENT patients were ideal lesions for stent placement but, unfortunately, account for only 7% to 27% of coronary lesions currently treated.¹ Randomized trials have not yet demonstrated a benefit from stenting in the types of lesions not treated in STRESS or BENESTENT—ie, long, complex, ostial, or involving a bifurcation. Observational data suggest that treating the types of lesions excluded in the original stenting trials would result in nearly a threefold higher need for target-vessel revascularization. Thus, the broad use of stents in a less select patient cohort is not likely to result in similar outcomes as in the original trials.

Subacute thrombosis

With the improvement in stent technology, deployment techniques, and aggressive antiplatelet therapy, acute stent thrombosis is uncommon (< 0.5%). However, subacute thrombosis is more common (0.5%–1.5%). The etiology is as yet undetermined.

Risk factors for subacute thrombosis include residual dissection, failure to take ticlopidine or clopidogrel, complex lesion morphology, overlapping stents, decreased left ventricular ejection fraction, and placement of multiple stents.

Although subacute thrombosis can occur up to 30 days after stent deployment, the majority of events occur within the first 2 weeks. Patients with stent thrombosis often present with recurrent anginal symptoms and dynamic ST segment changes.

Subacute thrombosis after stent placement requires prompt recognition and immediate restoration of coronary flow, ideally via a direct percutaneous technique. Fibrinolytic therapy has not been shown to be of any benefit in subacute thrombosis. Thus, patients with suspected stent thrombosis require urgent angiography and percutaneous restoration of coronary artery patency.

In-stent restenosis

Restenosis within the stent is a problem unique to intracoronary stenting and continues to be very difficult to manage. The restenosis rates in BENESTENT and STRESS were 22% and 31.6% respectively. In-stent restenosis is affected by the following factors:

- History of restenosis
- Presence of multiple stents
- Longer lesion length
- Extensive residual stenosis after stenting
- History of total occlusion
- Diabetes mellitus
- Vessel size less than 3.0 mm.

Assuming stents prevent early elastic recoil and late remodeling effects, neointimal hyperplasia has been implicated as the cause of in-stent restenosis. Stenting results in a larger vessel diameter compared with PTCA. This is at the expense of increased vessel wall injury. It has been postulated that the degree of vessel wall injury correlates with the neointimal response, such that there seems to be

Although stenting reduces abrupt closure and restenosis, it has drawbacks

exaggerated proliferation of the neointima after stenting.

Although it occurs less frequently than after PTCA, restenosis after stenting is difficult to treat. The ideal revascularization strategy has yet to be determined, but emerging data suggest that radiation therapy at the site of intracoronary stenting may improve in-stent restenosis rates. The Scripps Coronary Radiation to Inhibit Proliferation Post Stenting (SCRIPPS) trial¹⁴ randomized 55 patients who had a restenosis after a coronary intervention to either local iridium-192 delivery or placebo. At 6-month follow-up, the radiation group had significantly larger arterial lumen diameters, which resulted in a significant reduction in angiographic restenosis (17% in the iridium-192 group vs 54% in the placebo group).¹⁴

Data from the Washington Radiation for In-Stent Restenosis Trial (WRIST)¹⁵ also support the efficacy of local delivery of low-dose gamma radiation. WRIST demonstrated a significant 78% reduction in the target-vessel revascularization rate.

Although further research is needed into local radiation therapy for the prevention of in-stent restenosis, these initial data are promising. Unfortunately, second-generation stents to date have not been shown to improve the restenosis rates when compared with the reference Palmaz-Schatz stent.

High costs

An important drawback to intracoronary stent implantation is the cost. The average unit price in the United States is over \$1,500. With more than 800,000 stents estimated to have been placed in the US in 1998, this is a \$1.2 billion dollar industry.¹⁶ Although patients undergoing intracoronary stenting in the STRESS trial had lower follow-up medical costs, the medical cost at 1 year for these patients was \$800 dollars greater than for patients who underwent PTCA without stents.

The length of hospital stay after PTCA has shortened, the anticoagulation regimen has been refined, and the efficacy of stent placement has improved. Nevertheless, stent placement today is likely associated with increased cost and utilization of medical resources.

Additional complications

Other complications associated with intracoronary stent placement include major bleeding, vascular injury requiring surgery, embolization, side branch occlusion, perforation of the coronary artery, and (very rarely) infection of the stent.

Bleeding and vascular complication rates have declined with the use of adjuvant therapy. Major bleeding and vascular injury requiring surgery occur in less than 1% of patients not taking warfarin. Identified risk factors for bleeding following percutaneous intervention are age greater than 75 years, female sex, greater than 8F sheath size, duration of procedure, use of heparin following procedure, saphenous vein graft intervention, hypertension, and bailout stenting.¹⁷⁻¹⁹

Embolization of the stent to native coronary arteries can occur if the stent is dislodged from the delivery system, but this is rare. Embolization to the aorta and the iliac and femoral arteries has also been reported.

Side branch occlusion occurs in about 10% of cases when the stent is placed across the ostium of a side branch. The clinical sequelae depend on the amount of myocardium supplied by the branch vessel.

Perforation of the coronary artery is rare (< 1% of patients) but often results in death, myocardial infarction, or emergent cardiac surgery.

Infection associated with placement of a coronary stent is possible but rare. Whether antibiotic prophylaxis should be given following placement of an intracoronary stent is unknown. It seems reasonable that elective surgical procedures (eg, dental, genitourinary) which can cause transient bacteremia should be postponed for 2 to 4 weeks following stent placement.

■ OTHER ISSUES

Interestingly, at the same time stenting has been receiving so much attention for its ability to prevent or correct problems following PTCA, the efficacy of stand-alone PTCA—ie, PTCA without adjunctive stent placement—has been improving.¹

Before stenting was widely available, the tenet that a larger post-PTCA vessel diame-

**The average
stent costs
more than
\$1,500**

ter is associated with a lower restenosis rate was tempered by fear of causing vessel dissection and its sequelae (ie, large myocardial infarction, emergency surgery, death). The availability of stenting as a safety net for treating large intimal dissection (ie, bailout stenting) provided the opportunity to aggressively optimize lumen diameter with PTCA. Furthermore, with the emergence of the platelet glycoprotein IIb/IIIa inhibitor abciximab, the safety and efficacy of stand-alone PTCA have improved.

Substudy analysis from recent trials suggests that aggressive angioplasty results in larger lumen diameters and is associated with improved clinical outcomes. The BENESTENT I trial offered direct evidence of the efficacy of stand-alone balloon angioplasty when "stent-like" (residual stenosis of less than 30%) results are achieved. If patients had stenosis of less than 30% as determined by quantitative angiography, they had a 17% restenosis rate and a 1-year survival rate of 77%, both of which were similar to the outcome of those randomized to the stent arm of this trial.²⁰

Preliminary data from the Optimal Coronary Balloon Angioplasty vs Stent (OCBAS) study involving 116 patients found similar restenosis rates and 6-month target-vessel revascularization rates for the aggressive balloon angioplasty and stent arms.

Given the explosive increase in stenting, the difficult-to-manage problem of in-stent restenosis, the high financial costs associated with stenting, and the improved efficacy of stand-alone PTCA, larger randomized trials comparing stenting with aggressive balloon angioplasty followed by provisional stenting seem warranted.

■ ADJUVANT THERAPY TO PREVENT ACUTE STENT THROMBOSIS

Initial attempts at intracoronary stenting were associated with an unacceptably high rate of acute stent thrombosis: the rate of stent thrombosis in both the BENESTENT and STRESS trials was about 3.5%. Acute stent thrombosis usually occurs within 1 to 2 days of

intervention and often leads to myocardial infarction (in 61% of cases) or death (in 12% of cases).²¹

Adjuvant antiplatelet therapy

Since the initial experience, two changes in clinical practice have resulted in a dramatic decrease in the thrombosis rate. First was the realization that high-pressure balloon inflation results in improved expansion and better approximation of the stent to the arterial wall.²²

Second was the recognition of the importance of antiplatelet therapy following stent deployment.²³ Before this, adjuvant pharmacotherapy had included an aggressive anticoagulation regimen, which resulted not only in high periprocedural bleeding and vascular complication rates, but also in unacceptably high rates of acute thrombosis.

The Stent Anticoagulation Regimen Study (STARS) was a multicenter trial comparing aspirin alone, aspirin and warfarin, and aspirin and ticlopidine after successful placement of a Palmaz-Schatz stent. The subacute thrombosis rate was 3.6% in the aspirin group, 2.7% in the aspirin-warfarin group, and 0.5% in the aspirin-ticlopidine group.²⁴ These are the first data to demonstrate a role for antiplatelet therapy in the prevention of stent thrombosis. Ticlopidine is now given routinely for 2 weeks following stenting and then is discontinued.

The search for the ideal oral antiplatelet therapy for patients undergoing intracoronary stent implantation continues. Ticlopidine was once considered the ideal agent, based on data from large randomized trials. It is efficacious and easy to use. Unfortunately, it is associated with important hematologic dyscrasias. There is a 1.6% incidence of mild to moderate neutropenia and a 0.8% incidence of severe neutropenia (absolute neutrophil count < 450/ μ L or 0.45×10^9 /L). Ticlopidine has also been associated with life-threatening thrombotic thrombocytopenic purpura.

Newer antiplatelet agents are effective and have an improved side-effect profile compared with ticlopidine. Clopidogrel is an antiplatelet agent that inhibits adenosine diphosphate-mediated platelet aggregation. The multicenter Clopidogrel vs

With antiplatelet therapy, the stent thrombosis rate is only 0.5%

Aspirin in Patients at Risk of Ischemic Events (CAPRIE) trial compared clopidogrel vs aspirin in more than 19,000 patients with atherosclerotic vascular disease. Clopidogrel patients had a relative risk reduction of 8.7% for clinical events compared with the aspirin group. Further, there was only a 0.1% incidence of significant reduction in the neutrophil count for clopidogrel patients.²⁵

Whether clopidogrel will prove to be an effective agent in the stent population remains to be determined. However, it appears to be a potent inhibitor of platelet aggregation and has an improved side-effect profile compared with ticlopidine. Although there are trials underway to demonstrate the efficacy of clopidogrel in patients with intracoronary stents, preliminary data have led many experts to substitute clopidogrel, given the adverse effects of ticlopidine.

Platelet glycoprotein IIb/IIIa inhibition

Although stents have decreased the need for target-vessel revascularization after percutaneous revascularization, they have been associated with higher, though not statistically significant, rates of postprocedural myocardial infarction and mortality compared with PTCA in larger trials. In both the Evaluation of 7E3 in Preventing Ischemic Complications (EPIC) trial and the Evaluation of PTCA to Improve Long-term Outcome by c7E3 GPIIb/IIIa receptor blockade (EPILOG) trial, the glycoprotein IIb/IIIa receptor inhibitor abciximab was shown to significantly reduce the rate of events following conventional balloon angioplasty.^{26,27}

In the EPISTENT trial, nearly 2,400 patients were randomly assigned to stenting plus placebo, stenting plus abciximab, or balloon angioplasty plus abciximab. Results demonstrated that abciximab improves the short-term and long-term safety profile of stenting.³ The 30-day postinterventional death and myocardial infarction rates were 10.8% for stent plus placebo, 6.9% for PTCA plus abciximab, and 5.3% for stent plus abciximab. At 6 months the rates were 11.4%, 7.8%, and 5.6%, respectively. As expected, the need for target-vessel revascularization at 6 months was lower in stent patients, regard-

less of the use of abciximab. The target-vessel revascularization rates were 15.4%, 10.8%, and 8.7% for the PTCA-abciximab, stent-placebo, and stent-abciximab groups, respectively.

Diabetes and restenosis after percutaneous intervention. At 6 months, diabetic patients in the stent-abciximab group had less need for target-vessel revascularization than did diabetic patients in the stent-placebo group (8.1% vs 16.6%, respectively). Diabetic patients have consistently been shown to have higher restenosis rates following PTCA compared with nondiabetic patients. In EPISTENT the need for revascularization at 6 months in diabetic patients in the stent-abciximab group was similar to that of nondiabetic patients (8.1% vs 8.8%, respectively). For the first time, diabetic patients had similar outcomes following percutaneous coronary intervention compared with nondiabetic patients.²⁸

Given the findings of EPISTENT, abciximab administration will likely become the standard of care for eligible diabetic patients receiving a stent.

■ FOLLOW-UP SCREENING FOR RECURRENT ISCHEMIA


Whether patients who undergo stent implantation should also undergo routine follow-up noninvasive stress testing is controversial. The rationale for routine assessment stems from the uncoupling of symptoms and restenosis seen in patients after PTCA. In fact, 15% to 60% of patients who have angina before undergoing PTCA tend to present with asymptomatic but positive functional studies and angiographic restenosis.

Assessment even in asymptomatic patients

The Coronary Artery Surgery Study (CASS) demonstrated that patients with ischemia on noninvasive stress testing had a less favorable outcome than patients without ischemia.²⁹ Asymptomatic ischemia did not reduce the risk for the ischemic group. Therefore, an argument can be made for noninvasive risk assessment following stent placement, even in asymptomatic patients. A reasonable approach would be for high-

Routine follow-up noninvasive stress testing is controversial after stent placement



risk patients to undergo routine noninvasive risk assessment 6 months after percutaneous revascularization. Unfortunately, as yet no data demonstrate that revascularization of asymptomatic ischemia improves outcome compared with medical management. 

REFERENCES

1. Serruys PW, de Jaegere P, Kiemeneij F, et al. A comparison of balloon-expandable-stent implantation with balloon angioplasty in patients with coronary artery disease. BENESTENT Study Group. *N Engl J Med* 1994; 331:489-495.
2. Narins CR, Holmes DR, Topol EJ. A call for provisional stenting: The balloon is back. *Circulation* 1998; 97:1298-1305.
3. The EPISTENT Investigators. Randomised placebo-controlled and balloon-angioplasty-controlled trial to assess safety of coronary stenting with use of platelet glycoprotein-IIb/IIIa blockade. Evaluation of Platelet IIb/IIIa Inhibitor for Stenting. *Lancet* 1998; 352:87-92.
4. de Feyter PJ, de Jaegere PP, Serruys PW. Incidence, predictors, and management of acute coronary occlusion after coronary angioplasty. *Am Heart J* 1994; 127:643-651.
5. Ray SG, Penn IM, Ricci DR, et al. Mechanisms of benefit of stenting in failed angioplasty. Final results from the Trial of Angioplasty and Stents in Canada (TASC II) [abstract]. *J Am Coll Cardiol* 1995; 25(suppl A):156A.
6. Fischman DL, Leon MB, Baim DS, et al. A randomized comparison of coronary-stent placement and balloon angioplasty in the treatment of coronary artery disease. Stent Restenosis Study Investigators. *N Engl J Med* 1994; 331:496-501.
7. Masotti M, Serra A, Fernandez-Aviles F, et al. Stent versus angioplasty restenosis trial (START). Angiographic results at 6-month follow-up [abstract]. *Eur Heart J* 1996; 17:120A.
8. de Feyter PJ, van Suylen RJ, de Jaegere PP, Topol EJ, Serruys PW. Balloon angioplasty for the treatment of lesions in saphenous vein bypass grafts. *J Am Coll Cardiol* 1993; 21:1539-1549.
9. Savage MP, Douglas JS Jr, Fischman DL, et al. Stent placement compared with balloon angioplasty for obstructed coronary bypass grafts. Saphenous Vein De Novo Trial Investigators. *N Engl J Med* 1997; 337:740-747.
10. Califf RM, Fortin DF, Frid DJ, et al. Restenosis after coronary angioplasty: an overview. *J Am Coll Cardiol* 1991; 17:2B-13B.
11. Erbel R, Haude M, Hopp HW, et al. Coronary-artery stenting compared with balloon angioplasty for restenosis after initial balloon angioplasty. *N Engl J Med* 1998; 339:1672-1678.
12. Sirnes PA, Golf S, Myreng Y, et al. Stenting in Chronic Coronary Occlusion (SICCO): A randomized, controlled trial of adding stent implantation after successful angioplasty. *J Am Coll Cardiol* 1996; 28:1444-1451.
13. Stone GW, Brodie BR, Griffin JJ, et al. Prospective, multicenter study of the safety and feasibility of primary stenting in acute myocardial infarction: In-hospital and 30-day results of the PAMI stent pilot trial. *J Am Coll Cardiol* 1998; 31:23-30.
14. Teirstein PS, Massullo V, Jani S, et al. Catheter-based radiotherapy to inhibit restenosis after coronary stenting. *N Engl J Med* 1997; 336:1697-1703.
15. Waksman R, White LR, Chan RC, et al. Intracoronary radiation therapy for patients with in-stent restenosis: 6-month follow-up of a randomized clinical study [abstract]. *Circulation* 1998; 98:3421-A.
16. Wohl V. Merrill Lynch & Company Health-Medical Technology Report: Boston Scientific Corporation, 1998.
17. Oweida SW, Roubin GS, Smith RB, Salam AA. Postcatheterization vascular complications associated with percutaneous transluminal coronary angioplasty. *J Vasc Surg* 1990; 12:310-315.
18. McCann RL, Schwartz LB, Pieper KS. Vascular complications of cardiac catheterization. *J Vasc Surg* 1991; 14:375-381.
19. Muller DW, Shamir KJ, Ellis SG, Topol EJ. Peripheral vascular complications after conventional and complex percutaneous coronary interventional procedures. *Am J Cardiol* 1992; 69:63-68.
20. Serruys P, Azar A, Sigwart U, et al. Long-term follow-up of 'stent-like' (< 30% diameter stenosis post) angioplasty; a case for provisional stenting [abstract]. *J Am Coll Cardiol* 1996; 27:15A.
21. Mak KH, Belli G, Ellis SG, Moliterno DJ. Subacute stent thrombosis: evolving issues and current concepts. *J Am Coll Cardiol* 1996; 27:494-503.
22. Colombo A, Hall P, Nakamura S, et al. Intracoronary stenting without anticoagulation accomplished with intravascular ultrasound guidance. *Circulation* 1995; 91:1676-1688.
23. Kastrat A, Schuhlen H, Hausleiter J, et al. Restenosis after coronary stent placement and randomization to a 4-week combined antiplatelet or anticoagulant therapy: six-month angiographic follow-up of the Intracoronary Stenting and Antithrombotic Regimen (ISAR) Trial. *Circulation* 1997; 96:462-467.
24. Leon MB, Baim DS, Popma JJ, et al. A clinical trial comparing three antithrombotic-drug regimens after coronary-artery stenting. *N Engl J Med* 1998; 339:1665-1671.
25. CAPRIE investigators. A randomised, blinded, trial of clopidogrel versus aspirin in patients at risk of ischaemic events (CAPRIE). CAPRIE Steering Committee. *Lancet* 1996; 348:1329-1339.
26. The EPIC Investigators. Use of a monoclonal antibody directed against the platelet glycoprotein IIb/IIIa receptor in high-risk coronary angioplasty. *N Engl J Med* 1994; 330:956-961.
27. The EPILOG Investigators. Platelet glycoprotein IIb/IIIa receptor blockade and low-dose heparin during percutaneous coronary revascularization. *N Engl J Med* 1997; 336:1689-1696.
28. Marso SP, Tanguay JF, Bhatt DL, et al. Optimizing the percutaneous coronary interventional strategy for diabetics—The EPISTENT experience [abstract]. *Circulation* 1998; 98:400A.
29. Weiner DA, Ryan TJ, Parsons L, et al. Prevalence and prognostic significance of silent and symptomatic ischemia after coronary bypass surgery: A report from The Coronary Artery Surgery Study (CASS) randomized population. *J Am Coll Cardiol* 1991; 18:343-348.

ADDRESS: Steven P. Marso, MD, Department of Cardiology, F25, The Cleveland Clinic Foundation, 9500 Euclid Avenue, Cleveland, OH 44195, e-mail marso@clevelandclinic.org.