Percutaneous gasserian thermocoagulation in the treatment of trigeminal neuralgia

Russell W. Hardy, Jr., M.D.
Department of Neurological Surgery

Although percutaneous trigeminal thermocoagulation was first employed in the treatment of tic douloureux in Europe prior to World War II,[1] the first major series of cases was not reported in the United States until 1974.[2] Since that time, the procedure has gained increasing acceptance as a safe and effective treatment for trigeminal neuralgia.

We are reporting a series of 53 patients treated at the Cleveland Clinic in the past 3 years.

Procedure

The technique used at the Cleveland Clinic is similar to that employed by Sweet and Wepsic,[2] although modifications of this technique have been described.[3–6] The procedure is carried out with a combination of fentanyl and sodium methohexital (Brevital) anesthesia. The patient is first sedated with 0.05 to 0.1 mg of fentanyl, and then at critical points in the procedure is further anesthetized with 30 to 50 mg of sodium methohexital. We have administered as much as several hundred milligrams of sodium methohexital in divided doses during the procedure. Major discomfort occurs during the introduction of the radio-frequency electrode through

the foramen ovale, and later during thermocoagulation of the ganglion. In our experience, this combination of anesthetics produces a maximum degree of comfort, yet allows the patient to be awakened periodically to test the results of stimulation and lesion making.

After the patient is prepared and anesthetized, a radio-frequency thermister electrode (Radionics Inc., Burlington, Massachusetts) is passed through the foramen ovale. The electrode is first introduced into the cheek, and aimed at a point somewhat medial to the mid-position of the pupil and toward a point 4 cm anterior to the external auditory meatus on the orbito-meatal line (*Fig. 1*). The electrode is slid beneath the mucosa of the oral cavity to the mandible and then to the base of the skull. One finger should be kept with the oral cavity to insure that the point of the electrode does not penetrate the mucosa and become contaminated.

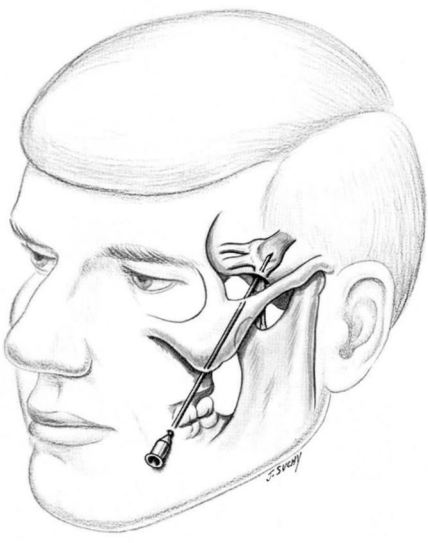

Fig. 1. The radio-frequency electrode is passed from the cheek through the foramen ovale.

After the base of the skull has been reached, lateral and base view roentgenograms are obtained. When the relation of the electrode tip to the foramen ovale has been verified, appropriate corrections can be made and the electrode introduced through the foramen. At this point further roentgenograms are made to verify the intracranial position of the electrode (*Figs. 2 and 3*). It is desirable but not absolutely necessary that cerebrospinal fluid (CSF) be obtained from the electrode; the presence of CSF strongly suggests that the electrode tip is properly situated in the ganglion. The absence of CSF does not necessarily contraindicate lesion making, particularly when the procedure is being performed on a patient who has undergone prior intracranial surgery.

After the intracranial position is confirmed by roentgenography, stimulation is carried out to verify the position of the electrode. The appearance of paresthesias in the appropriate trigeminal division at 0.1 to 0.4 volts suggests a good electrode position. Conversely, if paresthesias are not produced at 0.5 volts or more, the position of the electrode may need to be changed. *Figure 4* shows that the third division is reached most anteriorly and laterally, and as the electrode is advanced posteriorly and medially, the second and then the first divisions are then encountered. We have found that stimulation rather than roentgenography or localization is the most critical indicator in determining adequacy of electrode placement.

After proper electrode placement, sequential coagulations of the gan-

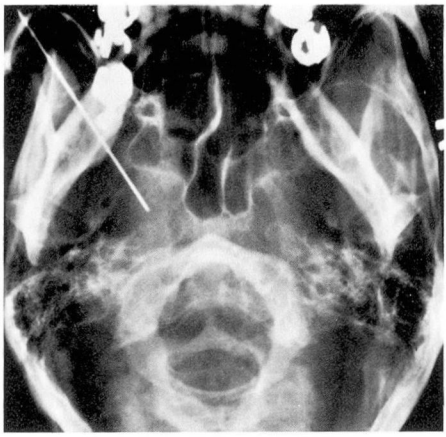

Fig. 2. Base view roentgenogram of the electrode position.

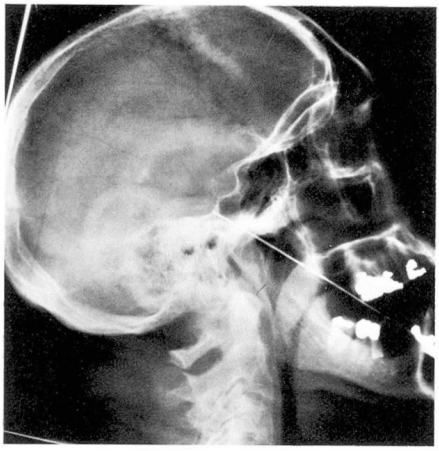

Fig. 3. Lateral roentgenogram of the electrode position.

glion are carried out, using electrode tip temperature as a guide to the adequacy of the lesion. There is some variability in the temperature which will produce an adequate lesion. In general, lesions above 70 C tend to produce more objective sensory loss and insure elimination of the pain. However, in some patients an adequate lesion may be produced by a temperature as low as 65 C. Lesions with minimal sensory loss may be desirable in certain patients. It is thought that there may be a greater chance of recurrence if less objective sensory loss is produced. It is important, however, to produce the lesions sequentially, gradually raising the temperature and checking the patient in the interval between each lesion to detect the onset of loss of pinprick sensation. In general, the time required to produce each lesion is 60 seconds, but in an occasional patient, when it is difficult to raise the tip temperature, a longer time may be required.

An important clue to accuracy of needle placement is the appearance of a "flush" in the appropriate division of the nerve. This does not always occur, but when it does it is an important guide to adequacy of coagulation.

Normally, relief of pain occurs promptly following surgery. If any doubt exists as to the adequacy of the lesion, it is better to wait and repeat the lesion if the tic douloureux actually recurs. Usually the patient can be discharged the day following surgery.

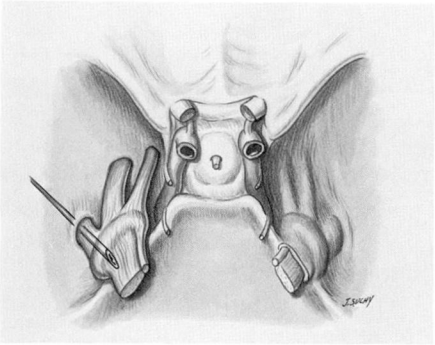

Fig. 4. The electrode passes from lateral to medial in the gasserian ganglion and encounters the third, and then the second and first divisions of the trigeminal nerve.

Results

Between November 1973 and January 1977, 53 patients underwent trigeminal coagulation for tic douloureux. In addition, two patients had trigeminal pain secondary to multiple sclerosis and one had facial pain from carcinoma.

The location of the trigeminal pain is shown in *Table 1*. Of the 53 patients, 30 had had no previous surgical treatment, and an additional 10 had had treatment with either peripheral alcohol block or peripheral neurectomy. Thirteen patients had undergone one or more prior intracranial procedures and are considered a separate group.

Of the patients with either no prior treatment or for whom treatment was limited to peripheral procedures, 90% were considered as having good results (*Table 2*). The patients in the fair or poor category were actually relieved of tic douloureux but are considered as having less favorable results because of the presence of paresthesias following the procedure.

Treatment was less successful in those patients who had undergone prior intracranial surgery. Nine of these 13 were relieved of tic pain, but four were considered as having poor results. Of these, three were considered as having poor results because it was not possible to achieve a satisfactory lesion and relieve their pain. One was considered as having a poor result because of postoperative paresthesias.

When all patients are considered as a group (*Table 3*), 45 of the 53 (85%) were relieved of pain and pleased with the result. Two patients (4%) were considered as having fair results because of minor paresthesias, even though they were relieved of pain.

Table 1. Location of trigeminal neuralgia

	No. of patients
V_1	1
V_2	13
V_3	9
V_2V_3	19
V_1V_2	6
$V_1V_2V_3$	5

Table 2. No prior intracranial surgery

No. of patients	Percent	Result
36	90	Good
2	5	Fair
2	5	Poor
40		

Table 3. Percutaneous thermocoagulation in 53 patients

No. of patients	Percent	Result
45	85	Good
2	4	Fair
6	11	Poor
53		

Six of the 53 (11%) were considered as having poor results, because either the procedure failed (3) or severe paresthesias were present (3).

In five patients, early repeat procedures were required to achieve a satisfactory lesion. In certain patients, a repeat procedure is actually anticipated. This is because we feel that the optimal lesion is one which produces minimal sensory loss. Thus, in a few patients, when at operation doubt exists whether an adequate lesion has been produced, it is our practice to discontinue the procedure and repeat it if postoperative observation reveals that the tic douloureux has not been eliminated. Of the total number of patients in the series, four have had late recurrences and required repeat procedures.

Complications of the procedure

Table 4. Complications of percutaneous coagulation

	No. of patients
Anesthesia dolorosa	3
Keratitis	1
Decreased corneal reflex	21
Minor paresthesias	5
Bilateral analgesia	1

are listed in *Table 4*. There have been no deaths in this series and no instance of serious neurologic deficit. The most serious complication is anesthesia dolorosa, which has been noted in three patients. This complication has also been observed in patients who have undergone operative section of the nerve. Minor paresthesias which did not disable the patient were noted in five. Decreased corneal reflex, noted in 21 patients, was not a serious deficit except in one patient in whom a corneal ulcer ultimately developed which was successfully treated.

The patient with bilateral analgesia had previously undergone surgical section of the contralateral trigeminal nerve for tic douloureux. We have no instance of extraocular muscle palsy and no instance of puncture of the carotid artery, complications which have been reported elsewhere.[2, 5]

Of the two patients with multiple sclerosis, one patient had a good result, but pain recurred in the other patient despite repeat procedures. The patient with intractable pain from carcinoma had only short-term relief.

Summary

Our experience suggests that percutaneous trigeminal thermocoagulation is an effective and safe treatment of trigeminal neuralgia. It has a success rate of 90% in previously untreated patients, and is effective even in those patients who have undergone prior intracranial surgery. An open surgical procedure is avoided and there is a relatively low complication rate.

References

1. White JC, Sweet WH: Pain and the Neurosurgeon; a Forty-Year Experience. Springfield, Ill, Thomas, 1969.
2. Sweet WH, Wepsic JG: Controlled thermocoagulation of trigeminal ganglion and rootlets for differential destruction of pain fibers. Part 1: Trigeminal neuralgia. J Neurosurg **40:** 143–156, 1974.
3. Nugent GR, Berry B: Trigeminal neuralgia treated by differential percutaneous radiofrequency coagulation of the Gasserian ganglion. J Neurosurg **40:** 517–523, 1974.
4. Onofrio BM: Radiofrequency percutaneous Gasserian ganglion lesions. J Neurosurg **42:** 132–139, 1975.
5. Tator CH, Rowed DW: Fluoroscopy of foramen ovale as an aid to thermocoagulation of the Gasserian ganglion; technical note. J Neurosurg **44:** 254–257, 1976.
6. Voris HC, Whisler WW: Treatment of Pain. Springfield, Ill, Thomas, 1975, p 61.