

Meniscal Root Tears: Identification and Repair

David B. Doherty, MD, and Walter R. Lowe, MD

Abstract

Intact menisci are capable of converting the axial load of tibiofemoral contact into hoop stress that protects the knee joint. Total meniscectomy leads to rapid degeneration of the knee. Strong clinical and biomechanical data show meniscal root tears and avulsions are the functional equivalent of total meniscectomy. Lateral root tears commonly occur with knee ligament sprains and tears. Medial root tears are generally more chronic, and can be caused by preexisting knee arthritis. Meniscal root repair is indicated when there is identification of a meniscal root tear in a knee with

minimal to no arthritis. Chronic root tears in the setting of osteoarthritis are treated conservatively. Meniscal root tears can acutely occur with cruciate ligament tears, can exaggerate symptoms of instability, and will have negative ramifications on outcomes of anterior cruciate ligament reconstruction if not addressed concomitantly. In this review, we describe the importance of the menisci for knee joint longevity through anatomy and biomechanics, the diagnostic workup, and ultimately a transosseous technique for repair of meniscal root tears and avulsions.

Intact and well functioning menisci are essential for optimal knee function. Articular cartilage damage and rapid joint degeneration have been observed in knees after meniscectomy.¹⁻⁵ Meniscal root tears and avulsions are now increasingly recognized as a functional equivalent to total meniscectomy, and will follow a similar course if left untreated.⁶⁻⁸

The menisci provide shock absorption and stability through their unique anatomy and physiology. Their essential role in dissipation of the axial load encountered during daily activities is accomplished via generation of circumferential hoop stress.^{4,5,9} Tears of the horn or body may diminish this ability depending on the size and location, but a tear or an avulsion that renders the root incompetent will leave the meniscus unable to generate hoop stress.¹⁰ Likewise, as the menisci have been shown to be important secondary stabilizers for both translation and rotation, this function is lost or significantly diminished in the setting of a root tear.^{6,11,12}

Despite their clinical and biomechanical implications, meniscal root tears can be difficult to identify, particularly when they are not actively

sought. The goal of this article is to highlight the current diagnostic workup and treatment in patients with suspected meniscal root pathology. We will also aim to emphasize important anatomic and biomechanical considerations when attempting a meniscal root repair.

Anatomy

The menisci are 2 fibrocartilage wedge-shaped structures that surround the medial and lateral tibial plateau's weight-bearing surfaces. They are attached at many points along their periphery via coronary ligaments that comprise a continuous junction of the meniscus to the capsule to the tibial plateau. Each meniscus has an anterior and a posterior horn that are securely anchored to the tibial intercondylar region via strong ligaments known as the roots.

The anterior medial root attaches just anterior and medial to the medial tibial spine. The anterior lateral root attaches just anterior to the lateral tibial spine. The medial and lateral anterior horns of the menisci are also connected via the anterior intermeniscal ligament (AIML).¹³⁻¹⁵ Recent cadaveric biomechanical studies have questioned

Authors' Disclosure Statement: The authors report no actual or potential conflict of interest in relation to this article.

the importance of the AIML, demonstrating no significant change in contact pressure or area before and after sectioning.¹⁶ Another important consideration with respect to the anterior root insertion of the lateral meniscus is its intimate relationship with the tibial insertion of the anterior cruciate ligament (ACL). The anterior lateral root and the ACL share over 60% of their tibial footprints.^{13,17}

When the menisci are competent, they absorb between 40% to 70% of the contact force generated between the femur and tibia.¹ By providing strong anchor points, the meniscal roots allow the horns and bodies of the menisci to maintain a stable position that maximizes congruency with the femoral condyles.

Pathology

The conversion of axial load to circumferential hoop stresses occur as the resilient, yet pliable, menisci are squeezed between the femoral condyle and tibial plateau. However, this function is dependent on secure attachment sites at the roots. In the setting of root tear, there is no restraint to the peripheral distortion of the menisci, and meniscal extrusion can occur.¹⁸

Clinical evidence and biomechanical evidence strongly show the consequences of meniscectomy. Multiple studies have shown similar findings and have proven that a meniscal root tear or avulsion is the biomechanical equivalent to total meniscectomy.³ With meniscectomy, not only do peak pressures within compartments increase significantly, it has been demonstrated that other compartments within the knee with

intact menisci do not have increases in compartment pressures, lending more evidence to the menisci functioning as separate units.¹⁶ It has also been found that anterior/posterior translation is increased with medial meniscal root tears. When lateral meniscus root tears were studied with associated ACL tear, the pivot shift motion was found to be exaggerated.⁶

However, the finding of utmost importance in these biomechanical studies is that peak pressures and excessive tibiofemoral motion are restored to normal levels after meniscal root repair. Therefore, repair of meniscal root tears restores native knee biomechanics and will potentially prevent arthritic sequelae from developing.^{3,4,7,19}

Epidemiology

Tears of the posterior root of either menisci are more common than their anterior counterparts, and have been more extensively studied. However, there are situations that can lead to anterior root tears, specifically during ACL reconstruction and during medullary nailing of the tibia.^{20,21} Barring iatrogenic injury, the anterior horn is less at risk for injury than the posterior horn given the biomechanical environment of the knee.³

Medial meniscus posterior root tears are more common than lateral tears. However, these are often more chronic in nature and not associated with an acute event. Risk factors for medial meniscus root tear include increased body mass index, varus mechanical axis, female gender, and low activity level.²²

Lateral meniscus root tears more commonly occur during trauma with sprains and/or tears of knee ligaments.²³ Along with increased recognition of meniscal root injuries associated with knee ligamentous injury comes the recognition that certain ligamentous reconstructions—namely the ACL—are more prone to failure and have higher stresses when a root tear is left untreated.^{17,24}

Diagnosis

The gold standard for diagnosis of a meniscal root lesion is under direct visualization during arthroscopy.¹⁸ The meniscal roots must be probed and stressed to assess their integrity regardless of the initial indication for knee arthroscopy. In most cases, however, the diagnosis of meniscal root tears should occur prior to proceeding to the operating room.

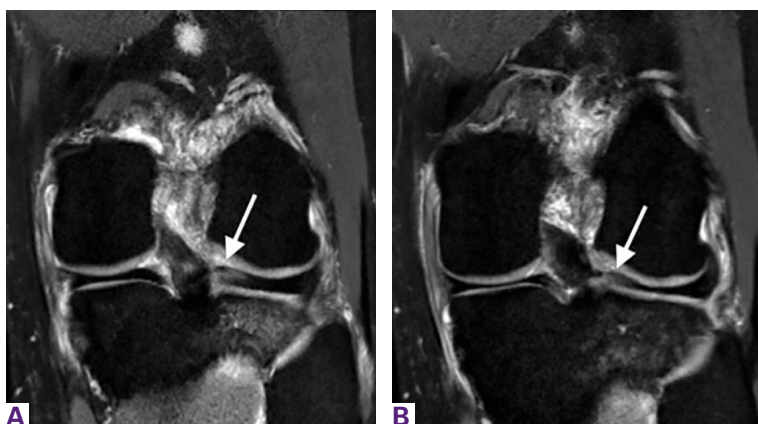

Figure 1. 3T magnetic resonance imaging T2 weighted coronal sections showing (A) lateral meniscus posterior horn and root with increased signal and underlying tibial bone edema at tip of white arrow and (B) radial tear extending full thickness at the posterior horn and root at the tip of the white arrow.

Magnetic resonance imaging (MRI) has been used to aid in diagnosis of meniscal root tears since the early 1990s.²⁵ Now, with the widespread use of MRI, understanding and diagnosis of meniscal root pathology has increased. All sequences should be reviewed, but T2 weighted coronal sections should provide the best visualization of the posterior roots (**Figures 1A, 1B**). Sagittal sections may also be helpful in this diagnosis. Increased signal within the root or horn may represent partial or full thickness tears, or may show a more degenerative process with fraying.^{14,15,26,27}

MRI does have limitations, however. When compared to arthroscopy, the sensitivity of 3T MRI to identify posterior root tears is 77%, and specificity is 73%. Medial root tears are more readily identified on MRI than lateral tears.²⁸ This further highlights the need for high suspicion during arthroscopy with the requisite equipment on standby should it be needed.

A concerning finding that may be observed on MRI includes meniscal extrusion (**Figures 2A, 2B**). Most often seen with the medial meniscus, extrusion is diagnosed when the meniscal body displaces greater than 3 mm past the tibial articular surface on a midcoronal image.^{26,27} Over 50% of patients with medial meniscal extrusion on MRI will have medial meniscal root tears.^{26,27} Conversely, meniscal extrusion is less common in lateral menisci for multiple reasons. The lateral compartment of the knee does not have as high contact pressure as the medial compartment, so the lateral meniscus is not as likely to be extruded from the joint. Additionally, the posterior lateral root has the added benefit of further stability from meniscofemoral ligaments.¹¹ They provide a restraint to meniscal extrusion, with a reported rate of 14% lateral meniscus extrusion when they are intact. If the meniscofemoral ligaments are not present or torn in the setting of posterior root tear, the lateral meniscus extrusion rate quadruples and approaches that of medial meniscal extrusion.¹⁵ Another finding indicative of meniscal root tear is the “ghost meniscus” (**Figure 3**). The posterior horn and anterior horn should both be visible in sagittal cuts on MRI. When the anterior horn is present, but the posterior horn is not visualized, it is termed a “ghost meniscus.” This MRI finding is highly associated with meniscal root tears, and will often be found along with meniscal extrusion on coronal sequencing.^{27,28}

Treatment

Historically, large meniscal tears, extruded menisci, or root avulsions have been treated with conservative observation if asymptomatic, or with meniscectomy when symptomatic. With a meniscal root tear, both forms of treatment will not provide lasting benefit and rapid joint degeneration ensues. Evidence now supports repair over meniscectomy when treating root tears.^{7,8,19,29}

Patients who have meniscal root tears that are likely sequelae of an arthritic process are not candidates for meniscal root repair. These patients will often have known arthritis with an intact meniscus and then progress to menis-

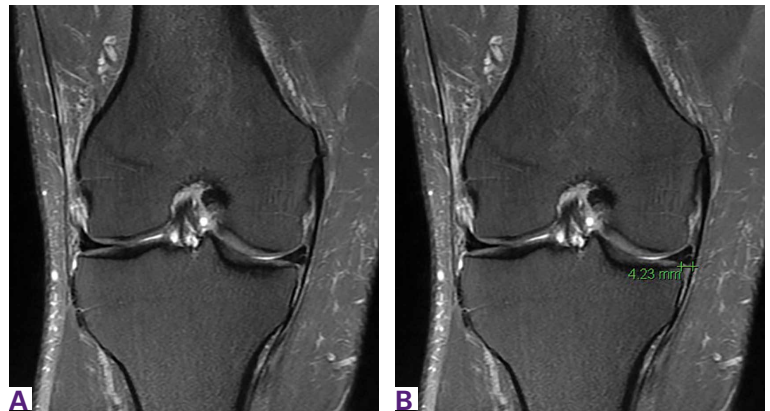

Figure 2. Most often seen with the medial meniscus, extrusion is diagnosed when the meniscal body displaces greater than 3 mm past the tibial articular surface on a midcoronal image.

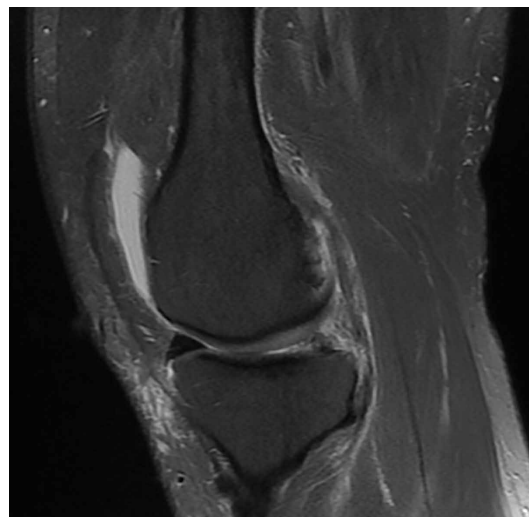

Figure 3. On magnetic resonance imaging, when the anterior horn is present, but the posterior horn is not visualized, it is termed a “ghost meniscus.” This finding is highly associated with meniscal root tears.

cal pathology, most often medially. Because arthritis is the cause of these meniscal tears, a repair will not reverse this process; such repairs will likely fail, and the patient will re-tear the meniscus. For this subset of patients, physical therapy and activity modification are appropriate treatment.

Repair is indicated for patients with acute tears, with or without associated soft tissue injury to the knee, and those with chronic or acute on chronic tears with minimal arthritis within the

knee. The authors' preferred method of repair is via suture fixation through transosseous tunnel (**Figures 4A-4F**).

Once a root tear has been identified during arthroscopy, it should be probed and/or grasped and pulled to confirm its integrity. A shaver is then used to debride any fraying of the meniscus and to debride the anatomic footprint of the root. Curettes and rasps are used to prepare the meniscal bed at the center of its insertion and the undersurface of the meniscal root. Once the attachment site of the root insertion has been prepared, an ACL tip-to-tip drill guide is placed over the prepared bed. For repair of a medial meniscus posterior root, a 2.4-mm drill tip guide pin is inserted through the guide via an incision made at the anteromedial tibia. For repair of the lateral meniscus posterior root, the pin is inserted through an incision at the anterolateral aspect of the tibia.

Once the guide pin has been inserted and is visualized at the center of the root footprint, it is held in place by a hemostat or grasper placed intra-articularly. Next, the guide pin is overreamed with a 4.5-mm cannulated drill bit. The transosseous tunnel is then further prepared using a shaver to remove excess soft tissue surrounding the tunnel entrance at the tibial plateau. Further rasping around the edges of the tunnel is performed to make final preparations.

Attention is then turned back to the meniscal root. Using a FastPass Scorpion (Arthrex), 2 or 3 size 0 fiber wire sutures are passed through the root, and a cinch stitch is then secured leaving four to six stands (2 from each Scorpion pass) in the root. A FiberStick is then introduced into the tibial bone tunnel and each strand of the 0 fiberwire is retrieved. Once the FiberWire attached to the meniscal root is in the tunnel, the meniscus should be directly visualized as the appropriate tension is toggled to reduce the meniscal root into its footprint. In order to securely fasten the meniscal root, an Arthrex SwiveLock 4.75-mm suture anchor is used. The meniscus is again probed to assess the integrity of the repair. Of note, an alternative method of fixation is accomplished by tying the fiberwire over an Arthrex suture button at the anterior tibia.

Postoperatively, weight bearing restriction is warranted, along with range of motion restrictions. During the first 2 weeks, patients will be counseled to be touch down weight bearing with the use of crutches or a walker. During

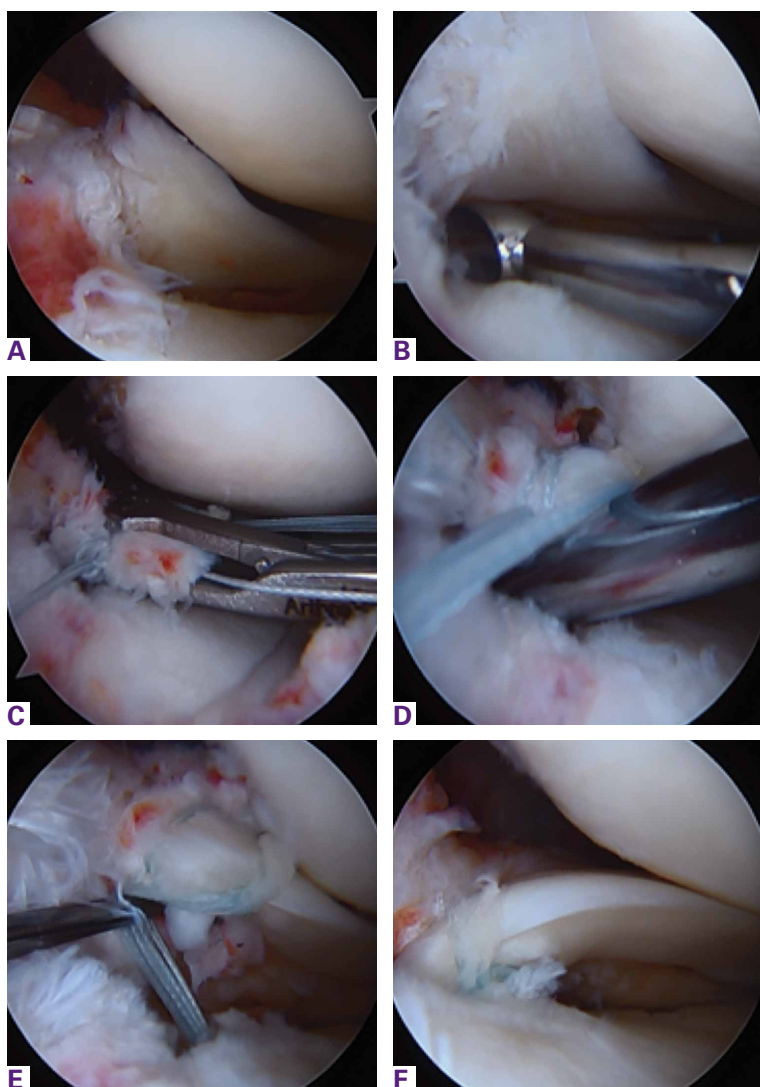


Figure 4. Intraoperative confirmation of diagnosis demonstrating (A) complete radial tear of the lateral meniscus posterior root. The meniscal insertion is then (B) prepared using a curette. The Arthrex Scorpion is then (C) used to pass 2 or 3 (3 used in this case) looped sutures to create cinch stitches in the posterior horn. Once placed, an Arthrex ACL tip-to-tip guide (D) is placed at the center of the insertion and a guide pin followed by a 4.5-mm drill are used to create the transosseous tunnel. Once the sutures are retrieved, via FiberStick, they are pulled into the tunnel (E) and guided into place via a probe. The FiberWire is then fixed to the tibia via suture button or suture anchor while the root is directly visualized in its reduced position (F).

this period, range of motion will be restricted by hinged knee brace to 30° of flexion and full extension. The next 2-week period will advance to progressive partial weight bearing, again with crutches or a walker. Range of motion will also be expanded to 60° of flexion. After a month, the patient will then be allowed to be full weight bearing as tolerated and be weaned from assistive ambulation devices. Range of motion will then be 90° of flexion. It is paramount that full extension be achieved and maintained in the early postoperative period. Quadriceps strengthening should also proceed with unlimited straight leg raises throughout this period as well.

Dr. Doherty is Orthopedic Surgery Resident, The University of Texas Health Science Center at Houston, Texas. Dr. Lowe is Edward T. Smith Professor and Chair, Chairman and Professor, Department of Orthopedic Surgery, University of Texas Medical School at Houston; Medical Director, Memorial Hermann Sports Medicine Institute; and Chief of Orthopedic Surgery, Memorial Hermann Hospital—Texas Medical Center and LBJ Hospital Houston, Texas.

Address correspondence to: David B. Doherty, MD, The University of Texas Health Science Center at Houston, 7000 Fannin St #1200, Houston, TX 77030 (tel, 713-530-0901; email, david.b.doherty@uth.tmc.edu).

Am J Orthop. 2016;45(3):183-187. Copyright Frontline Medical Communications Inc. 2016. All rights reserved.

References

- Kidron A, Thein R. Radial tears associated with cleavage tears of the medial meniscus in athletes. *Arthroscopy.* 2002;18(3):254-256.
- Fairbank TJ. Knee joint changes after meniscectomy. *J Bone Joint Surg Br.* 1948;30B(4):664-670.
- Allaire R, Muriuki M, Gilbertson L, Harner CD. Biomechanical consequences of a tear of the posterior root of the medial meniscus: similar to total meniscectomy. *J Bone Joint Surg.* 2008;90(9):1922-1931.
- Marzo JM, Gurske-DePerio J. Effects of medial meniscus posterior horn avulsion and repair on tibiofemoral contact area and peak contact pressure with clinical implications. *Am J Sports Med.* 2009;37(1):124-129.
- Hein CN, Deperio JG, Ehrensberger MT, Marzo JM. Effects of medial meniscal posterior horn avulsion and repair on meniscal displacement. *Knee.* 2011;18(3):189-192.
- Shybut TB, Vega CE, Haddad J, et al. Effect of lateral meniscal root tear on the anterior cruciate ligament-deficient knee. *Am J Sports Med.* 2015;43(4):905-911.
- Vyas D, Harner CD. Meniscus root repair. *Sports Med Arthrosc Rev.* 2012;20(2):86-94.
- Koenig JH, Ranawat AS, Umans HR, Difelice GS. Meniscal root tears: diagnosis and treatment. *Arthroscopy.* 2009;25(9):1025-1032.
- Fithian DC, Kelly MA, Mow VC. Material properties and structure-function relationships in the menisci. *Clin Orthop.* 1990;(252):19-31.
- Weaver JB. Ossification of the internal semilunar cartilage. *J Bone Joint Surg.* 1935;17(1):195-198.
- Ahn JH, Lee YS, Chang JY, Chang MJ, Eun SS, Kim SM. Arthroscopic all inside repair of the lateral meniscus root tear. *Knee.* 2009;16(1):77-80.
- Bellarbarba C, Bush-Joseph CA, Bach BR Jr. Patterns of meniscal injury in the anterior cruciate-deficient knee: a review of the literature. *Am J Orthop.* 1997;26(1):18-23.
- LaPrade CM, Ellman MB, Rasmussen MT, et al. Anatomy of the anterior root attachments of the medial and lateral menisci: a quantitative analysis. *Am J Sports Med.* 2014;42(10):2386-2392.
- Brody JM, Hulstyn MJ, Fleming BC, Tung GA. The meniscal roots: Gross anatomic correlation with 3-T MRI findings. *AJR Am J Roentgenol.* 2007;188(5):W446-W450.
- Brody JM, Lin HM, Hulstyn MJ, Tung GA. Lateral meniscus root tear and meniscus extrusion with anterior cruciate ligament tear. *Radiology.* 2006;239(3):805-810.
- Poh S-Y, Yew K-SA, Wong P-LK, et al. Role of the anterior intermeniscal ligament in tibiofemoral contact mechanics during axial joint loading. *Knee.* 2012;19(2):135-139.
- Naranje S, Mittal R, Nag H, Sharma R. Arthroscopic and magnetic resonance imaging evaluation of meniscus lesions in the chronic anterior ligament-deficient knee. *Arthroscopy.* 2008;24(9):1045-1051.
- Magee T. MR findings of meniscal extrusion correlated with arthroscopy. *J Magn Reson Imaging.* 2008;28(2):466-470.
- Kim SB, Ha JK, Lee SW, et al. Medial meniscus root tear refixation: comparison of clinical, radiologic, and arthroscopic findings with medial meniscectomy. *Arthroscopy.* 2011;27(3):346-354.
- LaPrade CM, Smith SD, Rasmussen MT, et al. Consequences of tibial tunnel reaming on the meniscal roots during cruciate ligament reconstruction in a cadaveric model, part 1: the anterior cruciate ligament. *Am J Sports Med.* 2015;43(1):200-206.
- Ellman MB, James EW, LaPrade CM, LaPrade RF. Anterior meniscus root avulsion following intramedullary nailing for a tibial shaft fracture. *Knee Surg Sports Traumatol Arthrosc.* 2015;23(4):1188-1191.
- Hwang BY, Kim SJ, Lee SW, et al. Risk factors for medial meniscus posterior root tear. *Am J Sports Med.* 2012;40(7):1606-1610.
- Binfield PM, Maffulli N, King JB. Patterns of meniscal tears associated with anterior cruciate ligament lesions in athletes. *Injury.* 1993;24(8):557-561.
- Wu WH, Hackett T, Richmond JC. Effects of meniscal and articular surface status on knee stability, function, and symptoms after anterior cruciate ligament reconstruction: a long-term prospective study. *Am J Sports Med.* 2002;30(6):845-850.
- Pagnani MJ, Cooper DE, Warren RF. Extrusion of the medial meniscus. *Arthroscopy.* 1991;7(3):297-300.
- Lerer DB, Umans HR, Hu MX, Jones MH. The role of meniscal root pathology and radial meniscal tear in medial meniscal extrusion. *Skeletal Radiol.* 2004;33(10):569-574.
- Costa CR, Morrison WB, Carrino JA. Medial meniscus extrusion on knee MRI: Is extent associated with severity of degeneration or type of tear? *AJR Am J Roentgenol.* 2004;183(1):17-23.
- LaPrade RF, Ho CP, James E, Crespo B, LaPrade CM, Matheny LM. Diagnostic accuracy of 3.0 T magnetic resonance imaging for the detection of meniscus posterior root pathology. *Knee Surg Sports Traumatol Arthroscopy.* 2015;23(1):152-157.
- Chung KS, Ha JK, Yeom CH, et al. Comparison of clinical and radiologic results between partial meniscectomy and refixation of medial meniscus posterior root tears: a minimum 5-year follow-up. *Arthroscopy.* 2015;31(10):1941-1950.