STENOSING SMALL-INTESTINAL ULCERS

Report of Eleven Cases

Charles H. Brown, M.D., and Nevzat Akin, M.D.*
Department of Gastroenterology

PRIMARY small-bowel ulcers are usually circumferential, solitary, located in the distal part of the small intestine, and may be complicated by bleeding, obstruction, and perforation. The origin of this type of ulceration is not known, so the ulcers have been classified as primary, idiopathic, small-intestinal ulcers.

The incidence of primary, idiopathic, small-bowel ulcer was low until 1964. Hangos,[1] in a survey of the world literature to 1959, found only 150 such cases, and Watson,[2] four years later, in a similar survey reported on only 170 cases. Although the description of the first case is attributed by Watson[2] to Matthew Baillie in 1805, less than 200 cases were reported through 1965.

Baker, Schrader, and Hitchcock,[3] and Lindholmer, Nyman, and Räf,[4] in late 1964 reported that enteric-coated potassium with diuretics could cause such ulcers. Stimulated by their findings, studies[5] were done in 415 hospitals in the United States and 73 hospitals in foreign countries, and the number of cases rapidly increased from 170 to 500. In about 50 percent of the cases, the intake of enteric-coated potassium or enteric-coated potassium with thiazide was implicated as a possible etiologic agent. Morgenstern, Freilich, and Panish[6] reported 17 patients in whom such small-intestinal ulcerations had been due to enteric-coated potassium or thiazide drugs containing potassium, and showed experimentally in dogs that such ulcerations could be caused by thiazide with potassium, but not by thiazide alone. The ulcerogenic effect of enteric-coated potassium compounds has been shown experimentally by Bokelman and associates[7] and Diener and associates[8] in monkeys, and by Boley and associates[9] in dogs.

Because of the interest at the Cleveland Clinic in hypertension and antihypertensive drugs, and the infrequent occurrence but increased incidence of stenosing small-bowel ulcers, we reviewed the case records of idiopathic small-intestinal ulcers diagnosed at the Cleveland Clinic from 1953 through 1964.

Clinical Data

Selection of patients. From 1953 through 1964, 11 patients with stenosing small-intestinal ulcers were examined. All of the patients were shown sam-

---

* *Fellow in the Department of Gastroenterology.*

ples of enteric-coated potassium either combined with thiazide or alone; only one patient had taken such a drug. The volume of enteric-coated potassium tablets taken by patients is indicated by the fact that 50,000 such tablets were supplied on prescription by the Cleveland Clinic Pharmacy in the year 1964. Stenosing small-intestinal ulceration developed in only one patient to date, but it is recognized that some patients given this drug in 1964 may still present this complication. Nonetheless, with the extensive use of the thiazide drugs containing potassium, the incidence of small-intestinal ulceration must be relatively low.

Age range, sex ratio, and duration of symptoms. The two youngest patients were six and one-half weeks, and five and one-half years old. The ages of the other nine patients ranged from 31 to 63 years with an average of 45 years. There were four males and seven females. The duration of symptoms was less than four months in seven patients, from two to seven years in three patients, and 20 years in one patient with a chronic iron-deficiency type of anemia.

History and presenting symptoms. Five patients had a history of gastrointestinal bleeding; they had primary symptoms of anemia. The feces were described as tarry, a "currant-jelly" type of feces, red blood in the feces; frequently a patient would have red blood in the feces on one occasion and subsequently tarry feces. The description of and examination of the feces made it difficult to determine whether the bleeding was from the upper gastrointestinal tract (tarry feces), or from the colon (bloody feces). Two of the patients had bleeding only, while in the other three the signs or symptoms of obstruction of the small intestine subsequently developed.

Six patients presented symptoms or signs of obstruction without a history of gastrointestinal bleeding. Since obstruction subsequently developed in three of those patients with gastrointestinal bleeding, a total of 9 of the 11 patients had signs or symptoms of obstruction of the small intestine.

Intermittent diarrhea, associated with abdominal cramping occurred in eight patients. Seven patients had vomiting in addition to diarrhea and abdominal cramping. One patient vomited fecal material. The site of abdominal cramping was usually periumbilical. Five patients lost weight of from 6 to 65 pounds within two to four months after the onset of the symptoms. Although perforation of idiopathic small-intestinal ulcers can occur, no patient in our series had a perforation.

Roentgen studies. In one of the five patients with bleeding, roentgenograms of the small bowel showed evidence of an ulcer and stenosis of the jejunum. Roentgen studies, including motility studies of the small intestine, at the time of a gastrointestinal bleeding episode, were uniformly negative or normal in the other four patients. In two patients with bleeding, obstruction subsequently developed, which was demonstrated by roentgen exami-

nation. One patient with a history of gastrointestinal bleeding but with normal roentgen studies of the small intestine, was found to have a stenosing small-intestinal ulcer at the time of the surgical repairing of a ventral hernia.

Plain roentgenograms of the abdomen, of each of the six patients with clinical evidence of obstruction, demonstrated dilated, gas-filled loops of small intestine. Small-intestinal motility studies after a barium swallow showed dilated small intestine and evidence of obstruction in five of six patients; motility studies were not performed on the six and one-half week old infant. Thus, of the total of nine patients who had obstruction, eight had evidence of abnormality on plain roentgenograms of the abdomen, and seven patients had abnormal results of intestinal motility studies. However, roentgen examinations demonstrated only evidence of obstruction of the small intestine, without a clue as to the cause of the obstruction. (*Fig. 1–3.*)

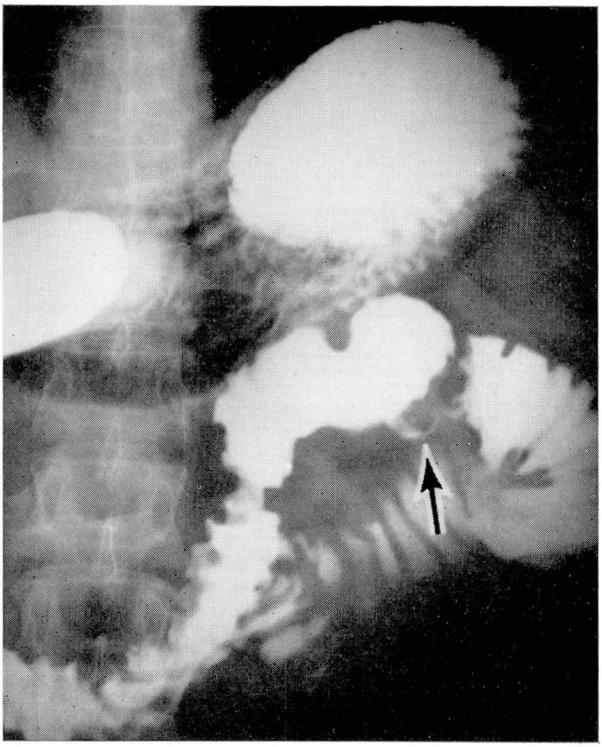

Fig. 1. Roentgenogram showing ulceration in the proximal jejunal segment, with a short area of stenosis, in a 45-year-old man with a history of periumbilical pain, diarrhea, vomiting, and tarry feces.

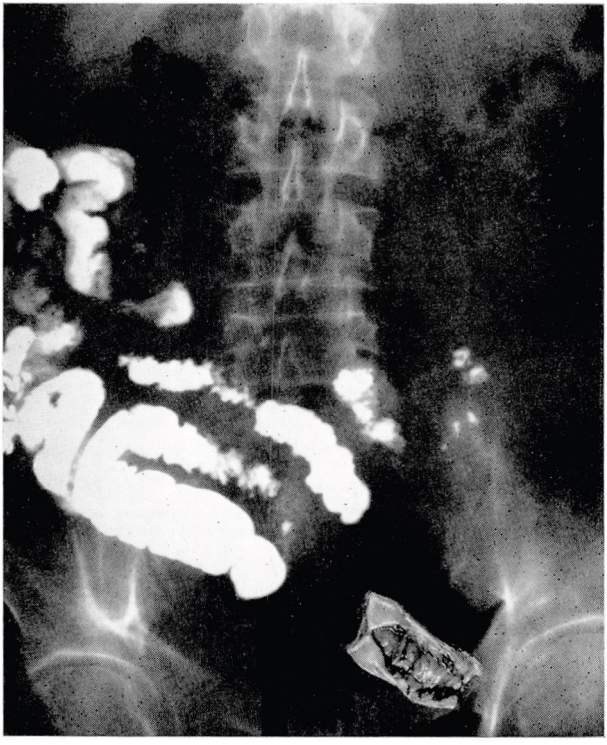

Fig. 2. Abdominal roentgenogram of a 63-year-old man who had abdominal cramps for three weeks and vomited fecal type of material. At operation an ulcer was found corresponding to the narrowed small segment of small intestine seen in the roentgen studies.

Diagnosis. The diagnosis of small-intestinal ulcer can be suspected from a history of gastrointestinal bleeding manifested in the feces by tarry feces, by red blood in the feces, or by feces with both types of blood content, or the so-called currant-jelly feces that occur from bleeding of Meckel's diverticulum. A primary small-bowel ulcer should be particularly suspected if an episode of gastrointestinal bleeding is followed by signs or symptoms of intestinal obstruction, as occurred in 3 of the 11 patients. Iron-deficiency anemia secondary to gastrointestinal bleeding, intermittent or progressive small-intestinal obstruction, or the history of intake of enteric-coated potassium thiazide are helpful clues in the diagnosis.

A definite diagnosis can be made only by surgical exploration and histopathologic study of the surgical specimen; only one definitive preoperative diagnosis was made (*Fig. 1*). At operation, a circumferential stenosing ulcer was present in each of the 11 patients. A segmental resection with an end-to-end anastomosis was performed in each case. There were no deaths and no postoperative complications.

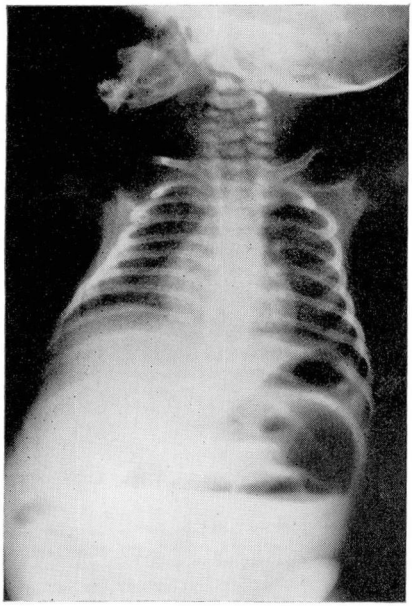

Fig. 3. Plain roentgenogram of the abdomen in the upright position, showing small-bowel obstruction, and multiple fluid levels, in a six and one-half week old infant who had diarrhea since birth, and persistent vomiting, with distended abdomen. Operation disclosed a circumferential stenosing ulcer 6 in. proximal to the ileocecal valve. There was no evidence that the lesion was congenital.

Pathology. The ulcers were in the ileum in nine patients, and in the jejunum in two. The diameters of the ulcers ranged from 0.5 cm. to 3.5 cm. The enlarged lymph nodes characteristic of regional enteritis were absent. The ulcers were solitary in 9 patients; two patients each had two ulcers in the ileum. (*Fig. 4.*)

In one patient with a jejunal ulcer a second jejunal ulcer developed seven months later. None of the other patients had a second ulcer.

REPORT OF THREE INTERESTING CASES

Case 1. A 36-year-old housewife was admitted to the Cleveland Clinic Hospital on October 3, 1959, because of a two-week period of tarry feces, weakness, and anemia, with a blood hemoglobin content of 6.9 gm. per 100 ml. At operation, a careful search of the stomach, duodenum, and small intestine did not disclose the site of bleeding; a vagus transection and pyloroplasty were performed.

The patient was well for four years, and then she was readmitted to the hospital on February 28, 1964. At that time she gave a history of tarry feces, red blood in the feces, and feces resembling cranberry juice. She was given a transfusion of seven units of blood. The bleeding ceased on intensive medical treatment for peptic ulcer. At this time a large incisional ventral hernia was noted. She was discharged from the hospital on March 12, 1964.

On June 30, 1964, she was readmitted to the hospital for the repair of the ventral hernia. There was no further bleeding, and the blood hemoglobin content was 13.5 gm. per 100

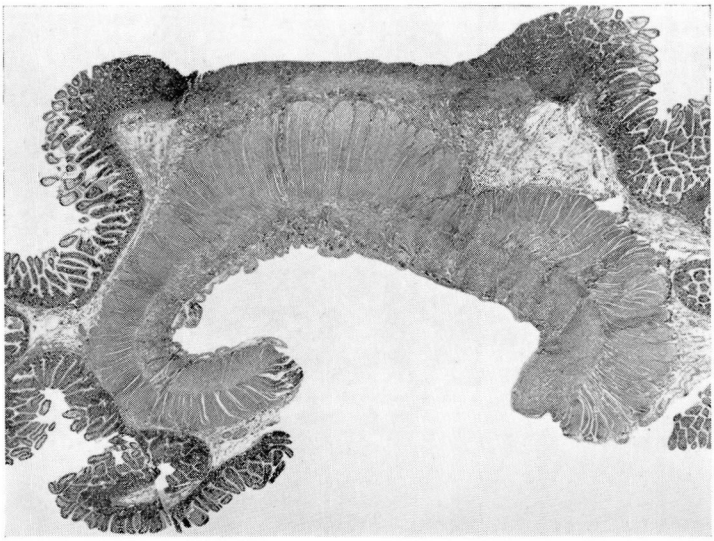

Fig. 4. Photomicrograph of a section of the distal ileum, showing ulceration. The mucosa ends abruptly at the edge of the ulceration. The muscular layer is hypertrophic, secondary to the incomplete stenosis distally. Hematoxylin-eosin stain; magnification ×6.

ml. At the time of operation for the hernia, the ileum was examined, and the stenosing scar of the ileum with dilated ileum proximally was found, and also an active ulcer, 1 cm. in greatest diameter. Fourteen centimeters of ileum was resected and an end-to-end anastomosis was performed. There were no postoperative complications and she has remained well to date.

Comment. This patient had two episodes of bleeding. The stenosing scar in the ileum, which caused some dilatation of the ileum proximally and which the surgeon thought would have soon caused complete obstruction, probably resulted from an ileal ulcer in 1959 and caused the bleeding then. The episode of bleeding in 1964 probably resulted from the active ulcer found at operation five months later.

Case 2. A five-and-one-half year old boy was admitted to the Cleveland Clinic Hospital on December 2, 1956, because of the confirmed diagnosis of patent ductus arteriosus and coarctation of the aorta. He underwent operation on December 1, 1956, to correct the congenital defects and anomalies. Five days later, abdominal cramps developed around the umbilicus, with slight tenderness, minimal guarding and rebound tenderness, and were treated medically. Two months later he was readmitted to the hospital, because of continuing abdominal cramps, intermittent diarrhea, distension of the abdomen, and vomiting. Roentgen studies showed intestinal obstruction. At the operation, two ulcers were found in the terminal ileum, associated with collapse of the distal segment and dilatation of the proximal segment. The ulcers were described as encircling, necrotizing, narrowing, and 2.5 cm. and 9 mm. in diameter. Two feet of ileum was resected and end-to-end anastomosis was performed. Pathologic examination of the resected specimen showed no evidence of a necrotizing vascular lesion. Postoperative recovery was uneventful. At 14 years of age he is enjoying normal health.

Comment. These two patients each had two stenosing ulcers in the ileum. The other nine patients in the series had solitary ulcers.

The prior vascular surgery (case 2) must be considered as etiologic in the development of the ileal ulcers. Preoperatively, the patient had no gastrointestinal symptoms. Other cases of small-intestinal ulceration and infarction after resection of coarctation of the aorta have been reported by Reid and Dallachy.[10]

Case 3. A 63-year-old housewife was admitted to the Cleveland Clinic Hospital on July 3, 1964, because of watery diarrhea, without blood, for the previous three months, associated with a 10-pound loss in weight and abdominal cramps. Vomiting started two days before admission to the hospital. She had been taking enteric-coated pills containing 1000 mg. of potassium chloride and 50 mg. of hydrochlorothiazide daily for one year. She had hypertension for 20 years.

Physical examination revealed a chronically ill patient with distended abdomen that was tympanitic. Auscultation revealed high-pitched, hyperactive, bowel sounds. Roentgen studies of the small intestine showed partial obstruction. Three days later, because of persistence of the symptoms, operation was performed. Chronic stenosing ulcer was found in the ileum; six inches of ileum was resected, and an end-to-end anastomosis was performed. Pathologic examination of the resected specimen showed that a chronic ulcer of the ileum had caused partial stenosis of the small bowel.

Comment. This patient is the only one in our series who had taken enteric-coated potassium before the small-intestinal ulcer developed. She had no history of gastrointestinal bleeding but presented symptoms of obstruction.

DISCUSSION

The etiology of primary nonspecific ulcer of the small intestine is not known, except for the recent reported association with the ingestion of enteric-coated compounds containing potassium.[3-9] One of the 11 patients in our series had prior therapy with enteric-coated potassium. The presence of adhesions secondary to previous operations and intake of anticholinergic drugs have been incriminated, as contributing factors in the mechanism of small-bowel ulceration, by slowing the intestinal motility and concentrating the release of potassium chloride in a limited segment of the small bowel.[11-13] These factors were not applicable to the patient we treated.

The occurrence of a stenosing small-intestinal ulcer in the six and one-half week old infant suggested a possible congenital lesion, but there was no evidence of a band or atresia. One patient had a small pancreatic adenoma, but without the histologic characteristics of the Zollinger-Ellison syndrome.

In one patient a small-intestinal ulcer developed after surgical repair of a patent ductus arteriosus and coarctation of the aorta. Other cases[10] have been reported to occur after operations on the chest, chiefly the repair of congenital lesions. A sudden surge of blood and consequent pressure in

arteries that have been functioning with relatively low pressure has been proposed as the mechanism.

In nine patients in our series, there was no clue as to etiology. The lesions were primary, nonspecific, idiopathic, stenosing, small-intestinal ulcers. According to an early report,[14] perforation was frequent and postoperative mortality ranged from 37 to 66 percent before antibiotics came into use.

SUMMARY

Eleven patients with stenosing small-bowel ulcers were examined at the Cleveland Clinic from 1953 through 1964. Only one of the patients had taken enteric-coated potassium chloride pills; the incidence of ulcers induced by this drug, potassium chloride, must be low compared to the enormous number of such pills dispensed. The ulcer in one patient was secondary to repair of a patent ductus arteriosus and coarctation of the aorta. The cause of the lesions could not be determined in nine patients. Unexplained gastrointestinal bleeding (two patients), symptoms and signs of obstruction of the small intestine (six patients), or a history of gastrointestinal bleeding followed by obstruction (three patients) should alert the clinician to the possibility of small-bowel ulceration. A definitive diagnosis must be made surgically, and treatment comprises resection of the involved segment of small intestine.

The ulcers were circumferential and stenotic; two were in the jejunum and nine in the ileum. In nine patients the ulcers were solitary, and two patients each had two ileal ulcers. There was no perforation.

There was no operative mortality, and recurrence of the ulceration was rare (one patient).

REFERENCES

1. Hangos, G.: Nonspecific ulcer of the small intestine. Gastroenterology **37:** 318–320, 1959.
2. Watson, M. R.: Primary nonspecific ulceration of the small bowel. Arch. Surg. **87:** 600–603, 1963.
3. Baker, D. R.; Schrader, W. H., and Hitchcock, C. R.: Small-bowel ulceration apparently associated with thiazide and potassium therapy. J.A.M.A. **190:** 586–590, 1964.
4. Lindholmer, B.; Nyman, E., and Räf, L.: Nonspecific stenosing ulceration of small bowel; a preliminary report. Acta. chir. scandinav. **128:** 310–311, 1964.
5. Lawrason, F. D.; Alpert, E.; Mohr, F. L., and McMahon, F. G.: Ulcerative-obstructive lesions of the small intestine. J.A.M.A. **191:** 641–644, 1965.
6. Morgenstern, L.; Freilich, M., and Panish, J. F.: The circumferential small-bowel ulcer; clinical aspects in 17 patients. J.A.M.A. **191:** 637–640, 1965.
7. Bokelman, D.; Bagdon, W.; Zwickey, R. E., and Mattis, P. A.: Ulcerogenic effect of potassium chloride on the gastrointestinal tract of the monkey. (Abs. 3243). Fed. Proc. **24:** 715, 1965.

8. Diener, R. M.; Shoffstall, D. H.; Earl, A. E., and Gaunt, R.: The production of potassium induced gastrointestinal lesions in monkeys. (Abs. 3228). Fed. Proc. **24**: 714, 1965.

9. Boley, S. J.; Schultz, L.; Krieger, H.; Schwartz, S.; Elguezabal, A., and Allen, A. C.: Experimental evaluation of thiazides and potassium as a cause of small-bowel ulcer. J.A.M.A. **192**: 763–768, 1965.

10. Reid, H. C., and Dallachy, R.: Infarction of ileum following resection of coarctation of the aorta. Brit. J. Surg. **45**: 625–632, 1958.

11. Schuster, F., and Berg. E. H.: Letter to the editor. Enteric-coated potassium and bowel obstruction. J.A.M.A. **194**: 570, 1965.

12. Boley, S. J.; Allen, A. C.; Schultz, L., and Schwartz, S.: Potassium-induced lesions of the small bowel; I. Clinical aspects. J.A.M.A. **193**: 997–1000, 1965.

13. Allen, A. C.; Boley, S. J.; Schultz, L., and Schwartz, S.: Potassium-induced lesions of the small bowel; II. Pathology and pathogenesis. J.A.M.A. **193**: 1001–1006, 1965.

14. Evert, J. A.; Black, B. M., and Dockerty, M. B.: Primary nonspecific ulcers of the small intestine. Surgery **23**: 185–200, 1948.