

# LEIOMYOMA OF THE ILEUM

## Report of a Case

THOMAS E. JONES, M. D. and ROBERT E. BRUBAKER, M. D.

Small intestinal neoplasms appear infrequently enough to make each case one of considerable interest. In the experience of the surgeons at the Cleveland Clinic 22 patients with small intestinal tumors verified by microscopic section have been operated on. The locations of the tumors and the pathological diagnoses were as follows:

Location	No. of Cases	Pathological Diagnosis
Duodenum.....	3	Adenocarcinoma 3
Jejunum.....	4	Adenocarcinoma 4
Ileum.....	15	Adenocarcinoma 4 Lymphosarcoma 4 Argentaffin tumor 3 Leiomyoma 2 Leiomyosarcoma 1 Spindle cell sarcoma 1

Resection was done in 13 cases, or 59 per cent of the series. Some form of palliative side-tracking operation was performed in 9 cases, or 41 per cent. The hospital mortality for the series was 27 per cent.

One case in which a leiomyoma of the ileum was resected by the senior author is of especial interest.

### CASE REPORT

The patient, a man aged 34, referred to the Clinic by Dr. C. A. Hanson of Newcomerstown, Ohio, was admitted by ambulance, and while being transferred to his room he had a severe chill. He complained bitterly of lower abdominal pain and tenderness. He stated that he had been well until one year ago when he suddenly had passed dark red blood with his stools for several days. Six months later, although he had not noticed further bleeding, he had become pale and easily fatigued and had been treated for anemia of undetermined origin. Four months before admission he had had two chills. Three weeks before admission he had again had several chills, and about the same time he had begun to have increasingly severe constant pain and tenderness in the suprapubic area and pain on bowel movement.

On admission the patient was obviously in severe pain. The temperature was 103° F., and the pulse rate was 112 per minute. The positive physical findings except for pallor of the skin and mucous membranes were confined to the abdomen and rectum. There was marked tenderness over the entire lower abdomen, especially above the symphysis pubis, but the abdomen was not distended. There was an ill-defined mass in the suprapubic region. On digital rectal examination there was such exquisite tenderness in the rectovesical pouch that no further information could be obtained.

The red blood cell count was 3,500,000 per cubic centimeter, and the hemoglobin was 44 per cent.

After a few days the temperature and the lower abdominal tenderness subsided. Proctoscopic examination under anesthesia showed a large mass in the rectovesical pouch which felt cystic in one area. The mucosa of the rectum and lower sigmoid appeared normal.

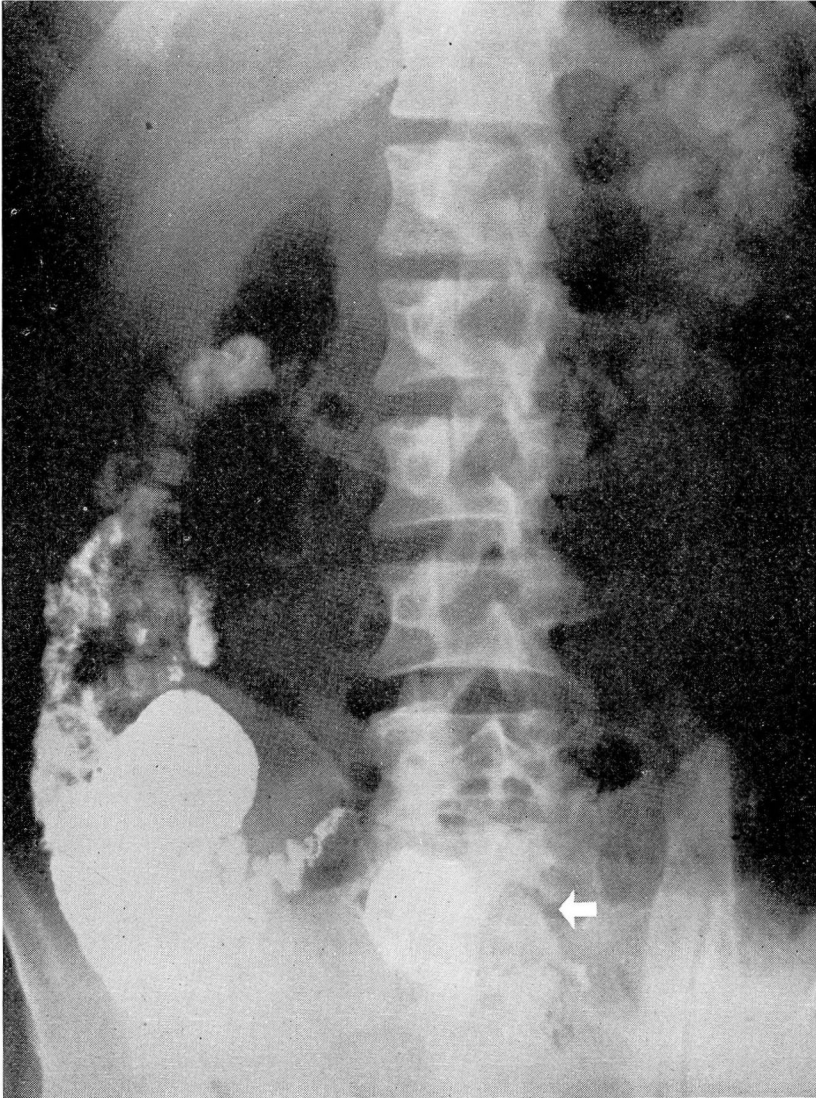


FIGURE 1

## LEIOMYOMA OF THE ILEUM

Roentgen examinations were made of the upper and lower intestinal tracts. Dr. Hughes of the Department of Roentgenology reported an irregular dilated loop of small intestine at the site of the mass which was present on the 4-hour retention film (Fig. 1) and again at the time of the colon x-ray, 24 hours after the ingestion of the barium meal (Fig. 2). This suggested a small intestinal tumor. The sigmoid colon was displaced far to the right.

After preparation with Miller-Abbott tube drainage and transfusions and after the establishment of fluid balance, the patient was operated upon August 18, 1942.

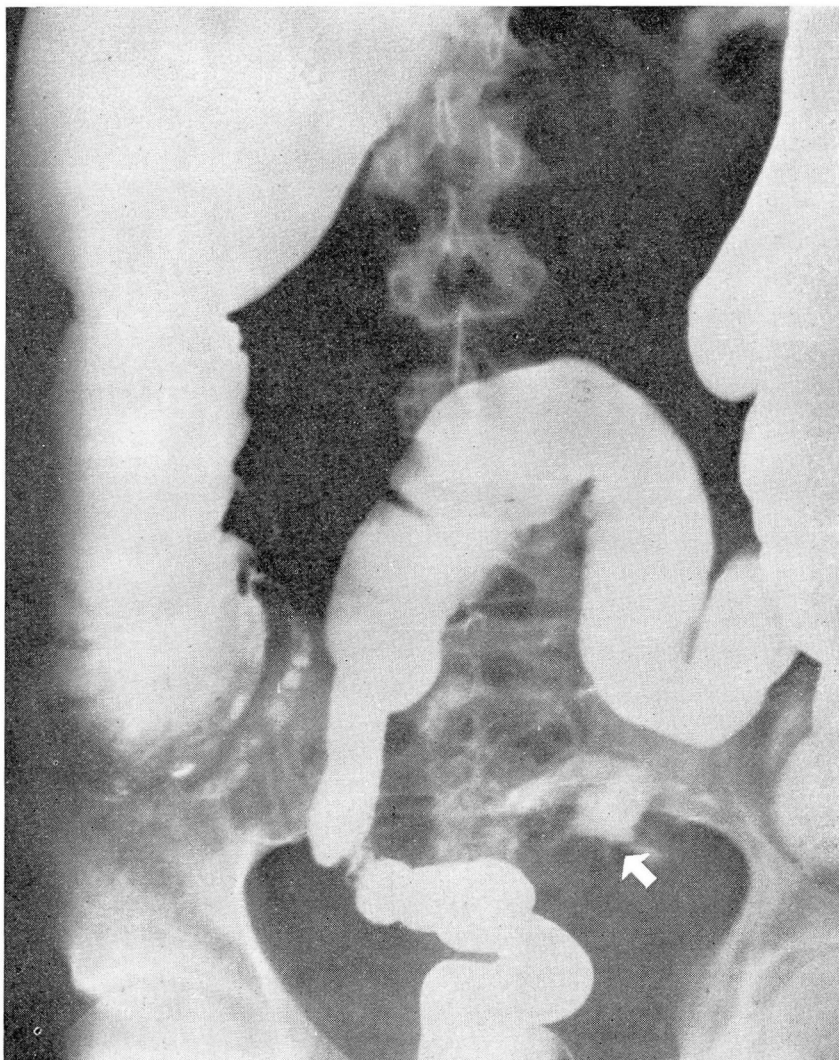


FIGURE 2

The following is a summary of the surgical notes: A large, irregular, red, meaty mass filled the entire left side of the pelvis and was densely adherent to all surrounding structures and to several loops of small bowel. The sigmoid was displaced to the right. The mass, which was delivered from the pelvis with some difficulty, appeared to arise from the antimesenteric border of a loop of ileum. An elliptical portion of the ileum including the attachment of the tumor was excised, and the bowel sutured transversely. A large sheet of rubber dam packed with gauze was placed into the pelvic basin to cover the denuded hollow formed by the dissection of the tumor. The pack was brought out the lower angle of the wound.

The postoperative course was relatively uneventful, and the patient was discharged on the twenty-fifth postoperative day. The packing within the rubber dam was removed gradually beginning the sixth day, and the entire pack was removed by the eleventh day. Three weeks later the cavity had almost entirely healed in.

The principle of the type of pack used in this case, which we believe has been generally forgotten, was suggested by Mikulicz in 1886. Its value in walling off the small intestines from unperitonealized areas is inestimable in instances such as this. It is particularly useful after extensive dissections of inflammatory masses in regional enteritis and after mobilization of adherent neoplasms of the sigmoid and splenic flexures where reperitonealization is impossible.

Dr. Graham of the Department of Pathology described the gross specimen as follows: "The specimen consists of a tumor mass removed from the small intestine. The tissue weighs 535 grams and measures 13 x 12 x 7 centimeters. It appears to be entirely encapsulated, and at one pole there is an elliptical piece of small intestine resected from the antimesenteric border. The intestinal mucosa appears normal except for a fistulous opening which leads into a cavity within the tumor. The tumor appears to have arisen within the wall of the intestine and extended outward. The cross section of the tumor shows what appears to be an entirely encapsulated growth about one-half of which adjacent to the intestine is converted into a large cystic cavity lined with necrotic tissue and inflammatory exudate. The more solid remainder is the seat of ex-

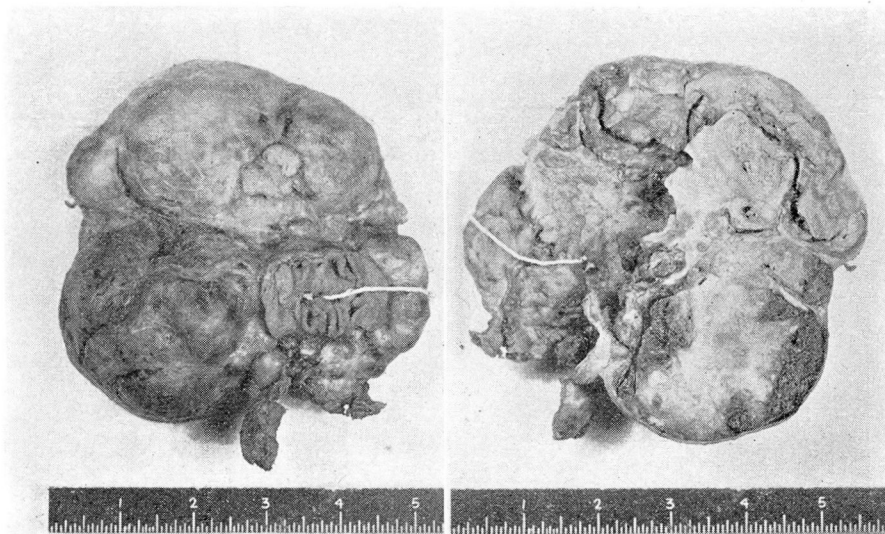


FIGURE 3A

FIGURE 3B

## LEIOMYOMA OF THE ILEUM

tensive infarction and necrosis. Beneath the capsule adjacent to the intestine there is an irregular mass of less degenerated solid white cellular tumor tissue. Microscopical sections show a tumor mass made up of fairly well differentiated, quite uniform, non-striated muscular tissue. Histologically the tumor appears to be benign." Fig. 3A shows the external aspect of the gross fixed specimen. A white string has been passed through the fistula from the lumen of the ileum into the interior of the cavity. Fig. 3B shows a cross section. The white string emerges from the fistula into the necrotic cavity adjacent to the intestine.

### SUMMARY

This case presents several interesting points.

(1) Chills and fever are rare as a presenting symptom in small intestinal neoplasms. Presumably in this instance they were due to extensive recurrent infarction and necrosis within the tumor.

(2) The retained barium shown on the retention and colon films was probably within the cavity of the tumor.

(3) The presence of a fistula into the neoplasm raises the question as to whether its origin may have been in a Meckel's diverticulum.

(4) The growth was difficult to remove because of its dense attachments. The entire left side of the pelvis was denuded of peritoneum. If the small intestines had been allowed to prolapse into this area, obstruction due to adherence and kinking would undoubtedly have ensued. The use of the Mikulicz pack as a mechanical barrier prevented this occurrence.