PREOPERATIVE DIAGNOSIS OF SYMPTOMATIC MECKEL'S DIVERTICULUM

RICHARD C. BRITTON, M.D.
Department of General Surgery

MECKEL'S diverticulum, with an incidence as high as 2 per cent,[1] has been reported to be the most common congenital gastrointestinal anomaly. Nevertheless, mortality from symptomatic diseases of the diverticulum has been reported to be from 6 per cent to 21.6 per cent.[2-5] These high rates have been attributed to delay in diagnosis and in operation.

Concerning the diagnosis of symptomatic Meckel's diverticulum little has been written except in the areas regarding exclusion of other causes of recurrent abdominal pain, peritonitis, intestinal obstruction, or rectal bleeding. The differential diagnosis usually includes appendicitis, mesenteric adenitis, worms, intestinal hemangioma, polyp, food allergy, recurrent intussusception, intestinal duplication, allergic purpura, and anal fissure.

The variety of descriptions of the pain associated with symptomatic Meckel's diverticulum leads one to conclude that periumbilical pain is usual although not pathognomonic. The differential diagnosis between bleeding from the Meckel's diverticulum and some of the more common causes of gastrointestinal bleeding in young patients, such as anal fissure, polyps, intussusception, and duodenal ulcer has been thoroughly described. In an attempt to find the most commonly associated symptoms in patients with proved symptomatic Meckel's diverticulum, a survey of records of patients was undertaken in order to aid earlier diagnosis and operation, and thereby reduce the mortality.

Material

The records of 24 patients in whom the diagnosis of Meckel's diverticulum was proved by operation between 1928 and 1958 comprise the series. All age groups were included in order to provide maximum opportunity for comparison of symptom patterns. The data of the 24 proved and symptomatic cases are summarized in Table 1.

Diagnosis

A correct, presumptive, primary, preoperative diagnosis of Meckel's diverticulum was made in 9 of 24 cases (37.5 per cent). The diagnosis was made as a second choice in two cases.

Preoperative *proof* of the diagnosis was obtained in three of the nine cases. One patient (Case 1) had a congenital persistence of the vitelline duct which, when injected with contrast medium, showed roentgenographic retrograde filling of a Meckel's diverticulum and the terminal ileum. In one patient (Case

Table 1.—*Summary of data* for 24 patients who had symptomatic Meckel's diverticulum**

			Pain			Bleeding		
Case number	Age, years	Sex	Frequency	Site	History	Bouts, number	Transfus., number	Frequency
1	1/6	M	—	—	—	See Comment	0	Daily
2	2	F	—	—	—	2	0	6 mo.
3	3	F	2 mo.	Umb.	1½ y.	3	0	2 mo.
4	3	M	2 mo.	Umb.	2 mo.	2	1	2 mo.
5	3	F	4 w.	Umb.	1 y.	2	0	2 mo.
6	4½	M	—	—	—	1	6	—
7	4½	M	2 w.	Umb.	6 mo.	0	0	—
8	5½	M	1 w.	Umb.	4 y.	0	0	—
9	8	F	1 w.	Umb.	3½ y.	6	12+	6 mo.
10	11	M	2 mo.	Umb.	2 y.	1	2	2 y.
11	11½	F	—	—	—	4	2	2 mo.
12	13	F	1 w.	Umb.	2 y.	2	7	2 mo.
13	19	M	—	—	—	3	4	2 mo.
14	23	M	1 mo.	Umb.	1 y.	5	0	2 mo.
15	28	F	Cont.	Gen.	1 d.	0	0	—
16	31	M	1 d.	R. l. q.	1 mo.	0	0	—
17	45	M	1 d.	R. l. q.	1 mo.	0	0	—
18	49	M	1 w.	Umb.	5 mo.	0	0	—
19	50	M	Cont.	R. l. q.	1 d.	0	0	—
20	50	M	1 mo.	Gen.	15 y.	0	0	—
21	56	M	—	—	—	3	6	1 mo.
22	60	M	1 w.	R. l. q.	4 mo.	0	0	—
23	61	M	Cont.	Gen.	5 d.	0	0	—
24	74	M	Cont.	Epi.	7 d.	0	0	—

*Umb. = umbilical; Cont. = continuous; Gen. = generalized; Epi. = epigastric; G = gastric; I = ileal; P = pancreatic; R. l. q. = right lower quadrant.

Table 1. — *Continued*

Preoperative diagnosis	Emergency operation	Types of mucosa in diverticulum	Ulcer present	Diverticulitis present	Perforation present	Comment
Persistent vitelline duct	No	—	—	—	No	Patent vitelline duct from birth with slight daily bleeding and escape of feces; specimen lost.
Suspected Meckel's diverticulum	No	G I	Yes	No	No	
Meckel's diverticulum; suspected intussusception	No	P G I	Yes	No	No	Acute appendicitis and ileocolic intussusception at age 19 months, Meckel's diverticulum noted but not removed.
Suspected Meckel's divert. and tumor	No	G I	Yes	No	No	
Recurrent intussusception	No	G I	Yes	No	No	
Suspected polyp; Henoch's purpura	Yes	G I	Yes	No	No	
Perforated appendicitis	Yes	G I	Yes	Yes	Yes	
Meckel's diverticulum	No	G I	Yes	No	No	
Suspected Meckel's divert. and polyp	Yes	G I	Yes	No	No	
Suspected Meckel's diverticulum	No	G I	No	No	No	
Suspected Meckel's divert. and polyp	No	G I	Yes	No	No	
Suspected ulcerative colitis and Meckel's diverticulum	Yes	G I	Yes	No	No	
Polyp	Yes	I	Yes	No	No	
Suspected tumor; psychoneurosis	No	I	No	No	No	Symptoms of crampy umbilical pain persisted four years postoperatively; negative roentgen findings.
Acute appendicitis	Yes	I	No	Yes	No	
Ileitis	No	I	No	Yes	No	
Meckel's diverticulum	No	I	No	Yes	No	Only positive radiologic diagnosis; retrograde filling of diverticulum by barium enema.
Chronic pancreatitis	No	I	Yes	Yes	No	Ileo-ileal intussusception with diverticulum as the leading point. Extraluminal mass felt by rectal examination preoperatively.
Ileitis	Yes	—	—	Yes	Yes	Emergency appendectomy done before admission here followed by fecal fistula; resection and ileocecostomy one month later.
Suspected tumor and Meckel's divert.	No	I	No	No	No	Recurrent obstructive symptoms due to peridiverticulitis, fibrosis, and kinking of adjacent ileum.
Duodenal ulcer	Yes	G I	No	No	No	
Incarcerated hernia	Yes	I	No	No	No	Recurrent obstructive symptoms; diverticulum incarcerated in right indirect inguinal hernia and small fibrosarcoma 6 in. proximally.
Sus. gallstone ileus	Yes	I	No	Yes	No	
Sus. gallstone ileus	Yes	I	No	Yes	No	

17) a preoperative barium enema filled the ileum and diverticulum in retrograde fashion. In one patient (Case 3) an operation for appendicitis and ileocolic intussusception had been performed at the age of 19 months, at which time a Meckel's diverticulum was noted proximal to the intussusception, but was not removed. Because of persistence of symptoms of recurrent periumbilical pain and rectal bleeding the diverticulum was removed at a second procedure.

An acute abdominal episode requiring emergency operation occurred in four of the children and in seven of the adults. Signs of peritoneal irritation were present in three, massive bleeding in five, and obstruction in three patients.

The use of various roentgen technics, using contrast media to study the gastrointestinal tract at all levels, was unproductive except in the two patients diagnosed preoperatively as previously mentioned. Long intestinal tubes used to localize the level of bleeding were undependable in four patients, since bleeding had ceased spontaneously in three and the tube could not be passed easily through the duodenum in the fourth patient. Measurement of occult blood in the stool of children whose presenting complaint was abdominal pain was carried out in only one patient (Case 8) and was strongly positive one day following an attack of pain.

Proctosigmoidoscopic findings were negative in all of the pediatric patients who had rectal bleeding. Use of the proctosigmoidoscope in conjunction with the barium enema examination, particularly with the air contrast enema, should be a basic part of the diagnostic procedure for such patients to rule out fissures and polyps.

Operation

In the majority of patients the operation consisted of simple diverticulectomy, by means of division between clamps placed transversely to the long axis of the ileum, at the base of the diverticulum. Closure was carried out in the same axis. In patients in whom it was apparent that this maneuver was likely to narrow the lumen of the ileum, segmental resection and end-to-end or side-to-side anastomoses were used. In each of two patients (Cases 1 and 19) a cutaneous fistula with the diverticulum was removed en bloc. There was no mortality in the group of patients operated on, some of whom underwent late exploration in the presence of the complications of massive hemorrhage, perforation, or obstruction. Relief of symptoms was achieved in all of the patients as determined by follow-up from one week to eleven years.

Pathologic Findings

Pathologic material was available for examination in 22 of 24 cases. The specimen presumably was lost in Case 1. In Case 19 perforation, abscess, and fistula formation had obliterated all vestiges of mucosa lining the muscular remnant of the diverticulum.

Three anatomic varieties of Meckel's diverticulum were seen. In Case 1 a patent omphalomesenteric (vitelline) duct in a newborn infant with pouting umbilical intestinal mucosa bled readily, but not profusely, and allowed the escape of small amounts of intestinal content. In Case 11 there was a diverticulum of the usual position and configuration, but with a solid fibrous cord extending from its apex to the undersurface of the umbilicus. In all of the remaining patients there was the more common form of a diverticulum located from 1½ to 4 ft. from the ileocecal valve, on the antimesenteric border of the ileum, from 1 to 12 cm. in length and from 2 to 5 cm. in diameter.

Less common (clinical) presentations occurred in five patients. In two patients (Cases 7 and 19) perforation occurred; in one patient (Case 22) a variation of Littré's hernia was found, the diverticulum being incarcerated in an indirect inguinal hernia with a small fibrosarcoma of the ileum 6 in. proximal to the diverticulum; and in one patient (Case 20) a chronic peridiverticulitis with local fibrosis and kinking of the small bowel produced obstructive symptoms. Intussusception occurred in only one patient (Case 18).

It was not possible to make an anatomical reassessment and accurately correlate bleeding in the absence of ulcer or gastric mucosa. Healing of an ulcer may have occurred by the time of operation in two patients (Cases 10 and 14). The plane of section may have missed a punctate erosion in two patients (Cases 13 and 21), since emergency operations were performed during active bleeding, but no evidence of ulcer was reported. The presence of gastric mucosa in the diverticulum was established in 11 of the 12 children under 15 years of age; there was no record of examination of the specimen in Case 1. Ten of the 12 children who passed blood in the stool had heterotopic gastric mucosa in the diverticulum. In the two children in whom there was no evidence of bleeding, diverticular ulcers were present. In one patient in whom there was rectal bleeding, and gastric mucosa present in the diverticulum, no ulcer was found in the specimen. The typical anatomic association of gastric mucosa with ulceration in the adjacent or opposite wall is shown in Figures 1 and 2. A correlation of anatomic and pathologic findings is summarized in Table 2.

Discussion

The roentgen diagnosis of Meckel's diverticulum is difficult and undependable, as indicated by a recent report[6] in which a survey of the literature yielded only 37 instances of proved preoperative diagnosis in adults. Physical findings are similarly of little value except when peritoneal irritation is present. The symptom pattern and clinical history still appear to be of greatest value in diagnosis.

The symptoms most consistently present in the infants and children with proved symptomatic Meckel's diverticulum in the series discussed here were *pain* and *bleeding*. Four of the 12 children had gross rectal bleeding only, two had pain only, and six had recurrent pain and bleeding. The pain, more adequately described by the older children in this series, usually was crampy, periumbilical, rarely shifting to the right lower quadrant or the infra-umbilical region, seemed

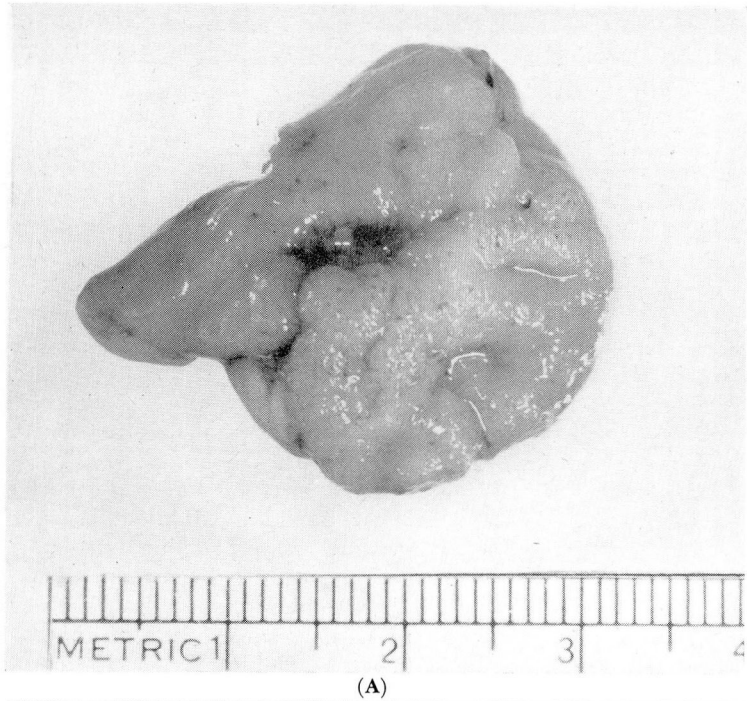

(A)

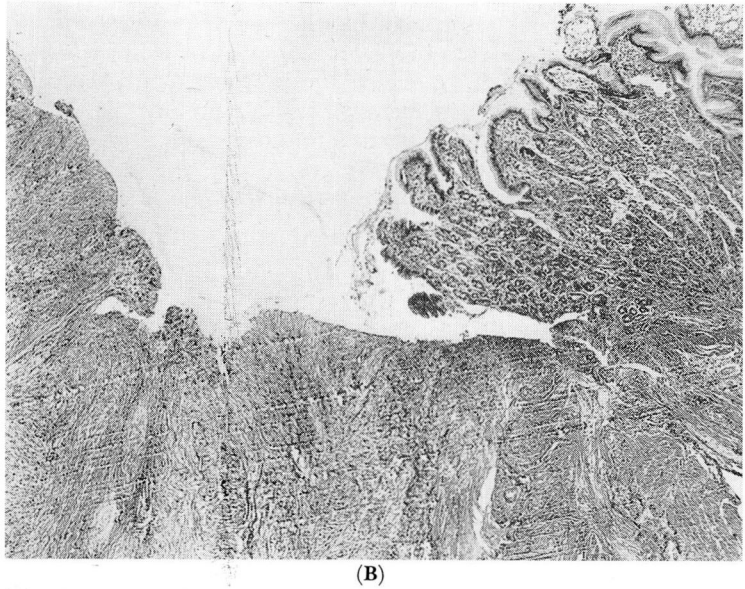

(B)

Fig. 1. (**A**) Photograph of gross specimen showing peptic ulcer in Meckel's diverticulum adjacent to heterotopic gastric mucosa; (**B**) photomicrograph of a section; hematoxylin-eosin stain; x 40.

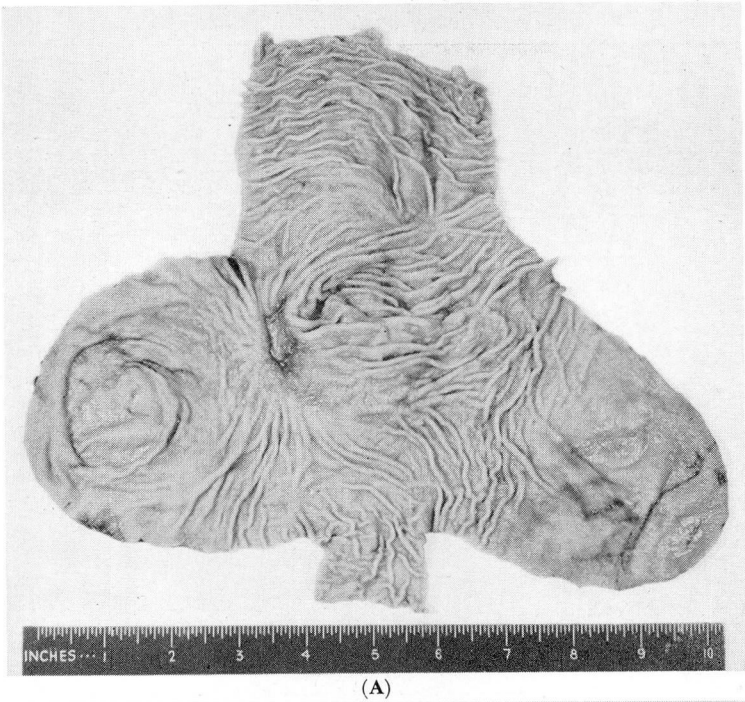

(A)

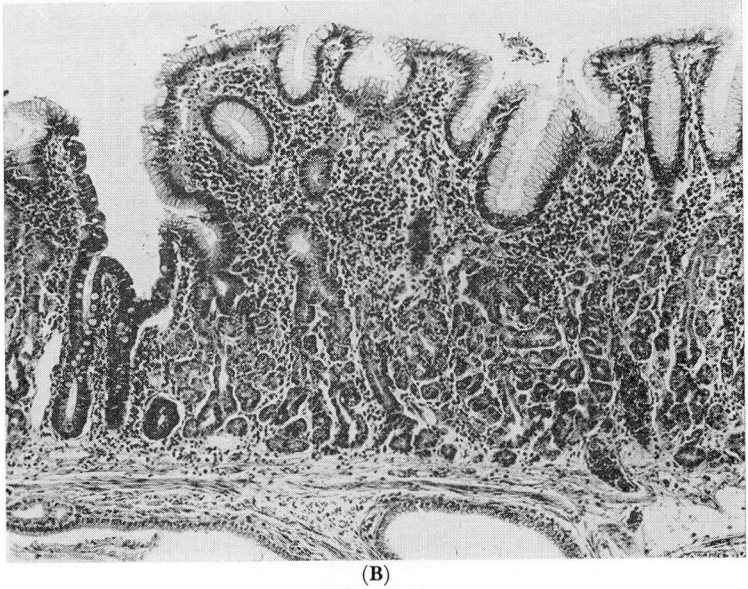

(B)

Fig. 2. (**A**) Photograph of gross specimen showing peptic ulcer in Meckel's diverticulum at the base of the diverticulum with heterotopic gastric and pancreatic mucosa in the fundus; (**B**) photomicrograph of a section; hematoxylin-eosin stain; x 40.

Table 2.—*Correlation of anatomic with pathologic findings*

Symptoms	Type of mucosa* in diverticulum	Number of patients	Number of patients who had			
			Ulcer	Diverticulitis	Perforation	Obstruction
Pain	I	8	1	6	0	3
	G I	2	2	0	1	0
	P G I	0	0	0	0	0
	Not known	1	?	?	1	0
	Total	11	3(?)	6(?)	2	3
Pain and bleeding	I	1	0	0	0	0
	G I	5	4	0	0	0
	P G I	1	1	1	0	0
	Not known	0	0	0	0	0
	Total	7	5	1	0	0
Bleeding	I	1	1	0	0	0
	G I	4	3	0	0	0
	P G I	0	0	0	0	0
	Not known	1	?	?	0	0
	Total	6	4(?)	0(?)	0	0

*I = ileal; P = pancreatic; G = gastric.

to be unrelated to meals, was not relieved by eating or the use of antispasmodics or antacids, and in three patients occurred during periods of fasting. One significant characteristic was that the pain occurred in *attacks* of relatively rapid onset, lasting from 1 to 18 hours, and in several patients was associated with audible and visible hyperperistalsis. In none of the patients was positional relief of pain apparent. The characteristic posture was that of any child with severe abdominal pain, the knees drawn up to the abdomen and frequent shifting from side to side. Symptoms of nausea, vomiting, fever, diarrhea, or constipation occurred in various combinations but not in any consistent pattern that would aid in diagnosis. The character of bleeding in these patients was that described by other authors, being typically red with formed clots when bleeding was copious, and red mixed with dark blood when bleeding was less severe. One child showed typical melena with a tarry stool, followed shortly by red blood with clots. This is consistent with the observation by Kiesewetter[5] that some of the blood may be digested by the acid and enzymes formed by gastric mucosa in the diverticulum.

The adult patients exhibited a variety of symptom patterns which occurred for the first time in adulthood and usually were of relatively short duration except for one patient (Case 20), who had recurrent small-bowel obstructive symptoms for 15 years, associated with fibrosis and kinking of the adjacent ileum

by chronic peridiverticulitis. Two thirds of the adults required emergency operations for perforation and fistula, acute diverticulitis, or massive hemorrhage. The absence of mortality in this collected series notwithstanding, the implication is clear that Meckel's diverticulectomy should be performed prophylactically at the time of laparotomy at any age, and particularly in children who have had suggestive symptoms.

The ratio of sexual incidence has been quoted as 3 to 1 in favor of males, a ratio that is true for this report when the total group of 24 patients is considered, but not for the pediatric group wherein the ratio is closer to 1 to 1.

Other pathologic variations that are said to be common, but were not observed in this series, are torsion of the diverticulum, internal hernia with volvulus, and perforation or obstruction of the diverticulum by a foreign body.

In attempting to explain the cause of diverticulitis in patients without heterotopic tissue in the diverticulum, two main factors have been mentioned. The first is the fact that the Meckel's diverticulum is supplied by an end artery that is a branch of the superior mesenteric artery and is, therefore, theoretically more susceptible to the effects of general systemic disease or infection. In the present series of cases, however, recent or concurrent other illness was not reported. The second factor is the increased likelihood that undigested food particles, particulate matter and foreign bodies will lodge in the diverticulum and will evoke an inflammatory response.

The sequence of events leading up to actual peptic ulceration of the mucosa adjacent to heterotopic gastric mucosa is not clear, particularly because of the episodic nature of the symptoms. The elaboration of hydrochloric acid and pepsin by the heterotopic gastric mucosa is well established, as well as the fact that artificial diverticula in the form of Pavlov pouches will cause ileal ulceration.[7-9] The interpretation of this problem in 1931 by Lindau and Wulff[7] has not been significantly changed. It is presumed that the heterotopic mucosa responds to the ingestion of food, but that additional circumstances must be present for the production of enough ulceration to cause pain or bleeding. In Case 12 the pain was usually crampy, but was boring in nature just prior to the two episodes of bleeding. This also was recorded for other patients, and suggests that one reaction to superficial erosion may be that of segmental hyperperistalsis, producing crampy pain; whereas, penetrating ulceration is more likely to cause pain similar to that of a penetrating duodenal ulcer. While local anatomy and puddling of secretions in the diverticulum may play a role, the persistence of symptoms after simple surgical inversion of the diverticulum into the lumen of the ileum, as cited by Hudson,[9] indicates that they are not essential. Several authors[5,7,9-11] have called attention to the fact that since ulceration may occur at the junction of ileum and diverticulum, the blind application of clamps across the base may exclude the bleeding ulcer, leaving it in situ after the diverticulum has been removed. It would seem that if this occurs, bleeding must cease when the inciting cause has been removed, since secondary bleeding after operation was not observed in any patient in this series.

The most consistently occurring symptoms in the patients in this series in the pediatric group were four in number: (1) *attacks of pain*, recurrent, rather than a

vague soreness or discomfort; (2) *periumbilical location of the pain* with local shifting only, and without radiation; (3) either *crampy or boring pain*, not relieved by usual measures short of narcotics; (4) *rectal bleeding* of liquid red blood and clots when the bleeding is copious, dark or black blood followed by larger amounts of liquid red blood, or by the presence of occult blood in the stool following an attack of periumbilical pain.

Summary

1. The data from 24 patients with symptomatic and proved Meckel's diverticulum are presented. The material has been analyzed for symptom patterns that might be helpful in preoperative diagnosis, especially as applied to children.

2. Of the 12 children in the series, pain was the only symptom in two, bleeding the only symptom in four, and both pain and bleeding the predominant symptoms in six.

3. The most common association of symptoms in the children who had symptomatic Meckel's diverticulum was cramping or boring periumbilical pain occurring in attacks in association with gross or occult blood in the stool.

4. There was no mortality in the surgically treated patients in this series.

References

1. Skinner, I. C., and Walters, W.: Leiomyosarcoma of Meckel's diverticulum, with roentgenologic demonstration of diverticulum: report of case. Proc. Staff Meet., Mayo Clin. **14**: 102-107, 1939.
2. Gross, R. E.: The Surgery of Infancy and Childhood: Its Principles and Techniques. Philadelphia: W. B. Saunders Co. 1953, 1,000 p., p. 219.
3. Brookes, V. S.: Meckel's diverticulum in children; report of 43 cases. Brit. J. Surg. **42**: 57-68, 1954.
4. Söderlund, S.: Meckel's diverticulum in children; report of 115 cases. Acta chir. scandinav. **110**: 261-274, 1956.
5. Kiesewetter, W. B.: Meckel's diverticulum in children. A.M.A. Arch. Surg. **75**: 914-919, 1957.
6. Stein, G. N.; Bennett, H. H.; Finkelstein, A.: Preoperative roentgen diagnosis of Meckel's diverticulum in adults. Am. J. Roentgenol. **79**: 815-822, 1958.
7. Lindau, A., and Wulff, H.: Peptic genesis of gastric and duodenal ulcer; especially in light of ulcers in Meckel's diverticulum and postoperative ulcers in jejunum. Surg., Gynec. & Obst. **53**: 621-634, 1931.
8. Kittle, C. F.; Jenkins, H. P., and Dragstedt, L. R.: Patent omphalomesenteric duct and its relation to diverticulum of Meckel. Arch. Surg. **54**: 10-36, 1947.
9. Hudson, H. W., Jr.: Meckel's diverticulum in children; second clinical and pathologic study with a report of thirteen additional cases. New England J. Med. **208**: 525-535, 1933.
10. Womack, N. A., and Siegert, R. B.: Surgical aspects of lesions of Meckel's diverticulum. Ann. Surg. **108**: 221-236, 1938.
11. Waugh, J. M.; Herrell, W. E., and Crumpacker, L. K.: Peptic ulcer in Meckel's diverticulum causing intrinsic intestinal obstruction; report of two cases. Surgery **11**: 385-391, 1942.