

THE CLINICAL PICTURE

GIULIA RECH, MD

Internal Medicine, Aging and Nephrologic Disease Department, Dermatology Division, Ospedale Sant'Orsola-Malpighi, Università degli Studi di Bologna, Italy

RICCARDO BALESTRI, MD

Internal Medicine, Aging and Nephrologic Disease Department, Dermatology Division, Ospedale Sant'Orsola-Malpighi, Università degli Studi di Bologna, Italy

FEDERICO BARDAZZI, MD

Internal Medicine, Aging and Nephrologic Disease Department, Dermatology Division, Ospedale Sant'Orsola-Malpighi, Università degli Studi di Bologna, Italy

BIANCA MARIA PIRACCINI, MD, PhD

Internal Medicine, Aging and Nephrologic Disease Department, Dermatology Division, Ospedale Sant'Orsola-Malpighi, Università degli Studi di Bologna, Italy

ANNALISA PATRIZI, MD, PhD

Internal Medicine, Aging and Nephrologic Disease Department, Dermatology Division, Ospedale Sant'Orsola-Malpighi, Università degli Studi di Bologna, Italy

The Clinical Picture

Scar reactivation and dry cough

A 52-YEAR-OLD WOMAN is referred to our dermatology clinic by her primary care physician for swelling and redness of seven old scars. The swelling began 3 months ago.

She is on no regular medications. She has never smoked. She underwent liposuction 7 years ago and appendectomy at age 15.

Physical examination reveals indurated and painful brownish-red plaques on the thighs and lower trunk, extending beyond the borders of six scars from the liposuction surgery and one scar from the appendectomy (**FIGURE 1**). She reports no dyspnea, night sweats, weight loss, fever, or other constitutional symptoms, but she has a dry cough that began 2 months after the onset of the skin symptoms. Her primary care physician has managed the cough symptomatically.

Laboratory testing shows mild leukopenia, with a white blood cell count of $3.0 \times 10^9/L$ (reference range 4.2–9.0). Other routine laboratory values are normal, including antinuclear antibody, extractable nuclear antibody, anti-double-stranded DNA, rheumatoid factor, urinalysis, erythrocyte sedimentation rate, C-reactive protein, serum calcium concentration, and liver and renal function tests.

Chest radiography reveals bilateral hilar lymphadenopathy.

Q: What is the next most appropriate diagnostic procedure?

- Skin biopsy
- High-resolution computed tomography (CT) of the chest
- QuantiFERON-TB Gold test
- Ventilatory function tests
- Serum angiotensin-converting enzyme (ACE) level

doi:10.3949/cjcm.78a.10132

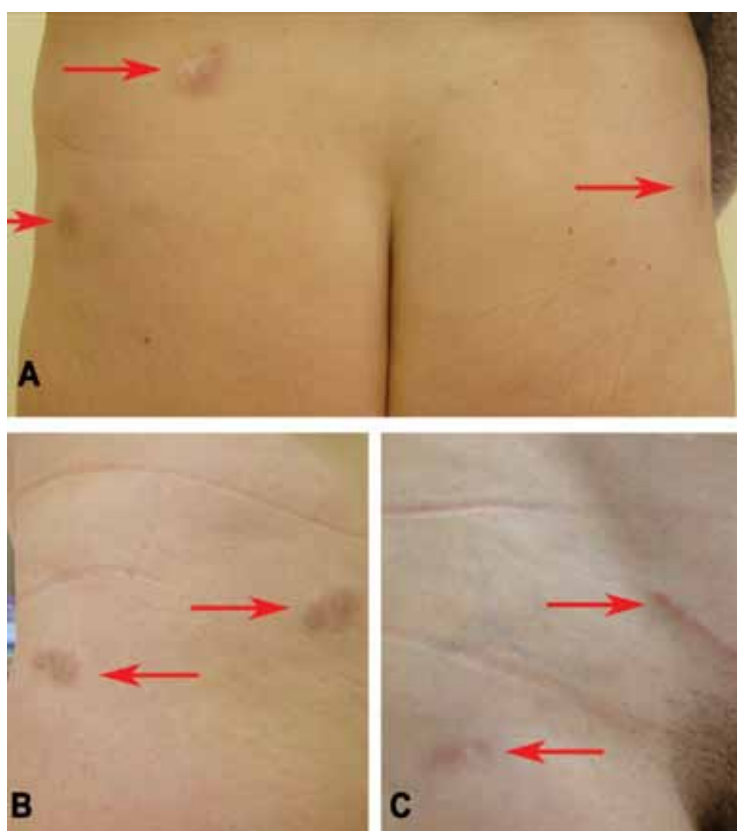


FIGURE 1. Indurated and painful brownish-red plaques localized on old scars: (A) lower trunk, (B) left side, (C) right side.

A: All are appropriate at this point. In this case, skin biopsy and high-resolution CT were performed. Histopathologic examination of one of the scars showed multiple well-demarcated, large, noncaseating epithelioid granulomas with histiocytes and multinucleated giant cells. High-resolution CT confirmed bilateral hilar and mediastinal lymphadenopathy and revealed micronodular densities with a bronchovascular and subpleural distribution.

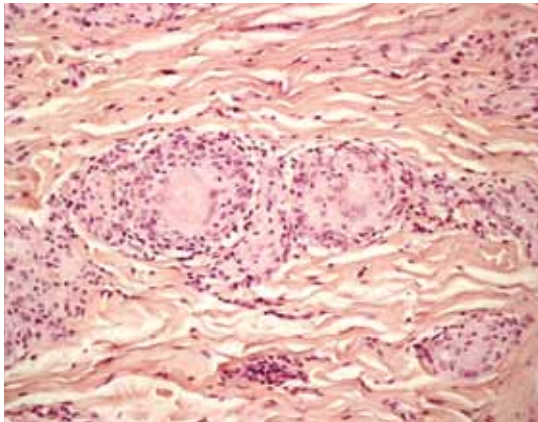


FIGURE 2. Noncaseating granuloma seen on skin biopsy study.

An interferon-gamma-release assay for tuberculosis—QuantiferON-TB Gold (Celltestis, Carnegie, Australia)—was negative. Ventilatory function tests showed a normal pattern, while the serum ACE level, electrocardiography, and an eye examination revealed no pathologic findings.

Q: What is the diagnosis?

- Keloids
- Scar sarcoidosis
- Paraneoplastic sign
- Dermatofibrosarcoma protuberans
- Tuberculosis

A: Based on the data outlined above, we made the diagnosis of scar sarcoidosis with involvement of hilar and mediastinal lymph nodes. The patient began systemic treatment with oral prednisone 1 mg/kg/day for 6 weeks, which was then gradually withdrawn, until the skin and hilar lesions resolved completely.

■ SCAR SARCOIDOSIS

Sarcoidosis is a multisystem disorder of unknown cause characterized by the formation of noncaseating granulomas in the affected organs. Patients may present with symptoms related to the specific organ affected, but they may have no symptoms or only general symptoms such as fever or general malaise.

The skin is involved in 25% of cases and presents so many polymorphous manifestations that sarcoidosis has become known as one of the “great imitators” in dermatology.^{1,2}

Although sarcoidosis on liposuction scars has not been reported previously, the reactivation of old scars is well known on sites of previous injections, tattoos, herpes zoster, and burns.^{2,3}

The finding of granuloma is not specific for sarcoidosis (FIGURE 2). The histologic differential diagnosis of sarcoidosis includes tuberculosis, atypical mycobacteriosis, fungal infection, reaction to a foreign body, rheumatoid nodules, leishmaniasis, Crohn disease, and necrobiosis lipoidica diabetorum.

The diagnosis of scar sarcoidosis is confirmed only by excluding other conditions via a comprehensive evaluation of clinical manifestations, histology, history, and radiologic and laboratory findings.

It has been suggested that the most satisfying therapy for the patient and physician in sarcoidosis is no treatment at all,⁴ and in fact sarcoidosis often remits spontaneously. Currently, the choice of treatment depends on the degree of systemic involvement, and the oral corticosteroid prednisone remains the first-line treatment. If the condition does not respond, the use of other systemic agents has been reported, but their effectiveness has not been evaluated in controlled clinical trials.

Recurrence is common after the suspension of treatment; therefore, treatment may need to be continued for several years, with frequent checkups.

Skin lesions are a visible clue to the diagnosis. Reactivation of old scars may be the single manifestation of cutaneous sarcoidosis, but it may also precede or accompany systemic involvement, often representing the main sign of an exacerbation or a relapse of systemic sarcoidosis, as in our patient.⁵ ■

■ REFERENCES

1. **Marchell RM, Judson MA.** Chronic cutaneous lesions of sarcoidosis. *Clin Dermatol* 2007; 25:295–302.
2. **Tchernev G.** Cutaneous sarcoidosis: the “great imitator”: etiopathogenesis, morphology, differential diagnosis, and clinical management. *Am J Clin Dermatol* 2006; 7:375–382.
3. **Fernandez-Faith E, McDonnell J.** Cutaneous sarcoidosis: differential diagnosis. *Clin Dermatol* 2007; 25:276–287.
4. **Baughman RP, Lower EE, du Bois RM.** Sarcoidosis. *Lancet* 2003; 361:1111–1118.
5. **Sorabjee JS, Garje R.** Reactivation of old scars: inevitably sarcoid. *Postgrad Med J* 2005; 81:60–61.

ADDRESS: Riccardo Balestri, MD, Via Massarenti 1, Clinica Dermatologica, 40138 Bologna, Italy; e-mail ilsabo@libero.it.

Treatment:
oral prednisone
1 mg/kg/day
for 6 weeks,
then tapered
until skin and
hilar lesions
resolved