

DAVID L. LONGWORTH, MD, AND JAMES K. STOLLER, MD, EDITORS

New and emerging infectious diseases: a self-test of clinical recognition

DESPITE PREDICTIONS EARLIER IN THIS CENTURY that infectious diseases would soon be eliminated as a public health problem, they remain the major cause of death worldwide and a significant cause of death and illness in the United States. The US public health system has been challenged by several newly identified pathogens (eg, human immunodeficiency virus [HIV], *Escherichia coli* 0157:H7, hepatitis C) as well as a resurgence of old diseases presumed to be under control (eg, tuberculosis, syphilis). Furthermore, efforts to control and prevent infectious diseases are being undermined by the emergence of drug resistance in conditions such as pneumococcal disease, gonorrhea, malaria, salmonella, tuberculosis, and staphylococcal infections. The following cases present two examples of new infectious diseases of significance to the internist.

CASE 1

Q1 A MAN WITH ACQUIRED IMMUNODEFICIENCY syndrome (AIDS) acquires fevers, night sweats, diarrhea, and several cranberry-like skin lesions (*Figure 1*). A biopsy reveals a circumscribed lesion with lobular capillary proliferation. A Warthin-Starry stain shows pleomorphic gram-negative bacilli (*Figure 2*).

What is the probable diagnosis?

- Secondary syphilis
- Kaposi's sarcoma
- Bacillary angiomatosis
- "Cold abscesses" of tuberculosis

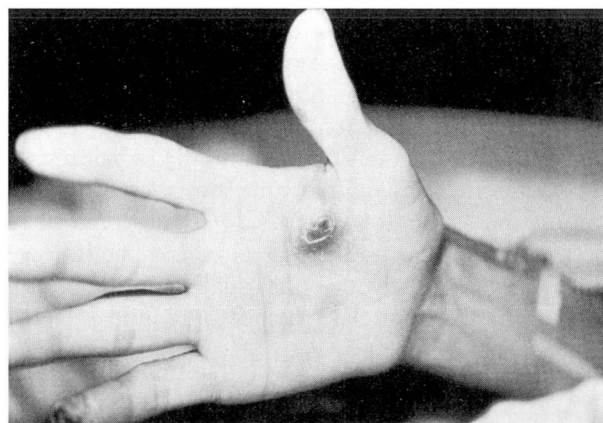


FIGURE 1. Cranberry-like skin lesion in a patient with acquired immunodeficiency syndrome. Photograph courtesy of Dr. Gerri Hall, Cleveland Clinic Foundation.

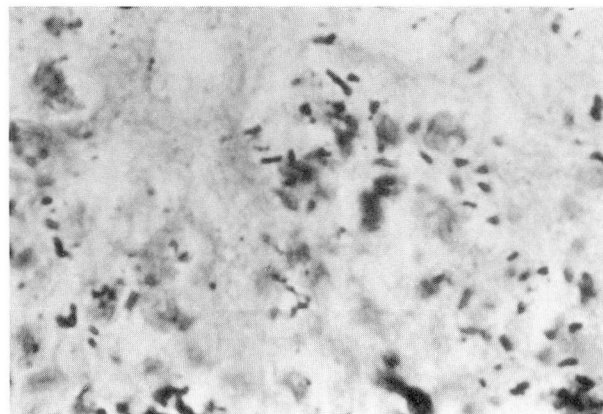


FIGURE 2. Pleomorphic gram-negative bacilli in the lesion shown in *Figure 1* (Warthin-Starry stain, $\times 180$). Photomicrograph courtesy of Dr. Gerri Hall, Cleveland Clinic Foundation.

A1 This patient probably has bacillary angiomatosis. This newly recognized infectious disease primarily affects immunocompromised patients, especially those infected with HIV. Bacillary angiomatosis derives its name from the vascular proliferation seen on histologic examination of affected tissues (including skin, bone, liver, spleen, and brain) and from the presence of bacillary organisms on silver-stain or electron microscopy. The incidence rate of infection is unknown. This disease is probably a zoonosis associated with exposure to cats (or fleas on the cats). The most commonly described cutaneous lesions are nodular raspberry-like tender papules or subcutaneous nodules, which occasionally resemble Kaposi's sarcoma.

Recent molecular microbiologic investigations have confirmed that at least two organisms, *Rochalimaea henselae* and *Rochalimaea quintana* (the louse-born agent of trench fever), can cause bacillary angiomatosis. Clinical manifestations associated with these organisms include bacillary angiomatosis, bacillary peliosis or hepatitis, relapsing fever with bacteremia, and cat-scratch disease. The differential diagnosis of subcutaneous and cutaneous lesions in HIV-infected patients is broad and includes a variety of disseminated opportunistic infections as well as neoplastic and dermatologic conditions. Cutaneous vascular lesions focus the differential diagnosis to Kaposi's sarcoma, verruga peruana (a late manifestation of infection with *Bartonella bacilliformis*), and bacillary angiomatosis.

The presence of bacillary organisms seen with Warthin-Starry staining suggests bacillary angiomatosis; definitive diagnosis depends on the demonstration of the organisms in tissue or in culture. The organisms, small curved gram-negative rods, grow best in 5% carbon dioxide with high humidity on solid tryptic soy agar containing rabbit blood. Isolator-lysis tubes are necessary to isolate them from blood. Excellent clinical response has been reported with erythromycin, rifampin, doxycycline, quinolones, and gentamicin. Beta-lactamase activity has been reported in some strains.

Cat-scratch disease connection

Isolation of both *Afipia felis* and *Rochalimaea* species has been reported in cases of cat-scratch disease. An indirect fluorescent antibody test for *R henselae*, developed at the Centers for Disease Control and Prevention (CDC), has advanced our understanding of the epidemiology of cat-scratch disease.

As recently reported in the *New England Journal of Medicine*, 38 of 45 patients (84%) with cat-scratch disease in Connecticut had positive serologic tests for *R henselae*, compared with 4% of age-matched cat-owning controls. In addition, *R henselae* has been isolated from a lymph node of a patient with cat-scratch disease as well as from the blood and fleas from cats suspected of transmitting cat-scratch disease. Thus, cat-scratch disease and bacillary angiomatosis may be different manifestations of the same infection, and the organism in most cases appears to be a *Rochalimaea*.

CASE 2

Q2 A MAN WORKING ON A SUMMER construction job at Sea Island, Georgia, presents with severe headaches, fever, and myalgia lasting 5 days. The patient recalls being bitten by several ticks. No rash is present. The leukocyte and platelet counts are decreased and liver function test results are mildly elevated. The patient improves after a course of tetracycline. Serologic tests are negative for Rocky Mountain spotted fever, tularemia, and brucella.

The most likely diagnosis for his illness is:

- Epstein-Barr virus
- Acute HIV infection
- Lyme disease
- Ehrlichiosis

A2 The patient most likely has ehrlichiosis. *Ehrlichia* is a genus of tick-borne rickettsial organisms that infect the leukocytes of susceptible mammalian hosts. *E canis* causes an illness of dogs characterized by fever, weight loss, bleeding, and pancytopenia. In 1987 the first case of human ehrlichiosis in the Western Hemisphere was reported in an Arkansas man with fevers, disorientation, pancytopenia, and a history of a tick bite. *Rickettsia*-like organisms in inclusion bodies were observed among circulating leukocytes, and the patient had positive serologic studies for *E canis*. Subsequently, investigators determined that *E chaffeensis*, closely related but not identical to *E canis*, is the sole causative agent of human ehrlichiosis in the United States. Since the initial case description, approximately 250 cases of human ehrlichiosis have been reported in the

United States, mostly from the South Central and South Atlantic states, particularly Oklahoma, Missouri, and Georgia.

Clinical features of ehrlichiosis

The most characteristic features are high fever and headache. Other common features include malaise, nausea, and vomiting. Approximately 90% of patients have a history of a tick bite or exposure to ticks within the preceding 3-week period. After an incubation period of 7 days, ehrlichiosis presents as a nonspecific febrile illness that resembles Rocky Mountain spotted fever. Both are diseases of the outdoors, with the highest incidence in May, June, and July. A rash develops in only approximately 20% of patients with ehrlichiosis (vs 80% with Rocky Mountain spotted fever), and when observed in ehrlichiosis, the rash usually *does not* involve the soles and the palms. Thrombocytopenia is common in both diseases, but neutropenia with an absolute lymphopenia is more commonly observed in ehrlichiosis than in Rocky Mountain spotted fever.

Differential diagnosis

A summertime flu-like illness following a tick bite should immediately raise the suspicion of tick-borne illness, which can result from infections with pathogens that include bacteria (especially *Rickettsia*), viruses, and protozoa. The geographic setting, thrombocytopenia and lymphopenia in the absence of a rash, negative serologic studies for Rocky Mountain spotted fever, and a clinical response to tetracycline suggest a clinical diagnosis of ehrlichiosis. Clinical

findings and a positive serologic test confirm a diagnosis of ehrlichiosis. The CDC now uses an immunofluorescent assay for *E chaffeensis*. A single titer of 1:64 or a fourfold rise or fall confirms the diagnosis. The treatment of choice includes tetracycline or chloramphenicol for 5 to 7 days. Most cases are self-limited, although one fatal case of seronegative ehrlichiosis in an Arkansas woman with AIDS was recently reported in the *New England Journal of Medicine*.

STEVEN M. GORDON, MD
Department of Infectious Disease
The Cleveland Clinic Foundation

SUGGESTED READING

Everett ED, Evans KA, Henry RB, McDonald G. Human Ehrlichiosis in adults after tick exposure: diagnosis using polymerase chain reaction. *Ann Intern Med* 1994; 120:730-735.

Fishbein DB, Dawson JE, Robinson LE. Human Ehrlichiosis in the United States, 1985 to 1990. *Ann Intern Med* 1994; 120:736-743.

McDade JE. Ehrlichiosis—A disease of animals and humans. *J Infect Dis* 1990; 161:609.

Schwartzman WA. Infections due to *Rochalimaea*: the expanding clinical spectrum. *Clin Infect Dis* 1992; 15:893-902.

Slater LN, Welch DE, Hensel D, et al. A newly recognized fastidious gram-negative pathogen as a cause of fever and bacteremia. *N Engl J Med* 1990; 323:1587-1593.

Spach DH, Liles WC, Campbell GL, Quick RE, Anderson DE Jr, Fritsche TR. Tick-borne diseases in the United States. *N Engl J Med* 1993; 329:936-947.

Zangwill KM, Hamilton DH, Perkins BA, et al. Cat-scratch disease in Connecticut - epidemiology, risk factors, and evaluation of a new diagnostic test. *N Engl J Med* 1993; 329:8-13.