



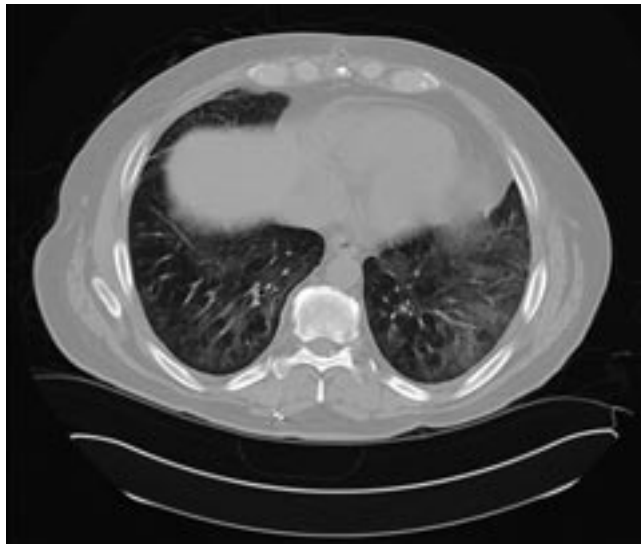
RACHEL M. TALIERCIO, DO
Chief Resident, Medicine Institute, Education
Institute, Cleveland Clinic

JEFFREY CHAPMAN, MD
Staff Physician, Respiratory Institute,
Cleveland Clinic

The Clinical Picture

Dyspnea, arthralgias, and muscle weakness

Before treatment



After treatment

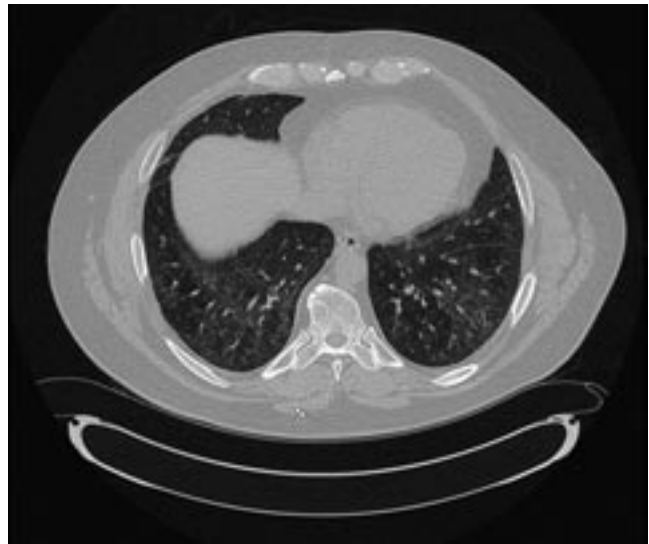

FIGURE 1. The patient's computed tomographic scan. **Left**, axial image through the base of the lungs before treatment. **Right**, after treatment.

A 50-YEAR-OLD man presents with dyspnea on exertion and fatigue that began a year ago and gradually worsened. Associated symptoms include productive cough, fever, and arthralgias in his hands, knees, and shoulders. He also reports muscle weakness with activities such as climbing stairs. Findings on physical examination are normal except for erythematous, thickened, and fissured skin on the dorsal surface of the hands, bibasilar rales, and proximal muscle weakness (his strength is rated 4 on a scale of 5). Computed tomography (CT) of the chest is ordered (**FIGURE 1**).

Q: Which condition is most likely?

- Rheumatoid arthritis with pulmonary involvement
- Hypertrophic pulmonary osteoarthropathy
- Polymyositis-dermatomyositis with pulmonary involvement
- Systemic lupus erythematosus with pulmonary involvement

A: The patient's symptoms and physical findings suggest polymyositis-dermatomyositis with associated interstitial lung disease.

Rheumatoid arthritis can also cause lung disease and proximal myopathy, but early physical findings in the hands would include symmetrical joint effusions and soft tissue swelling of the metacarpophalangeal joints.

Patients with hypertrophic pulmonary

osteoarthropathy present with arthralgias without weakness. Radiographic findings such as osteophytosis and tufting of terminal processes in the hands would support its diagnosis.

A small number of patients with systemic lupus erythematosus develop deforming arthritis with hand involvement that is either erosive (rhumus hand) or nonerosive (Jaccoud arthropathy, or lupus hand), but interstitial lung disease is rare in lupus, making this combination unlikely.

■ MULTIPLE PATHS TO DIAGNOSIS

Physical examination, review of systems, laboratory screening, radiographic findings, lung biopsy, electromyography, and muscle biopsy may be used in conjunction.

The criteria of Bohan and Peter are often used to diagnose polymyositis-dermatomyositis: symmetric proximal muscle weakness, elevated muscle enzymes, electromyographic changes consistent with myopathy, and compatible histologic findings on muscle biopsy, with or without the characteristic dermatologic manifestations.^{1,2} However, the diagnosis can be made in the typical clinical setting on the basis of characteristic levels of anti-Jo-1 antinuclear antibody and elevated serum muscle enzyme.

Depending on the criteria used, the incidence of interstitial lung disease in various studies of polymyositis-dermatomyositis ranged from 5% to 46%.³ Pulmonary involvement can present in one of three forms:

- Sudden onset of dyspnea and fever with alveolar infiltrates on chest radiography and ground-glass opacities on high-resolution chest CT
- Progressive dyspnea with radiographic findings of chronic interstitial lung disease
- No clinical symptoms, but with abnormal findings on chest radiography.⁴

In a minority of patients, lung disease precedes the onset of muscle or skin disease. Much more commonly, patients present with skin and muscle involvement first. In these patients, pulmonary involvement is typically seen 2 to 5 years after the diagnosis.² Patients with interstitial lung disease are more likely to have arthralgias and arthritis than are those

without lung involvement. Interestingly, the finding of microangiopathy on nail fold capillaroscopy strongly suggests pulmonary disease.³

Laboratory findings

Creatine kinase elevation is a marker of disease activity in the muscles. Aldolase, aspartate aminotransferase, and alanine aminotransferase levels may also be elevated but are not muscle-specific. Anti-Jo-1 antinuclear antibody is characteristic, although it can be negative in some patients.

Pulmonary function testing

Restrictive lung physiology with impaired diffusing capacity is the predominant pattern noted.

Lung biopsy findings

Polymyositis-dermatomyositis-associated interstitial lung disease is not limited to one histologic pattern. Nonspecific interstitial pneumonitis is the most common, but usual interstitial pneumonia, organizing pneumonia, and diffuse alveolar damage are also described.² Patients with nonspecific interstitial pneumonitis and organizing pneumonia are suspected to have a better response to immunosuppression and better survival, although controlled studies are absent.

CT appearance

Polymyositis-dermatomyositis complicated by interstitial lung disease does not have a distinct appearance on high-resolution CT. However, the radiographic changes in most cases will suggest the underlying pathology, and this can be used to guide therapy. Most common are bibasilar subpleural ground-glass and reticular opacities that curiously spare the immediate 1 to 2 mm of subpleural parenchyma.^{1,3} This pattern is very suggestive of fibrotic nonspecific interstitial pneumonitis. Patchy consolidations with air bronchograms suggest organizing pneumonia. Bibasilar, subpleural honeycomb cystic changes and traction bronchiectasis are noted in usual interstitial pneumonia and suggest fibrosis, which will not improve with therapy. In patients whose disease is progressive, the areas of consolidation often evolve into honeycomb cystic changes.^{2,4}

Lung disease can antedate or be more apparent than skin or muscle findings

■ TREATMENT IS WITH STEROIDS AND OTHER IMMUNOSUPPRESSIVES

Oral corticosteroids in dosages of 0.5 to 1 mg/kg are first-line therapy. Clinically, muscle disease often improves before lung disease, and treatment may be extended to several months. The histologic pattern suggested by CT or by pathologic study of surgical lung biopsy specimens is a better predictor of treatment response than clinical presentation. Nonspecific interstitial pneumonitis and organizing pneumonia have the highest steroid response rates.³ However, many patients do not respond to steroids alone—only 44% in one study.⁵ Furthermore, treatment response does not indicate recovery, as the disease may relapse.

The addition of immunosuppressive therapy with cyclophosphamide (Cytoxan) may halt deterioration in patients with polymyositis-dermatomyositis-associated interstitial lung disease who are steroid-resistant or may be useful as a steroid-sparing agent in recurrent disease after initial steroid withdrawal. In some cases, therapy with cyclophosphamide improved oxygenation and led to resolution of abnormalities on chest radiography.^{6,7}

Azathioprine (Imuran), methotrexate, and hydroxychloroquine (Plaquenil) have all been used as part of a steroid-sparing regimen.¹ Tacrolimus (FK 506; Prograf) and rituximab (Rituxan) are emerging therapies, especially for patients who cannot tolerate cytotoxic immunosuppressive agents

or who progress despite them.^{8,9}

■ PROGNOSIS IS WORSE IF LUNG DISEASE IS PRESENT

The presence of interstitial lung disease increases the risk of death in polymyositis-dermatomyositis. Additionally, clinicians must assess interstitial lung disease separately from muscle or skin disease, as there does not have to be correlation between the activity in the separate organs. Fortunately, the treatment for lung, muscle, and skin involvement is often the same.

Several elements suggest poor prognosis. An acute and aggressive presentation often heralds a poor outcome.¹ Neutrophil alveolitis on bronchoalveolar lavage and a very low diffusing capacity (< 45%) have both been associated with a poorer prognosis.³ The histologic pattern not only predicts treatment response but also prognosis. Patients whose lung biopsies reveal nonspecific interstitial pneumonitis or organizing pneumonia have a better outcome than do patients with usual interstitial pneumonia or diffuse alveolar damage.

In one study,¹ 36 patients with polymyositis-dermatomyositis and interstitial lung disease were followed for 5 years. Resolution was noted in 19.4%, improvement in 55.6%, and deterioration in 25%. Overall, the survival rate was 86.5% at 5 years, and the death rate attributable to pulmonary complications was 13.9% in patients with interstitial lung disease.¹ ■

■ REFERENCES

1. Douglas WW, Tazelaar HD, Hartman TE, et al. Polymyositis-dermatomyositis-associated interstitial lung disease. *Am J Respir Crit Care Med* 2001; 164:1182–1185.
2. Marie I, Hatron PY, Hachulla E, Wallaert B, Michon-Pasturel U, Devulder B. Pulmonary involvement in polymyositis and in dermatomyositis. *J Rheumatol* 1998; 25:1336–1343.
3. Marie I, Hachulla E, Cherin P, et al. Interstitial lung disease in polymyositis and dermatomyositis. *Arthritis Rheum* 2002; 47:614–622.
4. Akira M, Hara H, Sakatani M. Interstitial lung disease in association with polymyositis-dermatomyositis: long-term follow-up CT evaluation in seven patients. *Radiology* 1999; 210:333–338.
5. Nawata Y, Kurasawa K, Takabayashi K, et al. Corticosteroid resistant interstitial pneumonitis in dermatomyositis/polymyositis: prediction and treatment with cyclosporine. *J Rheumatol* 1999; 26:1527–1533.
6. Schnabel A, Reuter M, Gross WL. Intravenous pulse cyclophosphamide in the treatment of interstitial lung disease due to collagen vascular disease. *Arthritis Rheum* 1998; 41:1215–1220.
7. Shinohara T, Hidaka T, Matsuki Y, et al. Rapidly progressive interstitial lung disease associated with dermatomyositis responding to intravenous cyclophosphamide pulse therapy. *Intern Med* 1997; 36: 519–523.
8. Wilkes MR, Sereika SM, Fertig N, Lucas MR, Oddis CV. Treatment of antisynthetase-associated interstitial lung disease with tacrolimus. *Arthritis Rheum* 2005; 52:2439–2446.
9. Ytterberg SR. Treatment of refractory polymyositis and dermatomyositis. *Curr Rheumatol Rep* 2006; 8:167–173.

ADDRESS: Jeffrey Chapman, MD, Department of Pulmonary, Allergy, and Critical Care Medicine, A90, Cleveland Clinic, 9500 Euclid Avenue, Cleveland, OH 44195; e-mail chapmaj@ccf.org.

Oral corticosteroids are first-line therapy, but many patients do not respond to steroids alone