

Zika virus: Counseling considerations for this emerging perinatal threat

📌 Zika virus infection, although typically mild and often asymptomatic, can have serious consequences in pregnancy. As the pandemic rapidly spreads and new routes of virus transmission are identified, are you ready to counsel patients at risk?

Anushka Chelliah, MD, and Patrick Duff, MD

IN THIS ARTICLE

Management strategies for pregnant patients with Zika virus exposure

page 29

Fetal surveillance

page 31

Perinatal counseling on exposure prevention

page 32

CASE 1 Pregnant traveler asks: Should I be tested for Zika virus?

A 28-year-old Hispanic woman (G3P2) at 15 weeks' gestation visits your office for a routine prenatal care appointment. She reports having returned from a 3-week holiday in Brazil 2 days ago, and she is concerned about having experienced fever, malaise, arthralgias, and a disseminated erythematous rash. She has since heard about the Zika virus and asks you if she and her baby are in danger and whether she should be tested for the disease.

What should you tell this patient?



Dr. Chelliah is a Maternal Fetal Medicine Fellow in the Division of Maternal Fetal Medicine, Department of Obstetrics and Gynecology, University of Florida College of Medicine, Gainesville.



Dr. Duff is Associate Dean for Student Affairs and Professor of Obstetrics and Gynecology in the Division of Maternal Fetal Medicine, Department of Obstetrics and Gynecology, University of Florida College of Medicine.

The authors report no financial relationships relevant to this article.

The Zika virus is an RNA *Flavivirus*, transmitted primarily by the *Aedes aegypti* mosquito.¹ This virus is closely related to the organisms that cause dengue fever, yellow fever, chikungunya infection, and West Nile infection. By feeding on infected prey, mosquitoes can transmit the virus to humans through bites. They breed near pools of stagnant water, can survive both indoors and outdoors, and prefer to be near people. These mosquitoes bite mostly during daylight hours, so it is essential that people use insect repellent throughout the day while in endemic areas.² These mosquitoes live only in tropical regions; however, the *Aedes albopictus* mosquito, also known as the Asian tiger mosquito, lives in temperate regions and can transmit the Zika virus as well³ (FIGURE 1).

The Zika virus was first discovered in 1947 when it was isolated from a rhesus monkey in Uganda. It subsequently spread to Southeast Asia and eventually caused major outbreaks in the Yap Islands of Micronesia (2007)⁴ and French Polynesia (2013).⁵ In 2015, local transmission of the Zika virus infection was noted in Brazil, and, most recently, a pandemic of Zika virus infection has occurred throughout South America, Central

FIGURE 1 *Aedes aegypti* and *Aedes albopictus* mosquitoes



Aedes aegypti (left) and *Aedes albopictus* (right) mosquitoes. *Aedes* mosquitoes are the main transmission vector for the Zika virus.

America, and the Caribbean islands. To date, local mosquito-borne virus transmission has not occurred in the continental United States, although at least 82 cases acquired during travel to infected areas have been reported.⁶

Additionally, there have been rare cases involving spread of this virus from infected blood transfusions and through sexual contact.⁷ In February 2016, the first case of locally acquired Zika virus infection was reported in Texas following sexual transmission of the disease.⁸

Clinical manifestations of Zika virus infection

Eighty percent of patients infected with Zika virus remain asymptomatic. The illness is short-lived, occurring 2 to 12 days following the mosquito bite, and infected individuals usually do not require hospitalization or experience serious morbidity. When symptoms are present, they typically include low-grade fever (37.8° to 38.5°C), maculopapular rash, arthralgias of the hands and feet, and nonpurulent conjunctivitis. Patients also may experience headache, retro-orbital pain, myalgia, and, rarely, abdominal pain, nausea, vomiting, diarrhea, ulcerations of mucous membranes, and pruritus.⁹ Guillain-Barré syndrome has been reported in association with Zika virus infection¹⁰; however, a definitive cause-effect relationship has not been proven.

If a pregnant woman is infected with the Zika virus, perinatal transmission can occur, either through uteroplacental transmission or vertically from mother to child at the time of delivery. Zika virus RNA has been detected in blood, amniotic fluid, semen, saliva, cerebrospinal fluid, urine, and breast milk. Although the virus has been shown to be present in breast milk, there has been no evidence of viral replication in milk or reported transmission in breastfed infants.¹¹ Pregnant women are not known to have increased susceptibility to Zika virus infection when compared with the general population, and there is no evidence to suggest pregnant women will have a more serious illness if infected.

The Zika virus has been strongly associated with congenital microcephaly and fetal loss among women infected during pregnancy.¹² Following the recent large outbreak in Brazil, an alarmingly high number of Brazilian newborns with microcephaly have been observed. The total now exceeds 4,000. Because of these ominous findings, fetuses and neonates born to women with a history of infection should be evaluated for adverse effects of congenital infection.

Management strategies for Zika virus exposure during pregnancy

The incidence of Zika virus infection during pregnancy remains unknown. However, a



Zika virus has been strongly associated with congenital microcephaly and fetal loss

TABLE 1 Testing for Zika virus following symptom onset*

Symptom onset	Testing
<4 days	<ul style="list-style-type: none"> • RT-PCR of serum for detection of Zika virus RNA • Acute serum should be obtained to compare with convalescent serum 2 to 3 weeks later • Concomitant RT-PCR testing for dengue virus and chikungunya virus
4–7 days	<ul style="list-style-type: none"> • RT-PCR of serum for detection of Zika virus RNA • Zika virus serologic testing (IgM and confirmatory neutralizing antibody titers that are ≥4-fold higher than dengue virus neutralizing antibody titers in serum) • Testing is considered inconclusive if Zika virus neutralizing antibody titers are <4-fold higher than dengue virus neutralizing antibody titers • Acute and convalescent sera should be obtained to detect an increased antibody titer within a 2-week interval • Concomitant serologic testing for dengue virus infection and chikungunya virus infection
≥7 days	<ul style="list-style-type: none"> • Zika virus serologic testing (IgM and confirmatory neutralizing antibody titers that are ≥4-fold higher than dengue virus neutralizing antibody titers in serum) • Testing is considered inconclusive if Zika virus neutralizing antibody titers are <4-fold higher than dengue virus neutralizing antibody titers • Acute and convalescent sera should be obtained to detect an increased antibody titer within a 2-week interval • Concomitant serologic testing for dengue virus infection and chikungunya virus infection

*Contact your local or state health department regarding availability of testing. Laboratory specimens also may be sent to the Centers for Disease Control and Prevention Arbovirus Diagnostic Laboratory (telephone: 1-970-221-6400).

Source: Centers for Disease Control and Prevention. Updated diagnostic testing for Zika, chikungunya, and dengue viruses in US Public Health Laboratories. <http://www.cdc.gov/mmwr/PDF/mm4407a1.pdf>. Accessed February 12, 2016.

Abbreviations: IgM, immunoglobulin M; RT-PCR, reverse transcriptase-polymerase chain reaction.



Maternal-fetal transmission of Zika virus can occur throughout pregnancy

pregnant woman may be infected in any trimester, and maternal-fetal transmission of the virus can occur throughout pregnancy. If a patient is pregnant and has travelled to areas of Zika virus transmission, or has had unprotected sexual contact with a partner who has had exposure, she should be carefully screened with a detailed review of systems and ultrasonography to evaluate for fetal microcephaly or intracranial calcifications. The US Centers for Disease Control and Prevention (CDC) initially recommended that, if a patient exhibited 2 or more symptoms consistent with Zika virus infection within 2 weeks of exposure or if sonographic evidence revealed fetal microcephaly or

intracranial calcifications, she should be tested for Zika virus infection.¹¹

More recently, the CDC issued new guidelines recommending that even asymptomatic women with exposure have serologic testing for infection and that all exposed women undergo serial ultrasound assessments.¹³ The CDC also recommends offering retesting in the mid second trimester for women who were exposed very early in gestation.

The best diagnostic test for infection is reverse transcriptase-polymerase chain reaction (RT-PCR), and, ideally, it should be completed within 4 days of symptom onset. Beyond 4 days after symptom onset, testing for Zika virus immunoglobulin M (IgM)-

specific antibody and neutralizing antibody should be performed in addition to the RT-PCR test. At times, interpretation of antibody testing can be problematic because cross-reaction with related arboviruses is common. Moreover, Zika viremia decreases rapidly over time; therefore, if serum is collected even 5 to 7 days after symptom onset, a negative test does not definitively exclude infection (TABLE 1).

In the United States, local health departments should be contacted to facilitate testing, as the tests described above are not currently commercially available. If the local health department is unable to perform this testing, clinicians should contact the CDC's Division of Vector-Borne Diseases (telephone: 1-970-221-6400) or visit their website (<http://www.cdc.gov/ncezid/dvbd/specimensub/arboviral-shipping.html>) for detailed instructions on specimen submission.

Testing is not indicated for women without a history of travel to areas where Zika virus infection is endemic or without a history of unprotected sexual contact with someone who has been exposed to the infection.

Following the delivery of a live infant to an infected or exposed mother, detailed histopathologic evaluation of the placenta and umbilical cord should be performed. Frozen sections of placental and cord tissue should be tested for Zika virus RNA, and cord serum should be tested for Zika and dengue virus IgM and neutralizing antibodies. In cases of fetal loss in the setting of relevant travel history or exposure (particularly maternal symptoms or sonographic evidence of microcephaly), RT-PCR testing and immunohistochemistry should be completed on fetal tissues, umbilical cord, and placenta.²

Treatment is supportive

At present, there is no vaccine for the Zika virus, and no hyperimmune globulin or antiviral chemotherapy is available. Treatment is therefore supportive. Patients should be encouraged to rest and maintain hydration. The preferred antipyretic and analgesic is

FIGURE 2 Microcephaly: associated with Zika virus infection in pregnancy

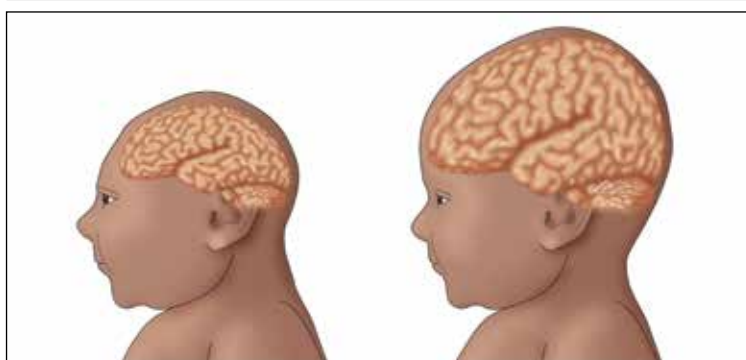


Illustration depicts a child with congenital microcephaly (left) and one with head circumference within the mean SD (right).

acetaminophen (650 mg orally every 6 hours or 1,000 mg orally every 8 hours). Aspirin should be avoided until dengue infection has been ruled out because of the related risk of bleeding with hemorrhagic fever. Nonsteroidal anti-inflammatory drugs should be avoided in the second half of pregnancy because of their effect on fetal renal blood flow (oligohydramnios) and stricture of the ductus arteriosus.

CASE 1 Continued

Given this patient's recent travel, exposure to mosquito-borne illness, and clinical manifestations of malaise, rash, and joint pain, you proceed with serologic testing. The RT-PCR test is positive for Zika virus.

What should be the next step in the management of this patient?

Prenatal diagnosis and fetal surveillance

The recent epidemic of microcephaly and poor pregnancy outcomes reported in Brazil has been alarming and demonstrates an almost 20-fold increase in incidence of this condition between 2014–2015.¹⁴ Careful surveillance is needed for this birth defect and other poor pregnancy outcomes in association with the Zika virus. To date, a direct causal relationship between Zika virus infection and microcephaly has not been



Testing is not indicated for women with no history of travel to Zika-infected areas or no unprotected sexual contact with someone exposed to the virus

unequivocally established¹⁵; however; these microcephaly cases have yet to be attributed to any other cause (**FIGURE 2**, page 31.)

Following the outbreak in Brazil, a task force and registry were established to investigate microcephaly and other birth defects associated with Zika virus infection. In one small investigation, 35 cases of microcephaly were reported, and 71% of the infants were seriously affected (head circumference >3 SD below the mean). Fifty percent of babies had at least one neurologic abnormality, and, of the 27 patients who had neuroimaging studies, all had distinct abnormalities, including widespread brain calcifications and cell migration abnormalities, such as lissencephaly, pachyria, and ventriculomegaly due to cortical atrophy.¹⁶

In addition to microcephaly, fetal ultrasound monitoring has revealed focal brain abnormalities, such as asymmetric cerebral hemispheres, ventriculomegaly, displacement of the midline, failure to visualize the corpus callosum, failure of thalamic development, and the presence of intraocular and brain calcifications.¹⁷

In collaboration with the CDC, the American College of Obstetricians and Gynecologists and the Society for Maternal Fetal-Medicine have developed guidelines to monitor fetal growth in women with laboratory evidence of Zika virus infection.¹⁸ Recommendations include having a detailed anatomy ultrasound and serial growth sonograms every 3 to 4 weeks, along with referral to a maternal-fetal medicine or infectious disease specialist.

If the pregnancy is beyond 15 weeks' gestational age, an amniocentesis should be performed in symptomatic patients and in those with abnormal ultrasound findings. Amniotic fluid should be tested for Zika virus with RT-PCR (**FIGURE 3**).¹² The sensitivity and specificity of amniotic fluid RT-PCR in detecting congenital infection, as well as the predictive value of a fetal anomaly, remain unknown at this time. For this reason, a patient must be counseled carefully regarding the benefits of confirming intrauterine infection versus the slight risks of premature

rupture of membranes, infection, and pregnancy loss related to amniocentesis.

Once diagnosed, microcephaly cannot be "fixed." However, pregnancy termination is an option that some parents may choose once they are aware of the diagnosis and prognosis of microcephaly. Moreover, even for parents who would not choose abortion, there may be considerable value in being prepared for the care of a severely disabled child. Microcephaly has many possible causes, Zika virus infection being just one. Others include genetic syndromes and other congenital infections, such as cytomegalovirus (CMV) infection and toxoplasmosis. Amniocentesis therefore may help the clinician sort through these causes. For both CMV infection and toxoplasmosis, certain antenatal treatments may be helpful in lessening the severity of fetal injury.

CASE 2 Pregnant patient has travel plans

A 34-year-old woman (G1P0) presents to you for her first prenatal visit. She mentions she plans to take a cruise through the Eastern Caribbean in 2 weeks. Following the history and physical examination, what should you tell this patient?

Perinatal counseling: Limiting exposure is best

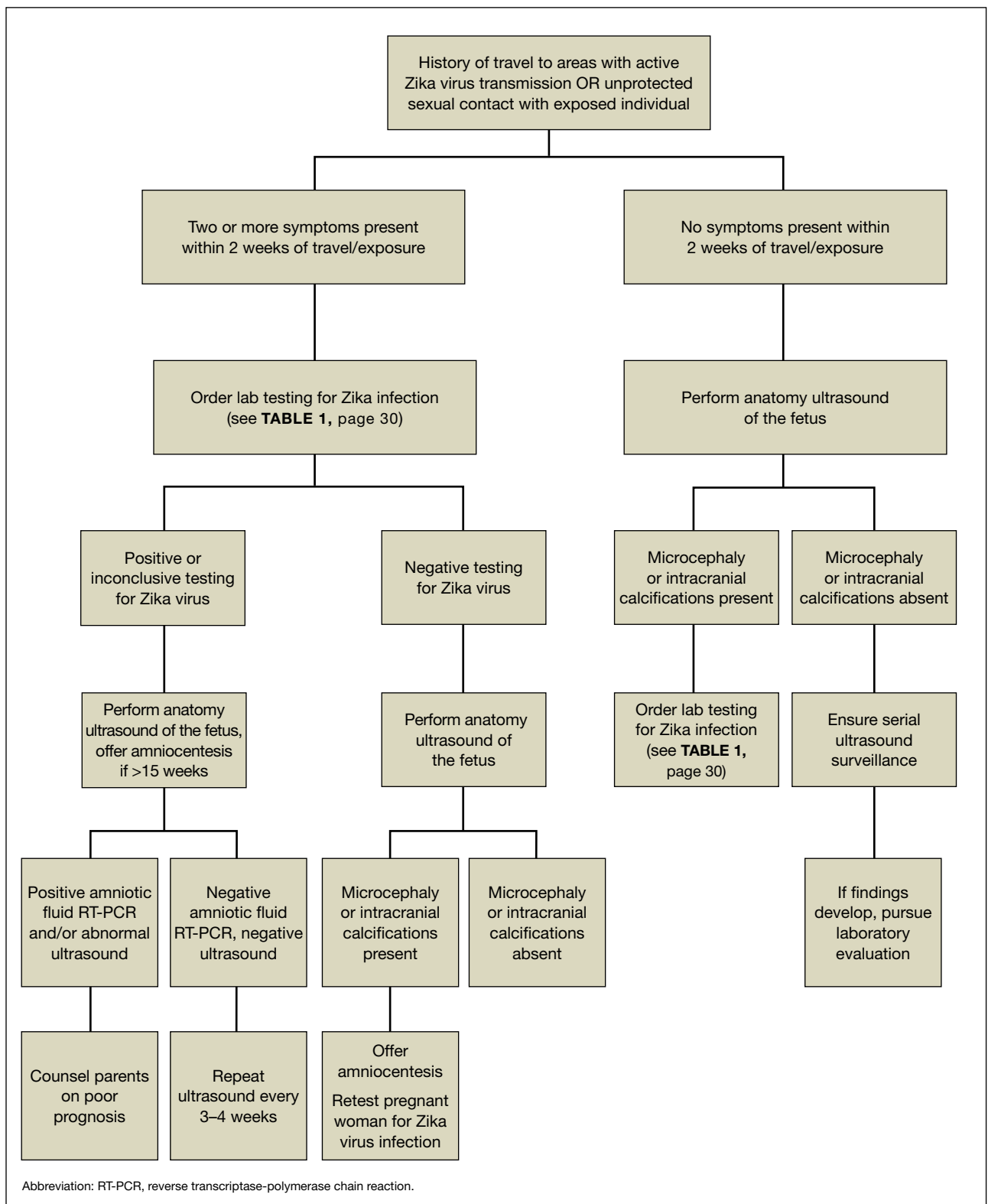
As mentioned, there is currently no treatment, prophylactic medication, or vaccination for Zika virus infection. Because of the virus's significant associations with adverse pregnancy outcomes, birth defects, and fetal loss, the CDC has issued a travel advisory urging pregnant women to avoid travel to areas when Zika virus infection is prevalent. Currently, Zika virus outbreaks are occurring throughout South and Central America, the Pacific Islands, and Africa, and the infection is expected to spread, mainly due to international air travel. If travel to these areas is inevitable, women should take rigorous precautions to avoid exposure to mosquito bites and infection (**TABLE 2**, page 34).

If a woman was infected with laboratory-confirmed Zika virus infection in a prior pregnancy, she should not be at risk for



There is currently no treatment, prophylactic medication, or vaccination for Zika virus infection

FIGURE 3 Algorithm for evaluation and management of pregnant women with exposure to Zika virus infection¹²



CONTINUED ON PAGE 34

TABLE 2 Mosquito avoidance strategies

- Stay protected during the entire day
- Remain indoors
- Stay in air-conditioned rooms
- Wear long-sleeved shirts and long pants
- Use DEET-containing insect repellents*
- Apply permethrin to clothing
- Avoid exposure to stagnant water
- Use mosquito netting when sleeping

*Insect repellents containing DEET, picaridin, and IR3535 are safe in pregnancy when used as directed.


Source: Centers for Disease Control and Prevention. Zika virus: prevention. <http://www.cdc.gov/zika/prevention/index.html>. Published June 1, 2015. Accessed February 12, 2016.

Abbreviation: DEET, N,N-diethyl-meta-toluamide.

congenital infection during her next pregnancy. This is mainly because the period of viremia is short-lived and lasts approximately 5 to 7 days.²

Further, based on documented sexual transmission of the virus, pregnant women should abstain from sexual activity or should consistently and correctly use condoms with partners who have Zika virus infection or exposure to the virus until further evidence is available.

Stay informed

Zika virus infection is now pandemic; it has evolved from an isolated disease of the tropics to one that is sweeping the Western hemisphere. It is being reported daily in new locations around the world. Given the unsettling association of Zika virus infection with birth defects, careful obstetric surveillance of exposed or symptomatic patients is imperative. Clinicians must carefully screen patients with potential risk of exposure and be prepared to offer appropriate perinatal counseling and diagnostic testing during pregnancy. 

References

1. Dyer O. Zika virus spreads across Americas as concerns mount over birth defects. *BMJ*. 2015;351:h6983.
2. Centers for Disease Control and Prevention. Zika virus. Atlanta, GA: US Dept of Health and Human Services; 2015. <http://www.cdc.gov/zika/index.html>. Accessed February 12, 2016.
3. Bogoch II, Brady OJ, Kraemer MU, et al. Anticipating the international spread of Zika virus from Brazil. *Lancet*. 2016;387(10016):335-336.
4. Duffy MR, Chen TH, Hancock WT, et al. Zika virus outbreak on Yap Island, Federated States of Micronesia. *N Engl J Med*. 2009;360(24):2536-2543.
5. Besnard M, Lestere S, Teissier A, Cao-Lormeau V, Musso D. Evidence of perinatal transmission of Zika virus, French Polynesia, December 2013 and February 2014. *Euro Surveill*. 2014;19(13):pii:20751.
6. Centers for Disease Control and Prevention. Zika virus disease in the United States, 2015-2016. <http://www.cdc.gov/zika/geo/united-states.html>. Accessed February 12, 2016.
7. Foy BD, Kobylinski KC, Chilson Foy JL, et al. Probable non-vector-borne transmission of Zika virus, Colorado, USA. *Emerg Infect Dis*. 2011;17(5):880-882.
8. Dallas County Health and Human Services. DCHHS reports first Zika virus case in Dallas County acquired through sexual transmission. <http://www.dallascounty.org/department/hhs/press/documents/PR2-2-16DCHHSReportsFirstCaseofZikaVirusThroughSexualTransmission.pdf>. Accessed February 3, 2016.
9. Ministry of Health, Manuatu Hauora. Zika virus. <http://www.health.govt.nz/our-work/diseases-and-conditions/zika-virus>. Accessed January 13, 2016.
10. Oehler E, Watrin L, Larre P, et al. Zika virus infection complicated by Guillain-Barre syndrome—case report, French Polynesia, December 2013. *Euro Surveill*. 2014;19:4-6.
11. Centers for Disease Control and Prevention. Zika virus: transmission. <http://www.cdc.gov/zika/transmission/index.html>. Accessed January 20, 2016.
12. Petersen EE, Staples JE, Meaney-Delamn, D et al. Interim guidelines for pregnant women during a Zika virus outbreak—United States, 2016. *MMWR Morb Mortal Wkly Rep*. 2016;65(2):30-33.
13. Oduyobo T, Petersen EE, Rasmussen SA, et al. Update: interim guidelines for health care providers caring for pregnant women and women of reproductive age with possible Zika virus exposure—United States, 2016. *MMWR Morb Mortal Wkly Rep*. 2016;65(5):122-127.
14. Pan American Health Organization, World Health Organization. Epidemiological alert: neurological syndrome, congenital malformations, and Zika virus infection. Implications for public health in the Americas. December 1, 2015. http://www.paho.org/hq/index.php?option=com_docman&task=doc_view&Itemid=270&gid=32405&lang=en. Accessed January 13, 2016.
15. European Centre for Disease Prevention and Control. Rapid risk assessment: Zika virus epidemic in the Americas: potential associations with microcephaly and Guillain-Barré syndrome. December 10, 2015. <http://ecdc.europa.eu/en/publications/Publications/zika-virus-americas-association-with-microcephaly-rapid-risk-assessment.pdf>. Accessed January 13, 2016.
16. Schuler-Faccini L, Ribeiro EM, Feitosa IM, et al; Brazilian Medical Genetics Society—Zika Embryopathy Task Force. Possible association between Zika virus infection and microcephaly—Brazil, 2015. *MMWR Morb Mortal Wkly Rep*. 2016;65(3):59-62.
17. Oliveira Melo AS, Malinger G, Ximenes R, Szejnfeld PO, Alves Sampaio S, Bispo de Filippis AM. Zika virus intrauterine infection causes fetal brain abnormality and microcephaly: tip of the iceberg? *Ultrasound Obstet Gynecol*. 2016;47(1):6-7.
18. American College of Obstetricians and Gynecologists. Immunization for women. ACOG update on Zika virus. <http://www.immunizationforwomen.org>. Accessed January 20, 2016.



Be prepared to offer appropriate perinatal counseling and diagnostic testing during pregnancy

ON THE WEB

Find Zika virus infection resources with this article at obgmanagement.com