

# Hypersensitivity vasculitis group (HVG)

## *A case-oriented review of a continuing clinical spectrum*

Leonard H. Calabrese, D.O.  
John D. Clough, M.D.

*Department of Rheumatic and Immunologic Diseases*

*Department of Immunopathology*

Since the original clinical and pathologic description of Kussmaul and Maier<sup>1</sup> over a century ago, vasculitis has remained a formidable problem. Premortem diagnosis remains notoriously difficult, treatment is still fraught with significant morbidity and mortality, and its classification remains controversial at best.

Despite these difficulties, significant advances have been made in the area of pathogenesis. Three observations are largely responsible for this added insight: (1) the elucidation of the pathogenic role of immune complexes in serum sickness;<sup>2</sup> (2) the recognition that many connective tissue diseases, e.g., rheumatoid arthritis (RA), systemic lupus erythematosus (SLE), which are frequently accompanied by vasculitis, are characterized by immune complexes;<sup>3</sup> and (3) the identification of a few putative antigens, e.g., Hb<sub>s</sub>Ag, responsible for certain forms of arteritis.<sup>4</sup> All of these observations have given credence to the immune complex theory of vascular inflammation. Furthermore, recent advances in the clinical laboratory have enabled clinicians to monitor immune complex levels, aiding both in diagnosis and treatment.<sup>5</sup>

This discussion deals with a subgroup of the vasculitic syndromes that have been variously termed allergic vasculitis, allergic angiitis, and leu-

kocytoclastic vasculitis. Furthermore, other well-defined syndromes such as Henoch-Schönlein purpura and essential cryoglobulinemia have frequently been included in this classification because of certain clinical and pathologic similarities, especially the nearly universal involvement of the skin, and the presence of small vessel inflammation with varying amounts of nuclear debris (leukocytoclasia). We believe that the vascular damage induced by immune complexes is a dynamic phenomenon that frequently, however, assumes characteristic anatomic distributions with resultant clinical manifestations allowing classification. We have chosen the term hypersensitivity vasculitis group (HVG) to encompass all vasculitic syndromes that demonstrate universal involvement of the skin with small vessel vasculitis and leukocytoclasia. The term hypersensitivity has been retained since it now appears that all immune complex-mediated vascular syndromes occur in response to antigens, whether exogenous (drug, microbe) or endogenous (tumor, DNA). We hope to demonstrate, using illustrative cases, the advantage of such grouping with regard to differential diagnosis, clinical assessment and treatment, as well as to point out the limitations of such a classification in trying to deal with a dynamic process. In addition, the immune complex theory of vascular inflammation will be reviewed.

### Classification

All attempts to classify the vasculitides in purely clinical, pathological, or immunologic terms have failed to gain universal acceptance. Clinical classifications have traditionally been based upon the presence or absence of key organ system involvement,<sup>6</sup> i.e., lung, skin, whereas pathologic classifications

have concentrated either on the caliber of vessel involved,<sup>7</sup> character of the inflammatory infiltrate,<sup>8</sup> or depth of the cutaneous vascular involvement. Immunologic classifications have keyed on identification of specific antigens or demonstration of immune complexes or hypocomplementemia.<sup>9</sup> Although it is beyond the scope of this discussion to analyze the shortcomings of these respective systems, it is imperative that clinicians appreciate them in order to interpret clinical and anatomic pathologic data correctly. Such understanding allows optimal application of currently available diagnostic and therapeutic techniques.

We currently favor a modification of the classification of Fauci et al<sup>10</sup> (*Table 1*). The blending of clinical, pathological and immunologic features of the vasculitides in this classification renders it both understandable and functional. Its major distinction from previous classifications has been the combining of the classic polyarteritis syndrome (which spares the lungs) and the Churg-Strauss (allergic granulomatosis) syndrome (which commonly involves the lungs) under one heading and more importantly, the recognition of the frequently encountered overlap syndrome (which has features of both). Although it is functional, this system may not be totally accurate if indeed the Churg-Strauss syndrome carried a more favorable prognosis than classic polyarteritis nodosa (PAN) as suggested by recent data.<sup>11</sup>

*Hypersensitivity vasculitis group (HVG); a unifying hypothesis.* The term hypersensitivity vasculitis is a misnomer and actually is applied to a melange of clinical syndromes sharing certain clinical and pathologic features. The term originated from the observation that the inflammatory state, now known to be

**Table 1.** Spectrum of vasculitides

---



---

Polyarteritis nodosa group of systemic necrotizing vasculitis
Classic polyarteritis nodosa
Allergic granulomatosis (Churg-Strauss syndrome)
Systemic necrotizing vasculitis—"overlap syndrome"
Hypersensitivity vasculitis group
True hypersensitivity vasculitis
Henoch-Schönlein purpura
Mixed cryoglobulinemia with vasculitis
Vasculitis with connective tissue disease
Vasculitis associated with malignancies
Urticarial vasculitis (hypocomplementemic vasculitis)
Vasculitis associated with other primary disorders
Wegener's granulomatosis group
Classical Wegener's granulomatosis
Lymphomatoid Wegener's granulomatosis
Limited Wegener's granulomatosis
Necrotizing sarcoid granulomatosis
Giant-cell arteritis group
Temporal arteritis
Takayasu's arteritis
Mucocutaneous lymph node syndrome
Miscellaneous vasculitides

---



---

characterized by immune complexes, could frequently be traced to a precipitating antigen such as a drug or microorganism. As our knowledge of immune complex-mediated tissue injury grew, it became clear that clinical and pathologic features observed after an allergic vasculitic reaction to a drug such as sulfonamide could be mimicked by a variety of other antigen-antibody systems, both endogenous and exogenous, i.e., tumor, rheumatoid factor, anti-DNA. The vasculature can respond to mediators in a limited variety of ways and the morphology of the involved vessel and the character of the inflammatory infiltrate observed on isolated pathologic specimens can rarely, if ever, indicate an etiologic diagnosis. It may merely suggest a particular type of immunologic damage. Only when these data are coupled with detailed knowledge of the clinical situation (i.e., organ involvement, history of antigenic exposure, associated clinical conditions) and laboratory data can a specific etiology

be suspected. Often the precise etiology is never found and we have to be satisfied with observing the activity of the vasculitic process and the degree of target organ involvement.

The features that separate the hypersensitivity group from the remainder of the vasculitides are both clinical and pathologic and are not absolute. Clinically, the most important is the nearly universal presence of skin involvement, of which the most common form is palpable purpura (*Fig. 1*). These raised, purpuric spots range in size from pinpoints to several centimeters and fail to blanch with pressure. Although palpable purpura is highly suggestive of the hypersensitivity group, it is not specific since it has been seen occasionally in some granulomatous conditions such as Wegener's granulomatosis.<sup>12</sup> Other skin manifestations that may also be seen in this group include ulcerations, nodules, hemorrhagic vesicles and bullae, and chronic urticaria. Pathologically, two features are suggestive of the hypersen-

sitivity group: small vessel involvement and the presence of leukocytoclasia (nuclear debris) in the acute inflammatory infiltrate (*Fig. 1*). The caliber of vessel involvement (generally small, less than 1 mm in diameter, especially postcapillary venules and small arteries) is useful in separating this entity from PAN, which usually involves medium-sized muscular arteries.<sup>7,13</sup> This explains why microaneurysms are not observed in hypersensitivity vasculitis, making diagnosis by means of arteriography unlikely. Lastly, much has been said regarding the importance of observing leukocytoclasia on biopsy specimens. Although some authors suggest that this feature serves to separate hypersensitivity from PAN groups,<sup>14,15</sup> others<sup>16</sup> have disputed this point. The mere presence or absence of leukocytoclasia can neither confirm nor exclude a specific diagnosis but should be considered as an important piece of data when viewing the entire picture. For instance, finding nuclear debris in the muscle biopsy speci-

men in a patient with microaneurysms with medium-sized vessel involvement and no skin lesions would not permit a diagnosis of hypersensitivity arteritis, but leukocytoclasia observed in a skin biopsy specimen of a patient with palpable purpura is suggestive of hypersensitivity.

### Specific diseases

Diseases that frequently share the above features (palpable purpura, small vessel involvement, and leukocytoclasia) are listed below.

1. True hypersensitivity vasculitis. This term should be limited to vasculitic syndromes following exogenous antigenic exposure, e.g., drug, infection, insect bite, immunization, and classical serum sickness.
2. Henoch-Schönlein purpura.
3. Essential cryoglobulinemia.
4. Vasculitis associated with connective tissue disease, i.e., SLE, RA, Sjögren's syndrome.

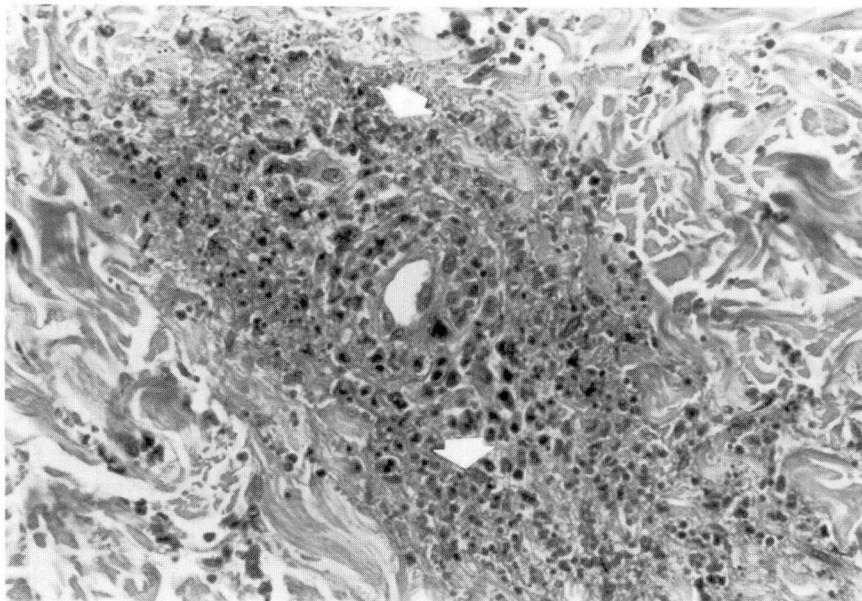


Fig. 1. Acute leukocytoclastic vasculitis. Arrows point to nuclear debris.

5. Vasculitis associated with malignancies, e.g., myeloma, leukemia, lymphoma, solid tumors.

6. Urticarial vasculitis (hypocomplementemic vasculitis).

7. Vasculitis associated with other primary diseases in which immune complexes have been identified but are of questionable pathologic significance (primary biliary cirrhosis, inflammatory bowel disease, intestinal bypass, Goodpasture's syndrome, and retroperitoneal fibrosis).

#### 1. True hypersensitivity angitis.

This syndrome, when fully developed, is fairly characteristic (*Table 2*). Hypersensitivity reactions to most exogenous antigens commonly share these features, but this is not always true. Exceptions include the classic PAN syndrome ascribed to amphetamines<sup>17</sup> and the chronic vasculitic syndrome observed during lepromatous infections.<sup>18</sup> Furthermore, the spectrum of immunologic reactions to hepatitis B should be termed hypersensitivity, but the clinical picture is highly variable, ranging from simple arthralgias with palpable purpura or chronic urticaria, to a life-threatening PAN-like syndrome.<sup>19-21</sup> This demonstrates the difficulty in attributing specific syndromes to a specific antigen. This observation also reflects the dynamic nature of immune complex injuries and helps to explain why all

rigid classifications of vasculitis are not accepted by clinicians.

The term hypersensitivity vasculitis should be limited to patients with the features outlined in *Table 2*. Although cutaneous lesions are involved in most cases, visceral involvement with significant morbidity and mortality may be observed.<sup>22</sup> Ideally, the syndrome should be traced to a precipitating exogenous antigen, but this is not always possible. *Table 3* lists documented causes of hypersensitivity vasculitis.

#### Case 1.

A 50-year-old white man was admitted to The Cleveland Clinic Foundation because of a rash and fever of 8 days' duration. He had had asthma in childhood (no symptoms for 20 years), and a kidney stone 10 years ago. Four weeks before his current disease, he had been taking sulfamethoxazole and trimethoprim for a prostatic infection manifested by dribbling and dysuria. His current problem began abruptly with fever, chills, malaise, and nausea. After 3 days, an evenly distributed maculopapular eruption appeared that nearly covered his body. On day 6, the eruption persisted, and the liver was found to be slightly enlarged. The white cell count (WBC) was 13,600/mm<sup>3</sup> with 11% eosinophils. The next day, his fever rose to 39 C, the eruption expanded and some facial and cervical edema became evident. He was hospitalized and found to have a serum glutamic oxaloacetic transaminase (SGOT) of 212 mU/ml (upper limit of normal, 40 mU/

**Table 2.** Clinicopathologic features of true hypersensitivity vasculitis

- 
1. Small vessel vasculitis of dermal vessels.
  2. Inflammatory infiltrate characterized by polymorphonuclear leukocytes with nuclear debris (leukocytoclasia). May have variable degree of lymphocytic infiltration.
  3. Near-universal presence of characteristic skin disorders (i.e., palpable purpura, chronic urticaria).
  4. All skin lesions usually at one anatomic stage.
  5. Occasional involvement of any visceral organ.
  6. Frequently traced to a precipitating antigen; occurring 7-10 days following initial exposure or even sooner after reexposure.
  7. Strong evidence for immune complex mechanism, i.e., detection of soluble immune complexes, identification of immunoreactants in tissue, hypocomplementemia.
  8. Usually self-limited but may be recurrent, chronic or at times fatal.
-

**Table 3.** Antigenic exposures causing hypersensitivity vasculitis (HSV)

I. Drugs <sup>14, 22-25</sup>	II. Infections <sup>26</sup>	III. Chemicals
Penicillin	Streptococcus <sup>27</sup>	Insecticides <sup>22</sup>
Sulfa	Staphylococcus <sup>26, 28</sup>	Herbicides <sup>22</sup>
Iodides	Subacute bacterial endocarditis <sup>29</sup>	
Griseofulvin	Meningococcus <sup>30</sup>	IV. Immunizations
Quinidine	Leprosy <sup>31</sup>	Influenza <sup>33, 34</sup>
Tetracycline	Malaria <sup>31</sup>	Allergy <sup>35</sup>
Dilantin	Tuberculosis <sup>31</sup>	
Phenylbutazone	Hepatitis B <sup>4, 19-21</sup>	V. Miscellaneous
Allopurinol	Cytomegalovirus <sup>32</sup>	Foreign protein
ASA phenacetin	Epstein-Barr virus <sup>32</sup>	Insect bites
Phenothiazine	Others <sup>26, 31, 32</sup>	Others

ml), serum glutamic pyruvic transaminase (SGPT) 935 mU/ml (upper limit of normal, 40 mU/ml), and alkaline phosphatase 258 mU/ml (upper limit of normal, 85 mU/ml). The WBC was 18,000/mm<sup>3</sup> with 13% eosinophils. A lumbar puncture was unremarkable. He was transferred to the Cleveland Clinic with suspected hepatitis.

On admission his temperature was 37 C. Facial edema was observed. There was no abdominal pain or arthritis. Laboratory evaluation disclosed a WBC of 20,000/mm<sup>3</sup> with 16% eosinophils; SGOT, 188 mU/ml; SGPT, 507 mU/ml, alkaline phosphatase, 284 mU/ml; and creatinine phosphokinase (CPK), 201 mU/ml (upper limit of normal, 180 mU/ml). Urinary sediment and chest roentgenogram were normal. The next day, right arm paralysis and mental deterioration suddenly developed. Dermatological examination disclosed palpable purpura on both upper extremities. His general condition deteriorated rapidly. Lung and kidney studies were unremarkable. Cranial computed tomography and lumbar puncture revealed no abnormalities.

The diagnosis of leukocytoclastic vasculitis probably secondary to sulphamethoxazole was presumed. Therapy was begun with plasmapheresis 2 L/day for 3 days followed by methylprednisolone, 1 g intravenously. After the second day his condition improved rapidly. He became more alert and the skin lesions began to subside. Plasmapheresis was stopped after three treatments and he was given oral prednisone, 100 mg/day. By 96

hours, the cutaneous lesions had cleared, and the blood count, liver function tests and CPK had returned to normal readings. His right arm, however, was still paralyzed. Results of tests of blood drawn before therapy were negative for hepatitis A and hepatitis B antigens and monospot; other serological results and cultures showed no abnormalities. Antinuclear antibody, anti-DNA, and rheumatoid factor studies were all negative. No immune complexes were detected by C1q binding. Complement levels were normal.

Skin biopsy performed before therapy disclosed lymphocytic vasculitis with occasional polymorphonuclear infiltrate, eosinophils, and nuclear dust with occasional extravasation of red blood cells.

*Comment.* This case demonstrates all of the features of HVG, including palpable purpura and small vessel vasculitis with leukocytoclasia. Since the presumed inciting antigen is exogenous (i.e., drug-induced), it represents true hypersensitivity vasculitis. Plasma exchange is theoretically the ideal treatment for this condition, having the dual role of removing preformed immune complexes and exogenous nonreplicative antigen, presumably hastening the end of an ongoing immune response.

2. **Henoch-Schönlein purpura (HSP).** The inclusion of HSP under the hypersensitivity group by most authors is an excellent example of the heteroge-

neity of our classification and of a point raised earlier regarding the limited ability of a vessel to respond to immunologic damage. The HSP syndrome is considered a subtype of HSV because all patients manifest palpable purpura, small vessel vasculitis and leukocytoclasia. However, if one searches for the additional features listed in *Table 2* for classical HSV, one is hard pressed to find many similarities. HSP, a disease primarily of children and young adults, is seen most often in the spring, frequently following an upper respiratory tract infection.<sup>35</sup> Gastrointestinal bleeding and colicky abdominal pain are common. Renal impairment in the form of a proliferative glomerulonephritis, generally mild and self-limiting, may infrequently be severe and persistent.<sup>36,37</sup> Although HSP is included under the heading of HSV because of the universal presence of palpable purpura displaying the usual histopathology of small vessel involvement with leukocytoclasia, it differs significantly in that IgA-containing immune complexes may be a characteristic feature of HSP. These have been identified in glomerular and vascular lesions and recently in the sera of a majority of patients with this syndrome.<sup>38,39</sup> These IgA-containing immune complexes appear capable of activating the alternative pathway of complement.<sup>40</sup> HSP is included in the HVG classification because it demonstrates the three unifying features of the group, i.e., palpable purpura, small vessel vasculitis, and leukocytoclasia. Pathophysiologically, however, it is distinct, apparently mediated by IgA-containing immune complexes. This serves to reemphasize that vascular response to noxious stimuli is limited.

### Case 2.

A 64-year-old white man was seen in the outpatient department of the Cleveland

Clinic in October 1979. He had been transferred from another hospital for evaluation of fever, rash, abdominal pains, and hematuria. His current illness had started in July 1979 as a pruritic eruption over both lower extremities. A week later, palpable, erythematous, nonpruritic lesions appeared over the buttocks and lower extremities. At the same time, he became febrile and suffered acute, recurrent, severe generalized abdominal pains. His private physician examined him and found microscopic hematuria. A complete blood count revealed: hemoglobin, 9.8 g/dl; WBC, 8700/mm<sup>3</sup>; and platelets, 340,000/mm<sup>3</sup>. Upper and lower gastrointestinal roentgenographic series showed no abnormalities. He was transferred to the Cleveland Clinic.

His medical history included severe atherosclerotic heart disease with class III angina pectoris. There was no recent indication of viral infection or significant drug exposure. For 5 years symmetric, intermittent joint pain accompanied by occasional swelling had been well controlled on prednisone, 5 mg daily.

A physical examination at that time revealed palpable purpura over the buttocks and lower extremities but was otherwise unremarkable.

Laboratory evaluation included hemoglobin, 10.3 g/dl; WBC, 10,100/mm<sup>3</sup>; platelet count, 310,000/mm<sup>3</sup>; and sedimentation rate (Westergren), 70 mm/hr. Urinalysis revealed more than 25 red blood cells per high-power field and 1.1 g protein/24 hours in the urine. Serum creatinine was 1.1 mg/dl. Biopsy specimen of a purpuric lesion revealed leukocytoclastic vasculitis by light microscopy. Immunofluorescent studies of the skin specimen were negative for IgG, IgA, IgM, C3, or fibrinogen. Antinuclear antibody, rheumatoid factor, and anti-DNA antibody were all undetectable in serum. Immune complexes as assayed by C1q binding and quantitative cryoglobulins were within normal limits. He was given prednisone, 40 mg daily, and told to return in one month.

By that time, the skin lesions had completely cleared and the gastrointestinal

symptoms had greatly diminished. It was decided to taper prednisone over the next several months. Approximately 10 weeks later he again appeared in the outpatient department; prednisone had been decreased to 40 mg and 10 mg on alternate days. At this visit, he mentioned recent onset of high spiking fevers, gross hematuria, and generalized fatigue and weakness. He was hospitalized, and the Westergren sedimentation rate at this time was 105 mm/hr. Urinary protein excretion was 564 mg/24 hours and creatinine clearance was 71 ml/min/1.73 m<sup>2</sup>. Serum creatinine level was 1.2 mg. Cutaneous vasculitis was again prominent on the buttocks and lower extremities and was also seen on the upper extremities. Biopsy specimen of the skin lesion again revealed leukocytoclastic vasculitis by light microscopy. A percutaneous renal biopsy specimen showed minimal changes consisting mostly of some glomerulosclerosis and mononuclear inflammatory infiltrate. Immunofluorescent studies were negative for IgG, IgA, IgM, and C3, but immunochemical staining revealed some finely granular deposits of IgA in the mesangial area. The patient was given cyclophosphamide, 100 mg daily, and prednisone, 30 mg and 15 mg on alternate days, and discharged to the care of his private physician. Over the ensuing year the patient had numerous exacerbations of fever, skin lesions, hematuria, and gastrointestinal pain. Because of profound leukopenia, Cytosan was discontinued, but disease was difficult to control on corticosteroids alone. In December of 1980 the patient died at home. Autopsy was not performed but disease was presumed to be active.

*Comment.* The initial presentation of palpable purpura, abdominal pain, and renal disease in a child is classical for Henoch-Schönlein purpura. Resistant progressive systemic vasculitis leading to death is unusual in children, but often encountered in adults. This case again demonstrates all of the features of the HV group, i.e., palpable purpura, small vessel vasculitis, and leukocytoclasia.

**3. Cryoglobulinemia.** Cryoglobulins are serum proteins that precipitate at temperatures below 37 C. The term cryoglobulinemia has been used to refer to both a pathophysiologic state (presence of cryoglobulins in the blood) and to a heterogeneous clinical syndrome (essential cryoglobulinemia), and this has been the source of some confusion to clinicians. Cryoglobulins must be viewed in light of their content. Many proteins may precipitate in the cold, including cryofibrinogen, C-reactive protein-albumin complexes, serum fibronectin or heparin-insoluble protein, and others.<sup>41-43</sup> In vasculitis and connective tissue diseases, we are interested primarily in cryoproteins containing immunoglobulin. Therefore, detection of a cryoprotein is meaningless without some qualitative analysis of its content. Cryoprecipitates may be classified by immunoglobulin content. Brouet et al<sup>44</sup> have proposed three basic classes: (I) monoclonal, in which a single homogeneous immunoglobulin is present; (II) mixed, with two or more immunoglobulins, one of which is homogeneous; (III) polyclonal, containing one or more classes of immunoglobulin, none of which is homogeneous. Immunoproliferative disorders are most frequently seen with Types I or II, and autoimmune with Type III. That these immunoglobulins precipitate at cold temperatures has little to do with the resultant clinical symptoms, especially in Type II or III cryoproteins. Although some may precipitate at temperatures as high as 35 C, most require prolonged incubation at 4-5 C. Cold-induced symptoms (i.e., acrocyanosis, cold-induced urticaria) are rarely observed in the absence of high concentrations of Type I cryoprecipitates as seen with lymphoproliferative disorders. Most clinical manifes-

tations in patients with mixed or polyclonal cryoglobulins are secondary to phlogistic effects of immune complexes (i.e., glomerulonephritis, arthritis, vasculitis) and are independent of the physical property of cryoprecipitation.<sup>44, 45</sup> With this in mind, the detection of cryoglobulins should be viewed as simply another method for detecting immune complexes. The disease states in which cryoglobulins have been reported are those in which immune complexes have been found by other antigen nonspecific techniques and include many autoimmune, infectious, renal, hepatic, and malignant disorders.<sup>45</sup>

Cryoglobulin determination requires careful collection and handling of the specimen. Blood should be drawn in a warm syringe and kept at 37 C while being transported to the laboratory; it is then clotted for 60–90 minutes at 37 C and the serum harvested and incubated at 4 C for at least 72 hours. The serum may then be centrifuged and observed for a visible precipitate, or, preferably, the pellet should be washed and evaluated by microprotein assay. Normal serum contains 20–80  $\mu\text{g}/\text{cc}$  cryoproteins.<sup>41–46</sup> When properly performed, this assay is as sensitive as Raji cell or C1q binding.<sup>47</sup> In necrotizing vasculitis, its sensitivity is difficult to assess since most patients with cryoglobulins and vasculitis have been selected only for the presence of cryoglobulins. Cream,<sup>48</sup> however, detected cryoglobulins in 15 of 35 cases of necrotizing arteritis. The term essential cryoglobulinemia or mixed cryoglobulinemia should be used with caution and only after careful clinical examination and extensive analysis of the purified cryoprotein. Often, the amount is insufficient for analysis and small, monoclonal components may be overlooked. This is

important because patients with B-cell malignancies may elaborate monoclonal cryoproteins and manifest a vasculitis identical to that seen in essential disease (Case 3).<sup>49, 50</sup> Regardless of these limitations, evaluation of a patient with features of the hypersensitivity group should always include multiple tests for immune complexes including the cryoglobulins.

### Case 3.

A 61-year-old black man presented to the Cleveland Clinic in July 1980, with paresthesias of the feet. In July 1979, shortly after beginning treatment with thiazide diuretics for hypertension, palpable purpura developed around both ankles. A few days later a lesion ulcerated over the lateral malleolus on the left ankle, which eventually healed spontaneously. At this time he began to complain of numbness and tingling of both feet. In August 1979 he was admitted to a local hospital where biopsies of the gastrocnemius muscle and sural nerve were performed and showed neurogenic atrophy and perivascular inflammation in several muscular arteries without frank necrosis. A presumptive diagnosis of polymyositis was made. He was treated with prednisone, 30 mg/day, which was gradually decreased over a period of a few months but paresthesias of the feet continued. He had no history of alcohol abuse, diabetes mellitus, previous liver disease or other drug ingestion.

At hospital admission, his blood pressure was 150/70 mm Hg, with a pulse of 64 beats/min. Small splinterlike hemorrhages were noted under the nail beds and several purpuric papular lesions were seen over the medial and lateral aspects of the right heel. Evidence of a healed ulcer was noted on the lateral malleolus of the left ankle. Neurological examination revealed absent pin sensation in the toes with hyperesthesias in both lower extremities from the mid-calf downward, and impairment of vibration and position sensation of both feet. The remainder

of the physical examination was unremarkable.

Laboratory evaluation at that time revealed hemoglobin, 12.8 g/dl; WBC, 10,300/mm<sup>3</sup>; and platelet count, 343,000/mm<sup>3</sup>. Total hemolytic complement was 116 units (normal, 70-190 units) and C1q binding was elevated at 137 units/ml (normal, less than 74 units/ml). Rheumatoid factor was strongly positive at 183 RLS (relative light-scattering units, normal less than 10 RLS). Antinuclear antibody study was positive at 1:40 dilution. Muscle enzymes including CPK and aldolase were within normal limits. An electromyographic examination of the lower extremities was consistent with a polyneuropathy. Muscle biopsy specimen of the left gastrocnemius muscle showed acute necrotizing arteritis with minimal myopathic changes. Sural nerve biopsy also demonstrated necrotizing vasculitis. Quantitative cryoglobulins composed of IgG and IgM were strongly positive at 620 µg/cc. No monoclonal immunoglobulin was detected. Hepatitis B surface antigen test result was negative.

It was felt that the patient had a vasculitic syndrome secondary to mixed cryoglobulins, and prednisone, 80 mg/day was instituted. One month following therapy, the paresthesias had lessened somewhat, and the cryoglobulins had disappeared, hence the prednisone was reduced. Approximately one month later, he had gangrenous changes of several digits of one hand and was given oral cyclophosphamide. His disease has been well controlled for many weeks and much of the digital ischemia has regressed.

*Comment.* This case demonstrates many of the features of mixed cryoglobulinemia, i.e., purpura, skin ulcerations, and paresthesias. Immune complexes were identified by both cryoprecipitation and C1q binding. It appears that this patient had vasculitic involvement of several calibers of vessels. The purpuric papules around the ankles (no biopsy was performed) probably represented small vessel vasculitis. The muscle and nerve biopsy specimens demon-

strated larger or medium-caliber vessel vasculitis.

On the basis of muscle and nerve biopsy and ultimate development of digital gangrene, this patient's disease could easily have been classified in the systemic necrotizing arteritis-polyarteritis nodosa group as well as in the HVG with mixed cryoglobulins. This case dramatically illustrates the dynamic nature of immune complex-induced vascular inflammation and the failure of defining a disease by simple classification.

**4. Vasculitis associated with connective tissue disease.** Vasculitis is often a prominent part of many of the connective tissue disorders, most notably RA, SLE, Sjögren's syndrome, dermatomyositis, and scleroderma.<sup>3</sup> In the first three disorders, the vasculitis may display some clinical and pathologic features of the HV group, i.e., palpable purpura, small vessel vasculitis, and leukocytoclasia. The vasculitic syndrome observed in these disorders, however, represents a wide spectrum, of which the HSV profile may be only a small part.

In RA the most common vasculitic lesion is nail fold infarct.<sup>51</sup> Pathologically, the vascular lesion is an obliterative endarteritis and does not demonstrate leukocytoclasia.<sup>52</sup> Cutaneous vasculitis may be manifested clinically by palpable purpura, hemorrhagic bullae, or ulcerative papules or plaques. Medium-caliber vessel involvement, similar in morphology to polyarteritis, may be observed in peripheral nerves, the heart, and other visceral organs.<sup>53</sup> In general, patients with vasculitis have a higher incidence of immunoreactants such as rheumatoid factor (both 19S and 7S) and circulating immune complexes as assayed by a variety of techniques (e.g., cryoprecipitation, C1q binding, and

monoclonal rheumatoid factor binding).<sup>54-58</sup>

Systemic lupus erythematosus is the prototype of immune complex diseases, and vascular inflammation may be observed in arteries of virtually any size or occasionally in veins.<sup>59</sup> Periungual and palmar erythema are frequently seen in SLE and represent the most benign end of the vasculitis spectrum. Occasionally, medium-caliber vessel involvement occurs and may lead to digital ischemia and necrosis. Small-vessel (i.e., capillary and venule) involvement results in a clinical picture suggestive of HVG. Rarely, all of these forms of vasculitis can be observed in a single patient, as in Case 4 (Figs. 2-5). Immunoglobulin, DNA and complement have been identified in tissues of patients with SLE.

Sjögren's syndrome is now considered an immune complex disease; in the past it was reported in association with "mixed cryoglobulinemia."<sup>60</sup> We interpret these older reports as simply representing the detection of cryoprecipi-

table immune complexes in the blood of patients with Sjögren's syndrome. With C1q binding assays, Lawley et al<sup>61</sup> identified circulating immune complexes in the majority of patients with Sjögren's syndrome, with or without associated connective tissue disease. Immune complex diseases encountered in these patients include dermatitis, neuropathy,<sup>62</sup> myopathy,<sup>63</sup> and glomerulonephritis.<sup>64</sup> Not infrequently the skin manifestations of this condition take the form of palpable purpura, thus placing it in the hypersensitivity vasculitis group.

#### Case 4.

A 30-year-old man was admitted to the Cleveland Clinic on January 11, 1981 with diffuse skin eruptions, fever, and muscular weakness. Apparently he had been in good health until approximately 4 to 6 months before admission when he experienced fever, malaise, and dyspnea on exertion. Three weeks before admission, he entered a local hospital for a diffuse skin eruption.

On admission to Cleveland Clinic he was acutely ill. Examination of the skin revealed

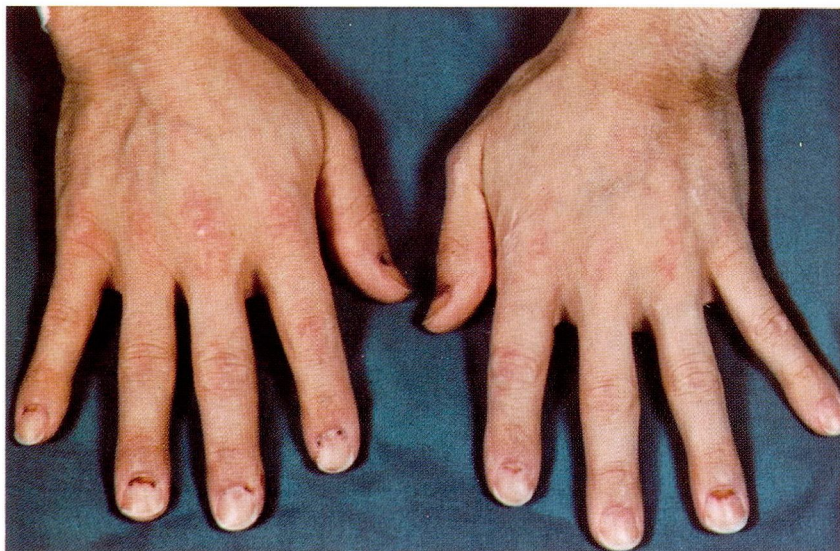
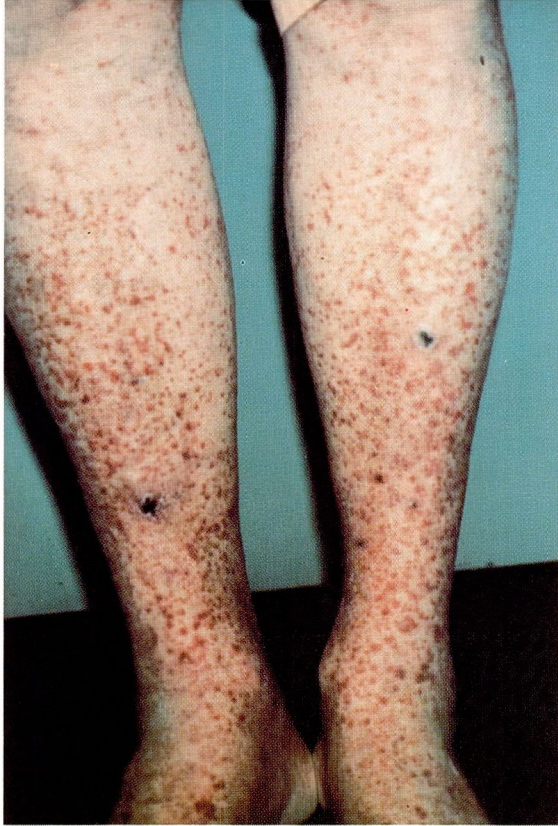
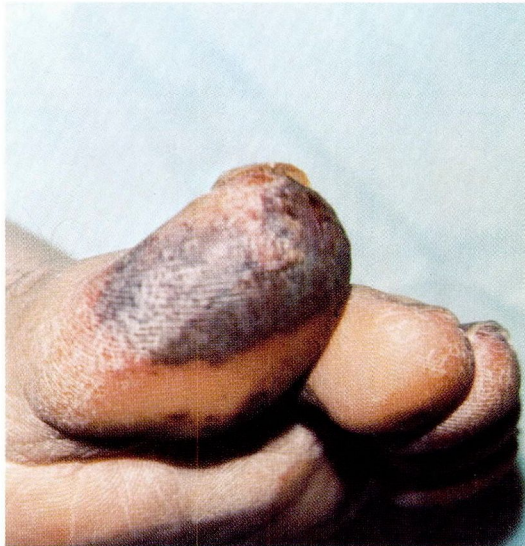Fig. 2. Case 4. Periungual infarcts.



**Fig. 3.** Case 4. Cutaneous vasculitis with palpable purpura.



**Fig. 4.** Case 4. Infarction of the great toe.

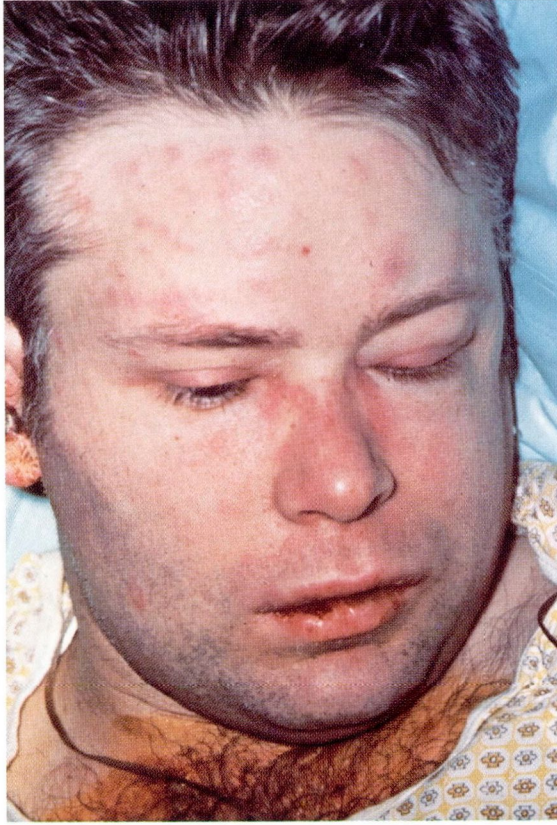

Fig. 5. Case 4. Appearance on admission to Cleveland Clinic. Note infarctive lesion on right ear.

periungual infarcts of both hands. Palpable purpura was noted most prominently over both lower extremities, with scattered areas over the upper chest and arms. Ischemic necrosis was noted on the right ear and there were fixed ischemic changes on several toes (Figs. 2-5). Decreased breath sounds were noted at the bases of both lungs. Cardiac examination revealed a resting tachycardia of 112 beats/min with a loud S3; no murmurs were noted. Abdominal examination was unremarkable. Peripheral pulses were full. Muscle weakness was most pronounced in the hip flexors and shoulders. There was no evidence of peripheral neuropathy. Hematology readings were: hemoglobin, 10.1 g/dl; WBC, 3400/mm<sup>3</sup>; and platelet count, 109,000/mm<sup>3</sup>. Muscle enzymes were elevated: CPK, 5800 mU/ml, and SGOT, 550 mU/ml. A renal function test gave a creatinine of 1.3 mg/dl. Immunologic studies re-

sulted in an antinuclear antibody titer of 1:320, and nDNA binding of 50% (normal = 0); total hemolytic involvement was 29 CH<sub>50</sub> units (normal, 70-190). Immune complexes were detected with C1q binding at 130 units/ml (normal < 62 units/ml), and a quantitative cryoglobulin level of 82 µg/ml (normal < 47 µg/ml). Electromyography of the left upper and lower extremities revealed a generalized myopathy with mild evidence of a generalized peripheral polyneuropathy. Skin biopsy specimen of a lower extremity lesion disclosed dermal vasculitis with leukocytoclasia and fibrinoid necrosis. Over the first 48 hours of hospitalization, the patient exhibited progressive mental deterioration, lethargy, and ischemic changes of the toes. He was treated with plasmapheresis (2-L exchange per treatment for a total of 10 exchanges) during the first 4 weeks of hospitalization. In addition he received high-

dose corticosteroids and a course of 19 mg of mechlorethamine, intravenously. Despite a hectic 2-month hospital course complicated by septicemia, profound thrombocytopenia, leukopenia, and congestive heart failure, his condition gradually improved and he was discharged and given prednisone, 30 mg twice a day. The skin lesions had cleared dramatically, muscle enzymes had returned to normal levels, and he was no longer short of breath. Renal function was moderately well preserved with a serum creatinine of 1.2 mg/dl and a 24-hour urinary protein of 200 mg. Renal biopsy specimen obtained approximately one week before discharge revealed only mesangiopathic glomerulonephritis with minimal proliferation.

*Comment.* This extraordinary case demonstrates the dynamic nature of vasculitis in association with a connective tissue disease (SLE). The periungual infarcts and palpable purpura place this case in the HV group. Larger vessel involvement was also seen, as demonstrated by frank digital ischemia. Unlike the patient in Case 1 who was successfully treated by a short course of limited plasma exchange, this man required multiple plasma exchanges and aggressive immunosuppressive therapy against ongoing immunologic response.

**5. Vasculitis associated with malignancy.** Although uncommon, immune complex disease may be observed secondary to a large variety of tumors.<sup>65</sup> B-cell malignancies may elaborate monoclonal immunoglobulins, which behave as immune complexes causing widespread arteritis.<sup>66, 67</sup> Solid tumors may act as antigenic stimuli eliciting humoral immune responses resulting in high levels of circulating immune complexes.<sup>68</sup> Patients with malignant melanoma, carcinoma, breast carcinoma, esophageal carcinoma, and osteogenic sarcoma have all been found to have high levels of circulating immune com-

plexes when tested by Raji cell assay.<sup>69</sup> Occasionally, these immune complexes may result in disease, such as glomerulonephritis or, more rarely, mononeuritis multiplex.<sup>70, 71</sup> Also, a granulomatous vasculitis of the central nervous system has been described in association with lymphomas, which probably results from hypersensitivity mechanisms, although this has not been conclusively demonstrated.<sup>72</sup>

### Case 5

A 75-year-old white woman presented at the Cleveland Clinic with a one-year history of slightly pruritic, erythematous macules and papules primarily distributed over the lower extremities. There was no history of significant medical illness, previous skin disease, or cold sensitivity. The patient generally felt well and denied fever, night sweats, or weight loss. Medications included allopurinol, 400 mg/day for persistent hyperuricemia.

Physical examination revealed palpable purpura primarily distributed over the lower extremities. There was no significant lymphadenopathy or hepatosplenomegaly. Biopsy specimen of one of the skin lesions disclosed vasculitis of the deep dermal vessels characterized by infiltration with lymphocytes, neutrophils and nuclear dust (leukocytoclasia). Direct immunofluorescence of the skin biopsy specimen revealed coarsely granular deposition of IgM, IgG, trace IgA, C<sub>3</sub>, and kappa but not lambda chains in the vessel walls. Cryoglobulins in high concentrations (6034 µg/cc) were composed of IgG and IgM kappa and possibly trace amounts of IgA kappa chains.

Because of the monoclonal composition of the cryoprecipitates in high concentration, a bone marrow biopsy was obtained. This showed focal areas of poorly differentiated lymphocytic lymphoma. Direct immunofluorescence of the tumor revealed only kappa light chains. That direct immunofluorescence of the lesions demonstrated kappa but not lambda chains is supporting evi-

dence for direct participation of the monoclonal protein.

*Comment.* This patient's disease is an example of vasculitis secondary to cryoprecipitable immunoglobulins accompanying a B-cell malignancy, demonstrating all of the cardinal features of HVG (i.e., palpable purpura, small vessel vasculitis, and leukocytoclasia). Although no clinical features suggested lymphoma other than vasculitis, analysis of the cryoprecipitate was consistent with a Type I cryoprotein and highly suggestive of malignancy. This should emphasize the importance of qualitative cryoprotein analysis and the utility of the classification scheme of the HVG.

**6. Urticarial vasculitis.** At the beginning of this discussion we stated that the HVG of vasculitides refers to a clinically heterogeneous group of syndromes placed together because they share certain anatomic, histopathologic, and clinical features. The nearly universal presence of cutaneous involvement is an important feature that makes topical recognition the key to diagnosis. At this point, it should be readily appreciated that the mere presence of these characteristic features of the HVG in any particular patient is not pathognomonic of any particular syndrome. They simply serve as aids to the clinician in forming a reasonable differential diagnosis when he is familiar with the classification scheme. Although the most common cutaneous manifestation is palpable purpura, the cutaneous vasculitic process may also be seen in the form of bullae, ulcerative lesions, and urticaria. The syndromes discussed in this section share urticaria as the dominant or sole dermatologic manifestation. Originally, it was thought that vasculitis associated with chronic urticaria was characteristic of a distinct clinical syndrome, but it

now appears that urticaria may only represent a peculiar expression of immune complex-induced vascular disease. The clinical syndrome specifically associated with urticarial vasculitis is hypocomplementemic vasculitis<sup>73</sup> or SLE-related syndrome.<sup>74</sup> These patients have chronic urticaria that in biopsy specimens displays small-vessel inflammation, usually with leukocytoclasia. Constitutional symptoms including arthralgia are prominent features. Angioneurotic edema of the face and small bowel is occasionally reported. Renal disease has not been a notable feature, but biopsy specimens in two patients have shown mild membranoproliferative glomerulonephritis with granular deposition of IgG and complement. Cases with these features generally do not satisfy ARA criteria for the diagnosis of SLE, although immunologic studies suggest this as the underlying mechanism.

Serologic studies in these patients usually reveal positive antinuclear antibodies in low to moderate titers but not anti-DNA antibodies. Antibodies directed against Sm, considered pathognomonic of SLE, have been found in several patients.<sup>74</sup> Hypocomplementemia has been a prominent feature in this group, the individual component studies showing a marked depression of C1 through C3 with normal or elevated levels of terminal complement components. More recently, a low molecular weight C1q precipitant (7S) with the characteristics of IgG has been described in many of these patients.<sup>75, 76</sup> Skin biopsy specimens generally reveal granular deposition of immunoglobulin and complement at the dermal-epidermal junction.

In several larger groups of patients with chronic urticaria and vascu-

litis,<sup>77,78</sup> some cases were clinically indistinguishable from idiopathic chronic urticaria, whereas others resembled hypocomplementemic or SLE-related syndrome. In about half of these patients, complement levels were reduced.

In the patients with urticaria, serologic and histopathologic studies reveal an even wider spectrum of disease. In a recent study of 42 consecutive patients with chronic urticaria, 22 (52%) had vasculitis on biopsy specimens; however, no differences between vasculitic and normal patients in the incidence of arthralgia, increased sedimentation rate or hypocomplementemia were noted.<sup>79</sup> In rare instances, other immune complex diseases may manifest urticaria such as infectious mononucleosis,<sup>80</sup> hepatitis,<sup>81</sup> serum sickness,<sup>82</sup> Henoch-Schönlein purpura,<sup>83</sup> essential cryoglobulinemia,<sup>44</sup> or SLE.<sup>84</sup> Unlike palpable purpura, which is virtually pathognomonic of cutaneous small vessel vasculitis, urticaria must be viewed with a higher degree of suspicion necessitating biopsy in all cases if vasculitis is to be proved. Although the detection of C1q binding material may be a marker for the urticarial vasculitic syndrome,<sup>85</sup> it now appears that the spectrum of disease associated with urticarial vasculitis is much larger than originally expected, with some patients demonstrating a paucity of serologic phenomena.

#### Case 6.

A 46-year-old woman presented for evaluation of urticaria of approximately 12 years' duration. She had been in generally good health until the age of 34, when recurrent bouts of generalized urticaria began, involving the extremities and occasionally the lip area. She described the eruption as nonpruritic, elevated, slightly erythematous plaques. Associated with these skin lesions was a sensation of fullness or tightness in the hands, feet, and knees, but no arthralgia or arthritis. She had undergone hypersensitiza-

tion injections to dust and pollen for a year with equivocal results. Approximately 8 years before the present evaluation, her symptoms had inexplicably disappeared, only to recur 6 months before her visit to the Clinic. At that time, the same generalized eruption developed, this time associated with eyelid swelling, the same tight feeling in the joints and also a tightness in the upper chest upon inspiration. There was no history of pleurisy, renal disease, hair loss, dry eyes, dry mouth or photosensitivity. Scattered erythematous flat papules were present on all extremities and a small, shallow-based painless erosive lesion was seen on the hard palate. The remainder of the examination was unremarkable.

Biopsy specimen of one of the skin lesions revealed scattered foci of leukocytoclastic vasculitis within the mid- and superficial dermis. There were no other light microscopic findings suggestive of SLE. Immunofluorescent studies of the patient's skin biopsy specimen revealed diffuse, finely granular deposits of IgG and IgM along the dermal-epidermal junction. Serum complement was depressed; total hemolytic complement was 37 CH<sub>50</sub> units (normal, 70-190 units); C4 was less than 9 mg/dl (normal, 14-51 mg/dl); C3 was 72 mg/dl (normal, 94-202 mg/dl); and C3 proactivator was less than 9.7 mg/dl (normal, 12-30 mg/dl). Circulating immune complexes were detected by C1q binding at 176 units/ml (normal, less than 74 units/ml). Antinuclear antibody was positive at a 1:320 dilution. Anti-DNA antibodies, LE cells, and rheumatoid factor were undetectable. Rapid plasma reagin (RPR) serology was positive at a 1:2 dilution with negative fluorescent treponemal antibody absorption (FTA-ABS). Urinalysis and creatinine were within normal limits. The erythrocyte sedimentation rate was elevated at 50 mm/hr (Westergren).

The patient was treated with prednisone, 40 mg daily and hydroxychloroquine, 200 mg daily with excellent response of the skin lesions. The prednisone was gradually tapered down to 10 mg daily with good control of symptoms.

*Comment.* This case fulfills the following ARA criteria for classification of

SLE: biologic false-positive test for syphilis and oral mucosal ulcerations. There was also a questionable history of arthralgias and tests for antinuclear antibodies were positive, but negative for anti-DNA. The patient probably has SLE but urticarial vasculitis could also be diagnosed because of the prominent role of urticaria in the clinical picture. Our case has elements similar to those described by Zeiss et al<sup>75</sup> including deposition of immunoglobulins at the dermal-epidermal junction detected by immunofluorescence. Also, C1q binding activity, as previously described,<sup>73-76</sup> was identified in our patient although no molecular weight determination was made.

**7. Vasculitis associated with other primary diseases in which immune complexes have been identified but are of questionable pathologic significance.**

This group includes a number of diseases that rarely exhibit cutaneous and/or visceral angiitis and form the loosest-fitting section of the HV group. We consider them here because nearly all have been reported to have circulating immune complexes although these are of doubtful primary pathologic significance. Another unifying point has been the documentation of leukocytoclasia in most cases. These conditions are listed in *Table 4*.

**Pathogenesis**

A growing body of experimental and clinical data has provided convincing evidence of the importance of circulat-

ing immune complexes (CIC) in the pathogenesis of necrotizing arteritis. These data may be considered in the following categories:

1. Experimental immune complex disease.
2. Identification of immune complexes in tissue.
3. Identification of soluble immune complexes in sera.
4. Identification of discrete antigen.

1. **Experimental models.** Elucidation of the serum sickness model of vascular inflammation in rabbits by Dixon<sup>91</sup> and co-workers has greatly contributed to our knowledge of the dynamics of immune complex-mediated injury. With use of a single dose of radiolabelled antigen, three phases of elimination can be observed. The first is a short period of equilibration with extravascular compartments. This is followed by a second longer period of terminal exponential decay, which represents endogenous metabolism by the host. The third is referred to as immune elimination; it represents elaboration of a specific antibody followed by formation of antigen-antibody complexes, which are then eliminated by the mononuclear phagocyte system or deposited in various organs. It is in this phase that complement consumption is observed and tissue injury occurs.<sup>92</sup>

Many factors are critical in the ultimate fate of endogenously formed immune complexes. These include size and valence of the antigen, immunoglobulin class and valence of antibody, size of the resultant immune complex, avidity of binding, ability of the host's reticuloendothelial system to clear the complexes, ability of the complexes to bind and activate the complement system, and lastly, some factor or factors that alter vascular permeability permitting deposition of immune complexes.<sup>92-94</sup>

The size or valence of the antigen is

**Table 4.** Miscellaneous conditions with HSV

Inflammatory bowel disease <sup>86, 87</sup>
Chronic active hepatitis <sup>19, 20</sup>
Primary biliary cirrhosis <sup>13</sup>
Retroperitoneal fibrosis <sup>88</sup>
Postintestinal bypass <sup>89</sup>
Goodpasture's syndrome <sup>90</sup>

a critical factor in determining the ultimate size of the resultant immune complex. Large complexes (larger than 19S) formed in antigenic excess appear to be the most pathogenic in the development of vascular lesions. Interaction with complement results in release of inflammatory mediators such as C3a, C3e, and C5a: C3a is a breakdown product of the native C3 molecule known as anaphylotoxin and is capable of causing histamine release from mast cells and basophils; C3e is chemotactic; C5a is also anaphylotoxic and in addition is a potent chemotactic factor attracting neutrophils, which results in tissue damage from release of acidic hydrolases and neutral proteases. Other complement component fragments may play a role in the inflammatory process; examples are C2 kinin and C567, but a discussion of these is beyond the scope of this paper. The ability of complexes to activate complement depends on the class and subclass of the involved antibodies; IgM, IgG1, and IgG3 are the most effective.<sup>95,96</sup> Although less efficient, alternative pathway activation via IgA,<sup>97</sup> such as in Henoch-Schönlein purpura,<sup>39</sup> can also be observed.

Once formed, immune complexes normally are cleared rapidly from the circulation by the reticuloendothelial system.<sup>98</sup> Recently, reticuloendothelial blockade has been demonstrated in several immune complex-mediated conditions such as mixed cryoglobulinemia, Sjögren's syndrome, and SLE.<sup>99-101</sup> This dysfunction has been postulated to contribute to the ultimate fate and deposition of immune complexes in these diseases.

It is also clear from animal studies that the mere presence of immune complexes in the circulation is insufficient to produce disease since passive infusion of preformed immune complexes does

not reproduce the classic serum sickness model with any regularity.<sup>102</sup> An additional factor or vascular trigger is necessary for the ultimate deposition of these complexes. Cochrane<sup>103</sup> found that pretreatment of animals with agents that increase vascular permeability leads to regular deposition of preformed CIC; furthermore, pretreatment of animals with antihistaminic drugs blocks the increased vascular permeability and prevents the deposition of immune complexes.<sup>103</sup> These intriguing animal studies led to analogous experiments in man, which demonstrated that histamine injection into clinically normal skin results in immune complex deposition in post-capillary venules and that tissue destruction is mediated via local complement activation and release of lysosomal enzymes from chemotactically attracted leukocytes.<sup>104, 105</sup>

Another form of vascular triggering mechanism appears to be altered hemodynamic factors. In classical polyarteritis nodosa a predilection for the bifurcation of arteries (areas with the most turbulent flow) has long been observed.<sup>106</sup> In the HV group the predilection for the lower extremities, where hydrostatic pressure is greatest, is another example of this hemodynamic triggering. Platelet accumulation with subsequent mediator release may be a critical factor in this vascular model.

Lastly, the tissue mast cell, which is rich in vasoactive mediators may play a key role in supplying the vascular trigger for the deposition of immune complexes in the microcirculation. Interaction with its membrane-bound IgE results in degranulation and release of stored (primary) mediators, such as histamine, and secretion and release of un-stored mediators, such as the slowly reactive substance of anaphylaxis (SRS-A), and the appearance of certain pros-

taglandins.<sup>107</sup> The distribution of mast cells in skin and mucosal surfaces and their proximity to venules make them prime candidates for a key role in the hypersensitivity group of vasculitides. A recent study of an extraordinary case of cutaneous vasculitis revealed early massive degranulation of mast cells followed by infiltration of acute inflammatory cells and the development of endothelial cell necrosis and fibrin deposition.<sup>108</sup> Though intriguing, the precise role of the mast cell in the pathogenesis of vasculitis is speculative.

**2. Identification of immune complexes in the tissues.** Various techniques have been used to demonstrate antibody, complement and occasionally antigen in tissues. Direct immunofluorescence and immunohistochemical staining have revealed IgG to be the most frequently deposited immunoglobulin in the vascular tissues, although IgM and IgA have also been detected. Various complement components have been identified, but only C3 has been detected with any regularity.<sup>109-112</sup> Electron microscopy has identified electron-dense material presumed to be immune complexes in vascular lesions.<sup>113</sup>

Immunohistochemical staining may provide useful information in the study of vasculitis. As demonstrated in Case 5, finding only one class of light chains in vessel walls was highly suggestive of a monoclonal protein participating in immunopathogenesis, ultimately leading to the diagnosis of vasculitis associated with malignancy. As previously mentioned, the finding of IgA as the predominant or sole class of immunoglobulin in vascular tissue is suggestive of Henoch-Schönlein purpura. Also, the identification of specific antigen in vessel walls, such as HB<sub>s</sub>Ag, has strong etiologic implications.

### 3. Identification of CIC in vasculitis

**syndromes.** Advances in the clinical laboratory have allowed identification of soluble immune complexes in various conditions. These techniques are not dependent on identification of antigen and are referred to as antigen nonspecific. These indirect assays include tests based upon physical properties (i.e., cryoprecipitation), binding to C1q (i.e., C1q solid phase, C1q precipitation in polyethylene glycol), binding of immune complexes to cells (i.e., Raji cell), inhibition of antibody-dependent cellular cytotoxicity (ADCC), and interaction with rheumatoid factor (i.e., monoclonal rheumatoid factor).

With these techniques, many investigators have detected circulating immune complexes in vasculitic syndromes. Immune complexes have been detected by means of cryoprecipitation by numerous investigators. Most of these patients were selected for the presence of cryoglobulins rather than vasculitis, so little can be said about the sensitivity of these assays,<sup>44-46, 114</sup> although comparison of the sensitivity of cryoprecipitation with that of C1q binding or the Raji cell assay in patients with membranous nephritis reveals that cryoprecipitation is at least equally sensitive.<sup>48</sup> With the use of 18 separate assays, a World Health Organization Collaborative Study Group detected immune complexes in 41% to 75% of patients with idiopathic cutaneous vasculitis.<sup>115</sup> In a study of 107 patients with various forms of cutaneous necrotizing arteritis, Makel et al<sup>116</sup> divided the group into predominantly leukocytoclastic or lymphocytic vasculitis and found immune complexes in 68% of the leukocytoclastic group but in only 44% of the lymphocyte-predominant group. Kammer et al<sup>117</sup> studied 29 patients with active cutaneous necrotizing arteritis, and found evidence of circulating

immune complexes in the majority of patients by both C1q binding and inhibition of ADCC. Sucrose density gradient ultracentrifugation revealed a molecular size usually greater than 19S. Other investigators have identified immune complexes in cutaneous vasculitis with a variety of other techniques.<sup>69, 118</sup>

#### 4. Identification of discrete antigen.

It was once hoped that identification of complexed antigen would be the final step in the study of vasculitis and would ultimately lead to a definitive classification. The first to be strongly linked to a vasculitic syndrome was the hepatitis B antigen, which was found in up to 50% of certain series of patients with polyarteritis nodosa.<sup>19-21</sup> Although strong evidence implicates the hepatitis B surface antigen as a causal agent in vasculitis, including demonstration of the antigen with immunoglobulin and complement in vessel walls and the presence of high concentrations of the antigen in cryoglobulins,<sup>119, 120</sup> it is well known that the clinical syndrome associated with hepatitis B is varied. The presentations reported included classical polyarteritis nodosa with aneurysm formation, HVG small vessel vasculitis, or arthralgia and/or arthritis.<sup>19, 119, 121</sup> The observation that a single antigen may be associated with numerous vasculitic syndromes should not be surprising but derives from the limited fashion in which blood vessels can respond to phlogistic stimuli. Nevertheless, identification of a specific antigen is valuable since it may be essential for appropriate therapy.

#### Histopathology

The histopathologic features of hypersensitivity vasculitis in the skin are functions of the timing of the biopsy and the activity of the vasculitic process.<sup>122</sup> In an early biopsy specimen of an active lesion there may be necrosis of

vessel walls accompanied by material with the staining qualities of fibrin. The inflammatory infiltrate may be predominantly polymorphonuclear leukocytes, and at times be accompanied by perivascular lymphocytes.<sup>123</sup> Other features may include endothelial swelling and degeneration, thickening of blood vessel walls, and thrombosis. In the HV group the neutrophils undergo the characteristic disintegration already described as leukocytoclasia (*Fig. 1*), although as mentioned earlier, this is neither uniformly present nor a particularly specific finding. Some authors have proposed minimum criteria for the diagnosis of vasculitis.<sup>124</sup>

The timing of the biopsy is important in interpreting the histopathologic findings. Early lesions are the most revealing in the search for immunoglobulins and/or complement via immunofluorescent techniques, as late lesions may fail to reveal any deposition. By light microscopy, late lesions may only demonstrate marked necrosis of dermal connective tissue making recognition of specific vessels virtually impossible. These and other factors contribute to the observation that the skin biopsy may be non-diagnostic in up to 30% of cases with cutaneous necrotizing arteritis.<sup>12, 125</sup>

#### Diagnosis

Since the skin is universally involved in HVG, the diagnosis should always be suspected when there are characteristic or suspicious lesions.<sup>7, 14, 22</sup> Palpable purpura is virtually synonymous with HVG and may be associated with itching, burning or stinging but is frequently asymptomatic. Chronic or recurrent urticaria is the second most common manifestation of HVG and is characteristic of some forms (e.g., hypocomplementemic vasculitis). Biopsies of other skin lesions demonstrate leukocytoclasia and should suggest HVG, but these may be

nonspecific such as erythematous macular, papular or annular eruptions. Occasionally pustules, vesicles, bullae, or plaques are vasculitic but this will not be appreciated without biopsy.<sup>126</sup>

Biopsy of the skin is the first step in diagnosis. Histologically in HVG, typical features may or may not be present in a given biopsy specimen. Varying degrees of endothelial swelling, frequently with occlusion of blood vessels, polymorphonuclear and/or lymphocytic infiltration with nuclear debris (leukocytoclasia), fibrinoid necrosis and extravasation of red blood cells may be observed.<sup>122, 123</sup>

Depending on the timing of the biopsy, immunofluorescence may show varying degrees of immunoglobulin and complement deposition in the vessel walls. Lesions older than 24–36 hours are frequently negative for these findings.<sup>127</sup> Regardless of timing, all suspected vasculitic lesions should be submitted for immunofluorescent microscopy.

Once the biopsy specimen has documented the presence of vasculitis and the clinical situation is consistent with the HV group, the clinician must attempt to classify the condition for therapeutic purposes. Often, no specific etiology is found and one must be satisfied with knowing only the degree of activity and extent of target organ involvement, but before this point is reached two questions must be asked:

1. Is there an obvious exogenous antigen, such as a particular drug, underlying infection, or foreign chemical or protein?

2. Is there any associated disease, either clinically apparent or occult, that can be the source of the aberrant immunologic response, e.g., cancer, connective tissue disease?

Once these questions have been addressed, it is essential to characterize the

condition serologically, which may further aid in diagnosis and therapy. These tests may be categorized as follows:

1. Antigen nonspecific tests for the detection of circulating immune complexes or tests suggesting the presence of immune complexes.

- a. Tests for immune complexes (Clq binding, cryoglobulins, Raji cell, other)

- b. Evidence of hypocomplementemia-depressed CH<sub>50</sub>, C<sub>3</sub>, C<sub>4</sub>.

2. Tests specific for offending antigen-antibody complexes:

- a. Infections (cultures of blood, urine, etc., or the presence of high titers of specific antibody, i.e., antistreptolysin 0)

- b. Connective tissue disease (rheumatoid factor, ANA, anti-DNA, anti-ENA, SS-A, SS-B).

3. Tests for target organ involvement, e.g., urinary protein, glomerular filtration rate, occult blood, chest roentgenogram.

Once the above data are obtained it should be apparent whether there is an implicated antigen or at least an associated systemic disease, and the decision to treat must now be addressed.

## Treatment

The treatment of HVG depends upon the activity of disease, extent of target organ involvement and identification of antigen or associated systemic disease. If exogenous antigen can be identified, its removal is the obvious initial treatment. If the antigen is a drug, foreign chemical or protein, its discontinuance will suffice in most cases of self-limited hypersensitivity angitis. If the syndrome is not self-limited, more aggressive removal of antigen and antigen-antibody complexes by techniques such as plasma exchange, appears to be of merit. If infection is the basis for antigenic stimulation, appropriate antimicrobial ther-

apy is the obvious treatment of choice. Clearly, treatment of any underlying disease (i.e., CTD, malignancy) is desirable therapy for HVG.

If no antigen can be identified then the decision to treat must be made on the basis of disease activity and target organ involvement. For instance, cases of idiopathic HVG or immune complex HVG with cryoglobulins limited to the skin usually need no treatment.<sup>45</sup> However, if visceral involvement is identified, such as renal, gastrointestinal, or central nervous system involvement, the treatment is controversial. Immunosuppressive agents such as corticosteroids or cytotoxic agents have been tried with varying results.<sup>10, 45</sup> Even more unproved but perhaps more rational therapies are antihistamines and colchicine.<sup>119, 128</sup> Plasma exchange remains the single most effective modality for rapid, though not necessarily sustained, reduction of circulating immune complexes.<sup>129</sup> When plasmapheresis is applied to hypersensitivity angitis secondary to exogenous antigen it has the theoretic advantage of removing not only preformed immune complexes but non-replicative antigenic stimulus, possibly ending an ongoing immune response.<sup>130</sup> The efficacy of this technique in HV has recently been reported.<sup>131</sup>

## References

1. Kussmaul A, Maier R. Ueber eine bisher nicht beschriebene eigenthümliche Arterienkrankung (Periarteritis nodosa), die mit Morbus Brightii und rapid fortschreitender allgemeiner Muskellähmung einhergeht. *Dtsch Arch klin Med* 1866; **1**: 484-518.
2. Cochrane CG. Mechanisms involved in deposition of immune complexes in tissues. *J Exp Med* 1971; **134**: 75-89S.
3. Weisman MH, Zvaifler NJ. Vasculitis in connective tissue disease. *Clin Rheum Dis* 1980; **6**: 351-73.
4. Gocke DJ, Hsu K, Morgan C, Bombardieri S, Lockshin M, Christian CL. Association between polyarteritis and Australia antigen. *Lancet* 1970; **2**: 1149-53.
5. Zubler RH, Lambert PH. Immune complexes in clinical investigation. *Recent Advances in Immunology* 1977; **1**: 125-47.
6. Rose GA, Spencer H. Polyarteritis nodosa. *Q J Med* 1957; **26**: 43-81.
7. Fan PT, Davis JA, Somer T, Kaplan L, Bluestone R. A clinical approach to systemic vasculitis. *Semin Arthritis Rheum* 1980; **9**: 248-305.
8. Alarcón-Segovia D, Brown AL Jr. Classification and etiologic aspects of necrotizing angitides: an analytic approach to a confused subject with a critical review of the evidence for hypersensitivity in polyarteritis nodosa. *Mayo Clin Proc* 1964; **39**: 205-22.
9. Alarcón-Segovia D. The necrotizing vasculitides; a new pathogenetic classification. *Med Clin North Am* 1977; **61**: 241-58.
10. Fauci AS, Haynes B, Katz P. The spectrum of vasculitis; clinical pathologic, immunologic and therapeutic considerations. *Ann Intern Med* 1978; **89**: 660-76.
11. Chumbley LC, Harrison EG Jr, DeRemee RA. Allergic granulomatosis and angiitis (Churg-Strauss syndrome); report and analysis of 30 cases. *Mayo Clin Proc* 1977; **52**: 477-84.
12. Hu CH, O'Loughlin S, Winkelmann RK. Cutaneous manifestations of Wegener granulomatosis. *Arch Dermatol* 1977; **113**: 175-82.
13. Gilliam JN, Smiley JD. Cutaneous necrotizing vasculitis and related disorders. *Ann Allergy* 1976; **37**: 328-39.
14. Sams WM Jr, Thorne EG, Small P, Mass MF, McIntosh RM, Stanford RE. Leukocytoclastic vasculitis. *Arch Dermatol* 1976; **112**: 219-26.
15. Ramsay C, Fry L. Allergic vasculitis: clinical and histological features and incidence of renal involvement. *Br J Dermatol* 1969; **81**: 96-102.
16. O'Duffy JD, Scherbel AL, Reidbord HE, McCormack LJ. Necrotizing angitis. I. A clinical review of twenty-seven autopsied cases. *Cleve Clin Q* 1965; **32**: 87-98.
17. Citron BP, Halpern M, McCarron M, et al. Necrotizing angitis associated with drug abuse. *N Engl J Med* 1970; **283**: 1003-11.
18. Wemambu SNC, Turk JL, Waters MFR, Rees RJW. Erythema nodosum leprosum: a clinical manifestation of the Arthus phenomenon. *Lancet* 1969; **2**: 933-5.
19. Duffy J, Lidsky MD, Sharp JT, et al. Polyarthritits, polyarteritis and hepatitis B. *Medicine* 1976; **55**: 19-37.

20. Sergent JS, Lockshin MD, Christian CL, Gocke DJ. Vasculitis with hepatitis B antigenemia: long-term observations in nine patients. *Medicine* 1976; **55**: 1-18.
21. Trepo CG, Zuckerman AJ, Bird RC, Prince AM. The role of circulating hepatitis B antigen/antibody immune complexes in the pathogenesis of vascular and hepatic manifestation in polyarteritis nodosa. *J Clin Pathol* 1974; **27**: 863-8.
22. Winkelmann RK, Ditto WB. Cutaneous and visceral syndromes of necrotizing or "allergic" angitis; a study of 38 cases. *Medicine* 1963; **43**: 59-89.
23. Mullick FG, McAllister HA, Wagner BM, Fenoglio JJ. Drug related vasculitis; clinicopathologic correlations in 30 patients. *Human Pathol* 1979; **10**: 313-25.
24. McCombs RP. Systemic "allergic" vasculitis; clinical and pathological relationships. *JAMA* 1965; **194**: 1059-64.
25. Curd JG, Milgrom H, Stevenson DD, Mathison DA, Vaughan JH. Potassium iodide sensitivity in four patients with hypocomplementemic vasculitis. *Ann Intern Med* 1979; **91**: 853-7.
26. Reed WP, Williams RC. Immune complexes in infectious diseases. *Adv Intern Med* 1977; **22**: 49-69.
27. Braverman IM, Yen A. Demonstration of immune complexes in spontaneous and histamine-induced lesions and in normal skin of patients with leukocytoclastic angitis. *J Invest Dermatol* 1975; **64**: 105-112.
28. Kaufman DB, McIntosh R. The pathogenesis of the renal lesion in a patient with streptococcal disease, infected ventriculoatrial shunt, cryoglobulinemia and nephritis. *Am J Med* 1971; **50**: 262-8.
29. Bayer AS, Theofilopoulos AN, Eisenberg R, et al. Circulating immune complexes in infective endocarditis. *N Engl J Med* 1976; **295**: 1500-5.
30. Davis JAS, Peters N, Mohammed I, Major GAC, Holborow EJ. Circulating immune complexes in a patient with meningococcal disease. *Br J Med* 1977; **1**: 1446-56.
31. Nydegger VE, Lambert PH. The role of immune complexes in the pathogenesis of necrotizing vasculitides. *Clin Rheum Dis* 1980; **6**: 255-78.
32. Sergent JS. Vasculitides associated with viral infections. *Clin Rheum Dis* 1980; **6**: 339-50.
33. Wharton CFD, Pietroni R. Polyarteritis after influenza vaccination. *Br Med J* 1974; **2**: 331-2.
34. Blumberg S, Bienfang D, Kantrowitz FG. A possible association between influenza vaccination and small-vessel vasculitis. *Arch Intern Med* 1980; **140**: 847-8.
35. Phanuphak P, Kohler PF. Onset of polyarteritis nodosa during allergic hyposensitization treatment. *Am J Med* 1980; **68**: 479-85.
36. Ansell BM. Henoch-Schönlein purpura with particular reference to the prognosis of the renal lesion. *Br J Dermatol* 1970; **82**: 211-21.
37. Ballard HS, Eisinger RP, Gallo G. Renal manifestations of the Henoch-Schoenlein syndrome in adults. *Am J Med* 1970; **49**: 328-35.
38. Kauffman RH, Herrmann WA, Meyer CJL, Daha MR, Van Es LA. Circulating IgA-immune complexes in Henoch-Schönlein purpura: a longitudinal study of their relationship to disease activity and vascular deposition of IgA. *Am J Med* 1980; **69**: 859-66.
39. Baart de la Faille-Kuyper EH, Kater L, Kooiker CJ, Dorhout Mees EJ. IgA-deposits in cutaneous blood-vessel walls and mesangium in Henoch-Schönlein syndrome. *Lancet* 1973; **1**: 892-3.
40. Spitzer RE, Urmson JR, Farnett ML, Stitzel AE, Post EM. Alteration of the complement system in children with Henoch-Schönlein purpura. *Clin Immunol Immunopathol* 1978; **11**: 52-9.
41. Grey HM, Kohler PF. Cryoimmunoglobulins. *Semin Hematol* 1973; **10**: 87-111.
42. Saba TM, Jaffe E. Plasma fibronectin (opsonic glycoprotein): its synthesis by vascular endothelial cells and role in cardiopulmonary integrity after trauma as related to reticuloendothelial function. *Am J Med* 1980; **68**: 577-94.
43. Putnam FW. The plasma proteins. New York, Academic. 1960; 352.
44. Brouet JC, Clauvel JP, Danon F, Klein M, Seligmann M. Biologic and clinical significance of cryoglobulins; a report of 86 cases. *Am J Med* 1974; **57**: 775-88.
45. Gorevic PD, Kassab HJ, Levo Y, Kihn R, Meltzer M, Prose P, Franklin E. Mixed cryoglobulinemia: clinical aspects and long-term follow-up of 40 patients. *Am J Med* 1980; **69**: 287-308.
46. Cream JJ. Cryoglobulins in vasculitis. *Clin Exp Immunol* 1972; **10**: 117-28.
47. Robinson MF, Roberts JL, Jones JV, Lewis EJ. Circulating immune complex assays in patients with lupus and membranous glomerulonephritis. *Clin Immunol Immunopathol* 1979; **14**: 348-60.
48. Cream JJ. Cryoglobulins in vasculitis. In:

- Chenais F, ed. Cryoproteines. Villar-de-Lans. 1978; Sept 21-3.
49. Clinicopathologic conference. Mixed cryoglobulinemia. *Am J Med* 1976; **85**: 769-76.
  50. Schultz DR, Yunis AA. Immunoblastic lymphadenopathy with mixed cryoglobulinemia; a detailed case study. *N Engl J Med* 1975; **292**: 8-14.
  51. Bywaters EGL. Peripheral vascular obstruction in rheumatoid arthritis and its relationship to other vascular lesions. *Ann Rheum Dis* 1957; **16**: 84-103.
  52. Douglas W. The digital artery lesion of rheumatoid arthritis; an immunofluorescent study. *Ann Rheum Dis* 1965; **24**: 40-5.
  53. Hurd ER. Extraarticular manifestations of rheumatoid arthritis. *Semin Arthritis Rheum* 1979; **8**: 151-76.
  54. Gordon DA, Bell DA, Baumal R, Broder I. Studies into the occurrence of soluble antigen-antibody complexes in disease. IV. Correlation between the rheumatoid biologically active factor and the clinical features of rheumatoid arthritis. *Clin Exp Immunol* 1969; **5**: 57-60.
  55. Zubler RH, Nydegger U, Perrin LH, et al. Circulating and intra-articular immune complexes in patients with rheumatoid arthritis; correlation of <sup>125</sup>I-C1q binding activity with clinical and biological features of the disease. *J Clin Invest* 1976; **57**: 1308-19.
  56. Weisman M, Zvaifler N. Cryoimmunoglobulinemia in rheumatoid arthritis; significance in serum of patients with rheumatoid vasculitis. *J Clin Invest* 1975; **56**: 725-39.
  57. Gupta RC, McDuffie FC, Huston KA, et al. Comparison of three immunoassays for immune complexes in rheumatoid arthritis. *Arthritis Rheum* 1979; **22**: 433-9.
  58. Cochrane CG, Koffler D. Immune complex disease in experimental animals and man. *Adv Immunol* 1973; **16**: 185-264.
  59. Gladstein GS, Rynes RI, Parhami N, Bartholomew LE. Gangrene of the foot secondary to systemic lupus erythematosus with large vessel vasculitis. *J Rheumatol* 1979; **6**: 549-53.
  60. Meltzer M, Franklin EC. Cryoglobulinemia—a study of twenty-nine patients; IgG and IgM cryoglobulins and factors affecting cryoprecipitability. *Am J Med* 1966; **40**: 828-36.
  61. Lawley TH, Moutsopoulos M, Katz SI, Theofilopoulos AN, Chused TM, Frank MM. Demonstration of circulating immune complexes in Sjögren's syndrome. *J Immunol* 1979; **123**: 1382-9.
  62. Kaltreider HB, Talal N. The neuropathy of Sjögren's syndrome; trigeminal nerve involvement. *Ann Intern Med* 1969; **70**: 751-62.
  63. Mason AMS, Gumpel JM, Golding PL. Sjögren's syndrome—a clinical review. *Semin Arthritis Rheum* 1973; **2**: 301-31.
  64. Moutsopoulos HM, Balow JE, Lawley TJ, Stahl NI, Antonovych TT, Chused TM. Immune complex glomerulonephritis in sicca syndrome. *Am J Med* 1978; **64**: 955-60.
  65. Caldwell DS. Musculoskeletal syndromes associated with malignancy. *Semin Arthritis Rheum* 1981; **10**: 198-223.
  66. Sams WM Jr, Harville DD, Winkelmann RK. Necrotizing vasculitis associated with lethal reticuloendothelial diseases. *Br J Dermatol* 1968; **80**: 555-60.
  67. Christianson HB, Fine RM. Vasculitis with or without panniculitis in leukemia, lymphoma, and multiple myeloma. *South Med J* 1967; **60**: 567-72.
  68. Rosen RD, Barnes BC. Measuring serum immune complexes in cancer. *Ann Intern Med* 1978; **88**: 570-1.
  69. Theofilopoulos AN, Wilson CB, Dixon FJ. The Raji cell radioimmune assay for detecting immune complexes in human sera. *J Clin Invest* 1976; **57**: 169-82.
  70. Gagliano RG, Costanzi JJ, Beathard GA, Sarles HE, Bell JD. The nephrotic syndrome associated with neoplasia; an unusual paraneoplastic syndrome; report of a case and review of the literature. *Am J Med* 1976; **60**: 1026-30.
  71. Johnson PC, Rolak LA, Hamilton RH, Luggana JF. Paraneoplastic vasculitis of nerve; a remote effect of cancer. *Ann Neurol* 1979; **5**: 437-44.
  72. Rewcastle NB, Tom MI. Non-infectious granulomatous angiitis of the nervous system associated with Hodgkin's disease. *J Neurol Neurosurg Psych* 1962; **25**: 51-8.
  73. McDuffie FC, Sams WM Jr, Maldonado JE, Andreini PH, Conn DL, Samayda EA. Hypocomplementemia with cutaneous vasculitis and arthritis; possible immune complex syndrome. *Mayo Clin Proc* 1973; **48**: 340-8.
  74. Agnello V. Complement deficiency states. *Medicine (Baltimore)* 1978; **57**: 1-20.
  75. Zeiss CR, Burch FX, Marder RJ, Furey NL, Schmid FR, Gerwurz H. A hypocomplementemic vasculitic urticarial syndrome; report of four new cases and definition of the disease. *Am J Med* 1980; **68**: 867-75.
  76. Marder RJ, Burch FX, Schmid FR, Zeiss CR, Gerwurz H. Low molecular weight C1q-

- precipitins in hypocomplementemic vasculitis-urticaria syndrome; partial purification and characterization as immunoglobulin. *J Immunol* 1978; **121**: 613-8.
77. Mathison DA, Arroyave CM, Bhat KN, Hurwitz DS, Marnell DJ. Hypocomplementemia in chronic idiopathic urticaria. *Ann Intern Med* 1977; **86**: 534-8.
  78. Soter NA. Chronic urticaria as a manifestation of necrotizing venulitis. *N Engl J Med* 1977; **296**: 1440-2.
  79. Phanuphak P, Kohler PF, Stanford RE, Schocket AL, Carr RI, Claman HN. Vasculitis in chronic urticaria. *J Allergy Clin Immunol* 1980; **65**: 436-44.
  80. Wands JR, Perrotto JL, Isselbacher KJ. Circulating immune complexes and complement sequence activation in infectious mononucleosis. *Am J Med* 1976; **60**: 269-72.
  81. Alpert E, Isselbacher KJ, Schur PH. The pathogenesis of arthritis associated with viral hepatitis complement-component studies. *N Engl J Med* 1971; **285**: 185-9.
  82. Fellner MJ. Penicillin allergy, 1976; a review of reactions, detection and current management. *Int J Dermatol* 1976; **15**: 497-504.
  83. Gairdner D. The Schönlein-Henoch syndrome (anaphylactoid purpura). *Q J Med* 1948; **17**: 95-122.
  84. Tuffanelli DL, Dubois EL. Cutaneous manifestations of systemic lupus erythematosus. *Arch Dermatol* 1964; **90**: 377-86.
  85. Agnello V. Immune complex assays: the first ten years. *Ann Intern Med* 1981; **94**: 266-7.
  86. Wackers FJT, Tytgat GN, Vreeken J. Necrotizing vasculitis and ulcerative colitis. *Br Med J* 1974; **4**: 83-4.
  87. Callen JP. Severe cutaneous vasculitis complicating ulcerative colitis. *Arch Dermatol* 1979; **115**: 226-7.
  88. Hellstrom HR, Perez-Stable EC. Retroperitoneal fibrosis with disseminated vasculitis and intrahepatic sclerosing cholangitis. *Am J Med* 1966; **40**: 184-9.
  89. Goldman JA, Casey HL, Davidson ED, Hersh T, Pirozzi D. Vasculitis associated with intestinal bypass surgery. *Arch Dermatol* 1979; **115**: 725-7.
  90. Weeks RE, Bernatz PE, Holley KE. CPC on Goodpasture syndrome. *Mayo Clin Proc* 1968; **43**: 449-56.
  91. Dixon FJ. The role of antigen-antibody complexes in diseases. *Harvey Lectures*, 1963; **58**: 21-52.
  92. Cochrane CG, Dixon FJ. Antigen antibody complex induced disease. In: Miescher PA, Müller-Eberhard HJ, eds. *Textbook of Immunopathology*. New York: Grune & Stratton, 1976; 137-56.
  93. Soter NA, Austen KF. Pathogenetic mechanisms in the necrotizing vasculitides. *Clin Rheum Dis* 1980; **6**: 233-48.
  94. Cochrane CG, Hawkins D. Studies on circulating immune complexes. III. Factors governing the ability of circulating complexes to localize in blood vessels. *J Exp Med* 1968; **127**: 137-40.
  95. Lambert PH, Casali P. Immune complexes and the rheumatic diseases. *Clin Rheum Dis* 1978; **4**: 617-43.
  96. Minta JO, Ward PA. The complement system of man. In: *Inflammation, Immunity and Hypersensitivity*. Movat HZ, ed. Hagerstown, Harper Row, 1979; 445-555.
  97. Goetze O, Müller-Eberhard HJ. The C3 activator system; an alternate pathway of complement activation. *J Exp Med (Suppl)* 1971; **134**: 90-108.
  98. Mannik M, Arend WP, Hall AP, Gilliland BC. Studies on antigen-antibody complexes. I. Elimination of soluble complexes from rabbit circulation. *J Exp Med* 1971; **133**: 713-39.
  99. Frank MM, Hamburger MI, Lawley TJ, Kimberly RP, Plotz PH. Defective reticuloendothelial system Fc-receptor function in systemic lupus erythematosus. *N Engl J Med* 1979; **300**: 518-23.
  100. Hamburger MI, Moutsopoulos HM, Lawley TJ, Frank MM. Sjögren's syndrome: a defect in reticuloendothelial system Fc-receptor function. *Ann Intern Med* 1979; **91**: 534-8.
  101. Hamburger MI, Gorevic PD, Lawley TJ, Franklin EC, Frank MM. Mixed cryoglobulinemia; association of glomerulonephritis with defective reticuloendothelial system. *Trans Am Assoc Physicians* 1979; **92**: 104-12.
  102. Cochrane CG. Studies on the localization of circulating antigen-antibody complexes and other macromolecules in vessels. I. Structural studies. *J Exp Med* 1963; **118**: 489-502.
  103. Cochrane CG. Studies on the localization of circulating antigen-antibody complexes and other macromolecules in vessels. II. Pathogenetic and pharmacodynamic studies. *J Exp Med* 1963; **118**: 503-17.
  104. Gower RG, Sams WM Jr, Thorne G, Claman HN. Immune complex deposition in leukocytoclastic vasculitis. *J Invest Dermatol* 1976; **66**: 271-2A.
  105. Wolff HH, Maciejewski W, Scherer R, Braun-Falco O. Immunoelectronmicroscopic examination of early lesions in histamine

- induced immune complex vasculitis in man. *Br J Dermatol* 1978; **99**: 13-24.
106. Fernandez-Diez J. General pathology of necrotizing vasculitis. *Clin Rheum Dis* 1980; **6**: 279-96.
  107. Anath N, Ranadive S. Histamine release from mast cells and basophils. In: *Inflammation, Immunity and Hypersensitivity*. Movat H, ed. Hagerstown: Harper-Row. 1979; 376-408.
  108. Soter NA, Mihm MC Jr, Dvorak HF, Austen KF. Cutaneous necrotizing venulitis; a sequential analysis of the morphological alterations occurring after mast cell degranulation in a patient with a unique syndrome. *Clin Exp Immunol* 1978; **32**: 46-58.
  109. Miescher PA, Paronetto F, Koffler D. Immunofluorescent studies in human vasculitis. In: Grabar P, Miescher P, eds. *Immunopathology*. IV. International Symposium. New York: Grune & Stratton, 1965; 446-56.
  110. Schroeter AL, Copeman PWM, Jordan RE, Sams WM Jr, Winkelmann RK. Immunofluorescence of cutaneous vasculitis associated with systemic disease. *Arch Dermatol* 1971; **104**: 254-9.
  111. Handel DW, Roenigk HH, Sharnoff J, Deodhar S. Necrotizing vasculitis. *Arch Dermatol* 1975; **111**: 847-52.
  112. Andrews DS, Caines G, McIntosh J, Petts V, Penny R. Circulating and tissue immune complexes in cutaneous vasculitis. *J Clin Lab Immunol* 1979; **1**: 311-20.
  113. Soter NA. Clinical presentations and mechanisms of necrotizing angitis of the skin. *J Invest Dermatol* 1976; **67**: 354-9.
  114. Cream JJ. Mechanism involved in clinical allergic vasculitis. VI. Experimental Models of Chronic Inflammatory Diseases; A Symposium. Heidelberg:Springer 1977; 152-63.
  115. Lambert PH, Dixon FJ, Zubler RH, et al. A WHO collaborative study for the evaluation of eighteen methods for detecting immune complexes in serum. *J Clin Lab Immunol* 1978; **1**: 1-15.
  116. Makel SE, Tappeiner G, Brumfield H, Jordan RE. Circulating immune complexes in cutaneous vasculitis; detection with C1q and monoclonal rheumatoid factor. *J Clin Invest* 1979; **64**: 1652-60.
  117. Kammer GM, Soter NA, Schur PH. Circulating immune complexes in patients with necrotizing vasculitis. *Clin Immunol Immunopathol* 1980; **15**: 658-72.
  118. McDougal JS, Redecha PB, Inman RD, Christian CL. Binding of immunoglobulin G aggregates and immune complexes in human sera to *staphylococci* containing protein A. *J Clin Invest* 1979; **63**: 627-36.
  119. Gower RG, Sausker WF, Kohler PF, Thorne GE, McIntosh RM. Small vessel vasculitis caused by hepatitis B virus immune complexes; small vessel vasculitis and HBsAG. *J Allergy Clin Immunol* 1978; **62**: 222-8.
  120. Levo Y, Gorevic PD, Kassab HJ, Zucker-Franklin D, Franklin EC. Association between hepatitis B virus and essential mixed cryoglobulinemia. *N Engl J Med* 1977; **296**: 1501-4.
  121. Fisher RG, Graham DY, Granmayeh M, Trabaino JG. Polyarteritis nodosa and hepatitis-B surface antigen: role of angiography in diagnosis. *Am J Roentgenol* 1977; **129**: 77-81.
  122. Roenigk HH. Vasculitis. *Int J Dermatol* 1976; **15**: 395-404.
  123. Soter NA, Mihm MC, Gigli I, Dvorak HF, Austen FK. Two distinct cellular patterns in cutaneous necrotizing angitis. *J Invest Dermatol* 1976; **66**: 344-50.
  124. Cox AJ. Pathology changes in hypersensitivity angitis. In: Hedwig EB, Mostoti FK, eds. *The Skin*. Baltimore: Williams & Wilkins, 1971; 279-92.
  125. Cream JJ, Gumpel JM, Peachey RDG, Schönlein-Henoch purpura in the adult; a study of 77 adults with anaphylactoid or Schönlein-Henoch purpura. *Q J Med* 1970; **39**: 461-84.
  126. Winkelmann RK. The spectrum of cutaneous vasculitis. *Clin Rheum Dis* 1980; **6**: 413-52.
  127. Sams WM Jr, Claman HN, Kohler PF, McIntosh RM, Small P, Mass MF. Human necrotizing vasculitis: immunoglobulins and complement in vessel walls of cutaneous lesions and normal skin. *J Invest Dermatol* 1975; **64**: 441-5.
  128. Hazen PG, Michel B. Management of necrotizing vasculitis with colchicine. *Arch Dermatol* 1979; **115**: 1303-6.
  129. Calabrese LH, Clough JD, Krakauer RS, Hoeltge GA. Plasmapheresis therapy of immunologic disease; report of nine cases and review of the literature. *Cleve Clin Q* 1980; **47**: 53-73.
  130. Clough JD, Calabrese LH. Theoretic aspects of immune complex removal by plasma exchange. *Plasma Therapy* 1981; **2**: 73-81.
  131. Wysenbeek AJ, Calabrese LH, Clough JD. Plasmapheresis therapy of fulminant hypersensitivity vasculitis. *J Rheumatol*. In press.