

CHANGES IN THE FUNDUS OCULI IN RELATION TO HYPERTENSION

GEORGE LOCKHART, III, M.D.
Department of Ophthalmology

AN understanding of the relationship of changes in the fundus oculi to grades of hypertension is important alike to the internist and the ophthalmologist. Various approaches to the study of the relationship have been suggested. These have been based on arbitrary classifications of ophthalmoscopic changes and hypertensive states, the early reports of which were those of Keith, Wagener and Barker¹ in 1939, and of Wagener, Clay and Gipner² in 1946. Wilson,³ in 1952, compared the two studies and suggested that a working combination of both classifications could be used. I have found the combination to be a practical basis for evaluating the over-all vascular status of the patient. Recently Minsky⁴ introduced a scheme of correlating ocular changes with diastolic blood pressure. To each type of retinal change he assigned a specific numerical value that he used in a mathematical formula to calculate the expected diastolic pressure. It is too soon as yet to assess the value of this procedure.

OCULAR MANIFESTATIONS OF HYPERTENSION

The ophthalmoscopic changes associated with hypertension may be classified into two groups: (1) *Angiopathy*, which includes generalized and focal vascular sclerosis and narrowing of arterioles; and (2) *Retinopathy*, which includes hemorrhages, exudates, neovascularization, papilledema, and macular stars.

Angiopathy

Recognition and Grading of Sclerosis

There still is much confusion in regard to recognition and grading of sclerosis in the fundus oculi. The chief problem is to differentiate between atherosclerosis and arteriolar sclerosis. Only the central retinal artery and the larger branches near the disc are true arteries. At about the first or second bifurcation, the retinal arterial tree becomes arteriolar in nature as the internal elastic lamina disappears, and gaps appear in the continuity of the fibers of the muscularis. These changes take place at a vascular diameter of about 75 microns.

Scheie⁵ has graded separately the hypertensive changes and those of arteriolar sclerosis, and has stressed the different types of arteriosclerosis. He particularly emphasized the differentiation of ophthalmoscopic changes in atherosclerosis and in arteriolar sclerosis. He included both general attenuation and focal constrictions of arterioles under hypertensive changes; however, I believe

that these signs should be considered separately since each has a different significance.

Atherosclerosis. Atherosclerosis usually is associated with the aging process, but it may begin early in life. It is a disease of the intima and is patchy in distribution. The primary lesions or atheromata are small, yellow, elevated areas of intimal thickening. The internal elastic lamellae become fragmented; proliferation of connective tissue takes place and deposition of cells and fibers containing cholesterol crystals and lipid droplets occurs. Hyalin degeneration and calcification subsequently may develop. There is a marked disparity between the extent of atherosclerosis and the degree of function of the organ supplied by the affected vessels: function is not disturbed until relatively late in the course of the disease; blood pressure may be normal even in advanced atherosclerosis.

On ophthalmoscopic examination, atherosclerosis in rare instances may be seen as an atheromatous plaque in a retinal arteriole. The plaque appears as a shining spot of yellowish color on an arteriole, usually at a bifurcation; the shining appearance is caused by the deposit of cholesterol crystals. However, the ocular involvement often is in the central retinal artery within the substance of the optic nerve and usually can be diagnosed only by inference. Often the first visible sign of atherosclerosis is occlusion of the central artery or vein, or of one of their branches. In that location a venous obstruction may be caused by atherosclerosis, since the artery and vein are immediately adjacent with their walls touching and they are surrounded by common bands of connective tissue. The vein may be compressed or may be invaded by the atheromatous plaque and thereby become obliterated. In the central retinal artery, there may be no ophthalmoscopic evidence of atherosclerosis even though obstruction is imminent. Often the earliest clue is the presence of choroidal sclerosis that is first seen in the inferior nasal quadrants and, in the early stages, appears similar to the usual tessellation seen in the fundi of blond or brunette persons. First the choroidal vessels stand out as reddish streaks, then yellow, and finally in advanced stages as white streaks. Choroidal sclerosis is a sign of atherosclerosis and not of hypertension, although it frequently is seen in hypertension.

Arteriolar sclerosis. Arteriolar sclerosis is caused by hypertension and represents damage to the walls of the vessels from the stress and strain of elevated blood pressure. Pathologically, the vascular walls show diffuse involvement with deposits of hyalin and lipid just outside the endothelium. As the disease progresses, the muscularis and finally the entire thickness of the wall are involved. The changes seen in the retinal arterioles reflect the condition of arterioles throughout the body and have been well correlated with changes in the renal arterioles.^{6,7}

Arteriolar sclerosis may be chronic or acute in formation. Chronic arteriolar sclerosis is a generalized sclerosis and may develop slowly over a period of years. Generalized arteriolar sclerosis is characterized by the absence of focal lesions, the vascular walls being smooth and without indentations. The degree of sclerosis is determined by the extent of arteriovenous crossing defects. Acute arteriolar sclerosis may develop rapidly when there is severe, active hypertension. This follows the hypertensive picture: first there is generalized narrowing

of arterioles, then focal angiospasm, then focal sclerosis. The degree of focal sclerosis is determined by the depth of focal sclerotic constrictions. The prognosis is worse in the acute type of arteriolar sclerosis than in the chronic type.

A secondary form of arteriolar sclerosis is caused by edema and fibrosis resulting from localized disease in the retina. This secondary form occurs most commonly near areas of chorioretinitis. The differentiation between generalized arteriolar sclerosis of hypertension and secondary arteriolar sclerosis is best made on the basis of the distribution of sclerosis. Hypertensive arteriolar sclerosis involves peripheral vessels first and then progresses centrally toward the larger vessels. Secondary arteriolar sclerosis may begin anywhere in the retina, depending upon the location of the primary inflammation. Sheathing of the arterioles is a form of secondary sclerosis caused by edema or retinopathy that often is seen in hypertension.

Grading of Arteriolar Sclerosis

The grading of the severity of arteriolar sclerosis is based upon two factors: the arteriolar light reflex, and the arteriovenous crossing defects. The second of these is the most important. Many different signs have been described as indications of arteriolar sclerosis, but all result from thickening of the walls of the arterioles and associated changes in the veins at the arteriovenous crossings. The arterioles and the veins have a common adventitial coat at their crossings. The earliest sign is compression of the veins, and this may vary in severity from the slightest indentation to nearly complete interruption of the vein at the point of crossing. Other signs include (1) deviation of the vein from its normal course at the point of crossing, (2) humping of the vein where it crosses an artery, (3) tapering caused by extension of the sclerotic process into the adventitia of the vein, and (4) banking caused by some obstruction to the venous return at the point of crossing.

A satisfactory grading of the *severity of arteriolar sclerosis* is as follows (Fig. 1):

- Grade I* Widening and increased brightness of the arteriolar-reflex stripe, and obscuration of the vein at point of crossing, with slight indentation of veins.
- Grade II* Copper-wire reflex, indentation of veins and clear spaces on side of crossing arterioles.
- Grade III* Silver-wire reflex, marked crossing defects, with tapering, banking, humping, and right-angled deflections.
- Grade IV* White fibrous cords with no blood column.

The terms *copper-wire* and *silver-wire* reflexes are somewhat misleading, since arteriolar light reflexes exactly described by these terms seldom are seen. In children and young adults with clear media, the normal arteriolar light reflex may be very brilliant. In Negroes the normal light reflex also often is unusually bright and may lead to errors in interpretation.

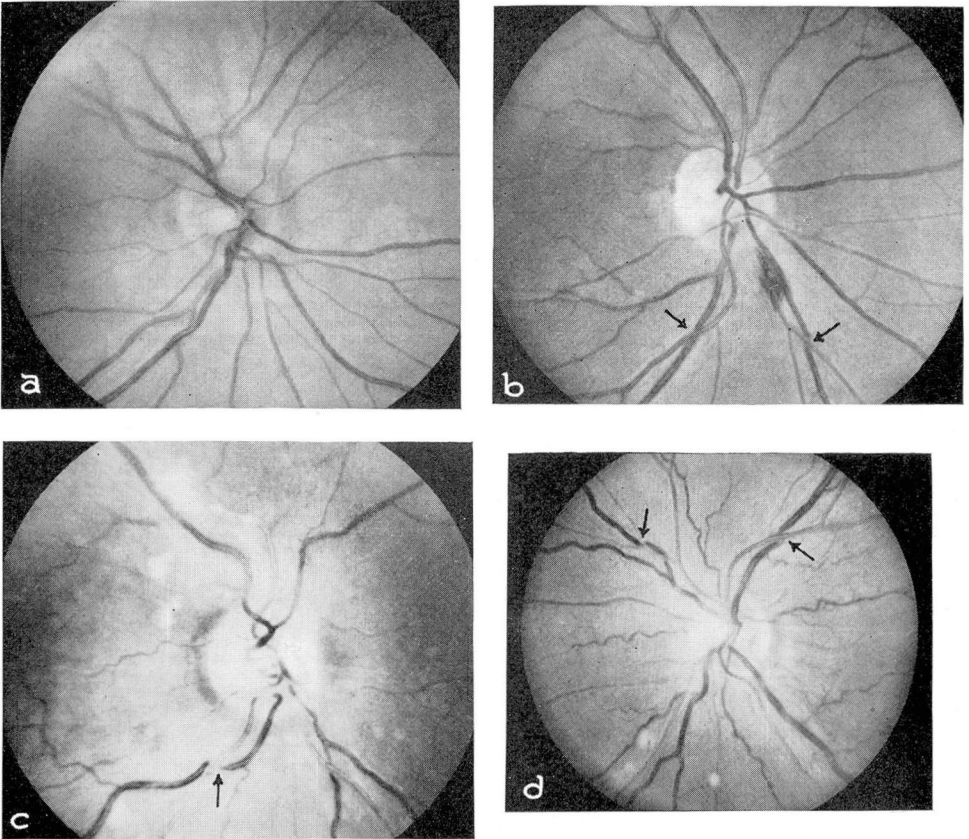


Fig. 1. Arteriolar sclerosis: (a) Normal. (b) Grade I. (c) Grade III. (d) Grade II.

Grading of Arteriolar Constriction

The second factor to be graded is constriction of the arterioles. Two types are found: (1) generalized attenuation that is due to tonic contraction of the vascular walls, and (2) focal constriction that is attributed to localized spasm. The earliest ophthalmoscopic change in hypertension is a generalized attenuation of arterioles. This is best seen in toxemia of pregnancy or in acute hypertension of rapid onset. The extent of narrowing is fairly proportional to the degree of elevation of blood pressure. In early cases it is seen first in the nasal quadrants beyond the second bifurcations. As mentioned earlier, I prefer to grade generalized and focal constrictions separately. Generalized narrowing almost always is present in organic hypertension; on the other hand, focal spasm indicates actively progressive disease and a more severe hypertension with a correspondingly poorer prognosis.

CHANGES IN FUNDUS OCULI

A suitable grading of the *severity of arteriolar constriction* is as follows:

Generalized (Fig. 2)

Grade I Slight narrowing—most noticeable in nasal periphery.

Grade II More marked narrowing with A/V ratio of about $\frac{1}{3}$.

Grade III Very marked narrowing, A/V ratio of about $\frac{1}{4}$.

Grade IV Arterioles threadlike or invisible.

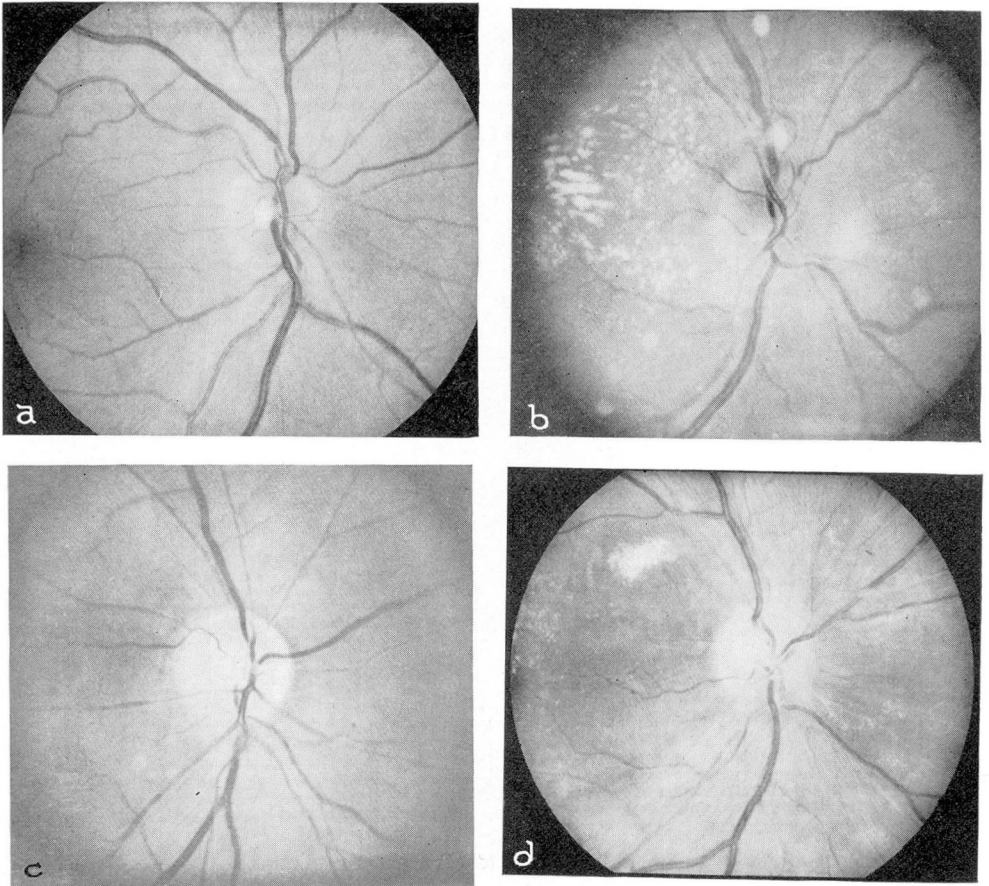


Fig. 2. Generalized arteriolar attenuation: (a) Grade I. (b) Grade II. (c) Grade III. (d) Grade IV.

Focal (Fig. 3)

Grade I Few areas of slight localized narrowing.

Grade II Many areas of narrowing to $\frac{1}{2}$ size of proximal segment.

Grade III Local narrowing to threadlike size.

Grade IV Arterioles invisible at points of constriction.

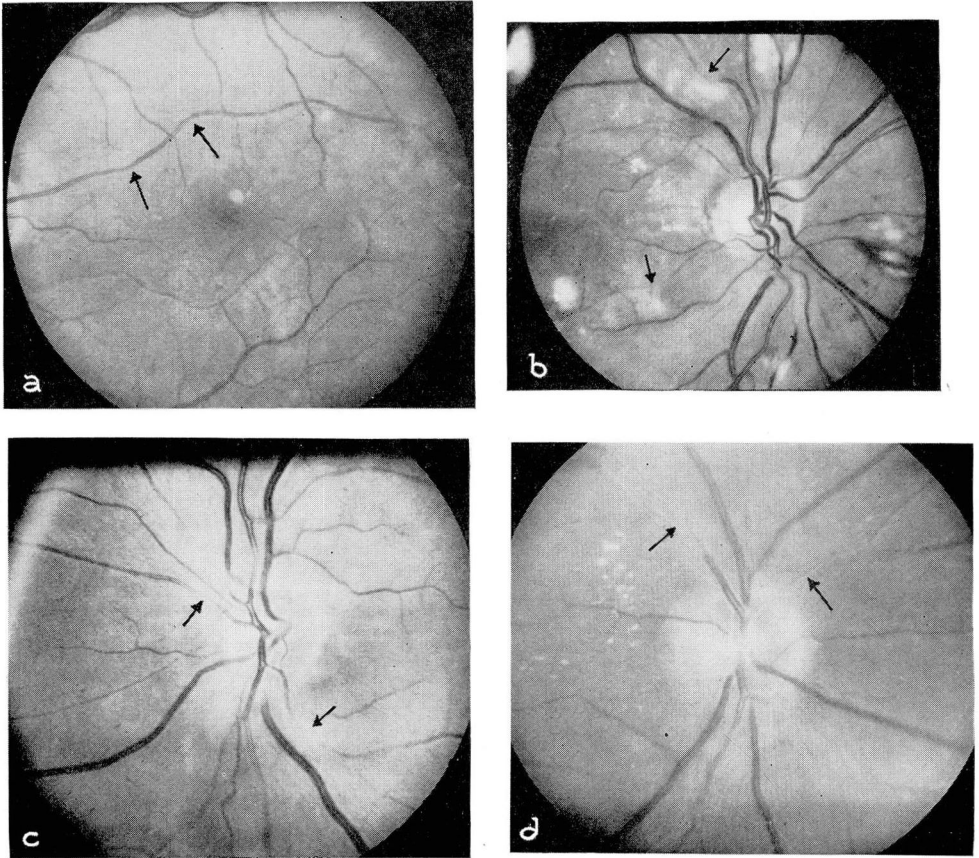


Fig. 3. Focal arteriolar constriction: (a) Grade I. (b) Grade II. (c) Grade III. (d) Grade IV.

Retinopathy

The next factor to be graded is retinopathy. Hemorrhages, exudates, and edema also are manifestations of the hypertensive picture.

Grading of Hemorrhages. Hemorrhages are graded 1 to 4 depending upon the number of ocular quadrants involved. The area of each eye, for observational

purposes, is arbitrarily divided into four quadrants; normally there are eight quadrants to observe. Hemorrhage in one or two quadrants is grade 1; in three or four quadrants is grade 2; in five or six quadrants is grade 3; in seven or eight quadrants is grade 4. This grading system is more accurate than counting the number of hemorrhages or estimating the total number, since a number of hemorrhages in one quadrant may be due to one spastic or damaged vessel; whereas, only a few in each of four or five quadrants certainly indicates a more widespread pathologic condition. Localized retinopathy from an occlusion of a venous branch is not graded as part of the hypertensive picture, but is listed as a complication.

Exudates. The term *exudate* is a misnomer since the appearance of whitish spots is not associated with actual inflammation, but the term is retained because of common usage and understanding. Exudates may be of two types: (1) Cotton-wool patches are seen as soft, white areas with feathery borders and are caused by localized edema, deposits of fibrin, or cytooid-body formation due to pre-capillary occlusion or spasm. Cotton-wool patches are graded, as are hemorrhages, according to the number of quadrants involved. They characteristically appear during acute phases of hypertension and may change appearance within three or four days. They usually take several weeks to disappear and may last for months. (2) Hard exudates or edema residues are deposits of hyalin or lipid in the deeper layers of the retina, and usually appear later than the cotton-wool patches; i.e., after the acute phase of hypertension has been present for a longer period of time, or when it is subsiding. These deposits frequently are seen in the macular region where they assume the appearance of the radiating-star figure because of the histologic configuration of Henle's layer. They are not graded numerically since their presence is not necessarily related to the course of the disease under treatment. They may last many months or even remain permanently.

Papilledema indicates the most severe hypertensive states and may be confined to the disc itself, or spread out in the surrounding retina. If edema is widespread over the retina, it may give rise to serous retinal detachment that subsides with control of the hypertensive state and absorption of edema.

Other Factors. Several other factors are noted and taken into consideration although they are not graded. Neovascularization indicates that occlusion or partial occlusion of vessels has previously occurred during active episodes of hypertension. Neovascularization of the disc often is seen after papilledema has subsided. Sheathing of vessels is not taken into account when grading generalized sclerosis; instead, it is listed separately as indicating previous angiospasm and edema. As mentioned before, vascular sheathing is a form of secondary arteriolar sclerosis. Sheathing of the larger vessels on the disc may be a normal variation. Elschnig spots appear as spots of pigment in the choroid with reddish or yellowish halos, and supposedly are caused by patchy distribution of the sclerotic process in the choriocapillaris; the overlying pigment disappears in certain areas to form the red or yellow halos, and accumulates in other areas to form the pigment spots. Siegrist streaks are chains of pigmented spots arranged

like a string of beads along a white and sclerotic choroidal vessel over which the pigment epithelium has been affected. The significance of Elschnig spots and Siegrist streaks is not well understood, but when they are widespread the prognosis must be more guarded.

SEVERITY OF HYPERTENSION IN RELATION TO OCULAR MANIFESTATIONS

Hypertensive changes have been variously grouped; the most widely used grouping as well as the simplest is the Keith-Wagener classification.¹ This classification is based on the over-all clinical status of the patient, and includes evaluation of cardiac and renal function and cerebrovascular and ophthalmoscopic changes.

Keith-Wagener Classification

- Group I* Minimal or no changes in all four systems. Fundi may show grade I arteriolar attenuation and sclerosis. The patient has no symptoms.
- Group II* Moderate-to-marked angiopathy with attenuation and sclerosis, but no retinopathy. However, there may occasionally be venous occlusions due to atherosclerosis. Other systems are affected, but function is adequate.
- Group III* Angiopathy and retinopathy present with hemorrhages and exudates. Patient almost always has symptoms. Other systems definitely affected.
- Group IV* Ocular signs, as in *group III*, with papilledema. Patients have serious impairment of cardiac or renal functions. Encephalopathy is frequent. Symptoms are severe.

I believe the best single classification is that proposed by Wagener, Clay and Gipner,² which was accepted by the American Ophthalmological Society. Hypertension is categorized into five types: (A) *Neurogenic*, (B) *Chronic nonprogressive*, (C) *Chronic progressive*, (D) *Acute angiospastic*, (E) *Terminal malignant*.

Wagener-Clay-Gipner Classification

- A. *Neurogenic hypertension*—Nothing in retina, except slight generalized attenuation
- B. *Chronic nonprogressive hypertension*
1. Grades I or II generalized attenuation of arterioles
 2. Grades I or II generalized arteriolar sclerosis (seen after disease has been present for several years)
- C. *Chronic progressive hypertension*
1. Generalized arteriolar sclerosis, always
 2. Generalized attenuation of arterioles
 3. Focal constrictions in arterioles
 4. Focal arteriolar sclerosis, occasionally
 5. Cotton-wool patches and hemorrhages, occasionally

D. *Acute angiospastic hypertension*

1. No arteriolar sclerosis
2. Generalized narrowing of arterioles
3. Focal constrictions in arterioles
4. Edema of retina, cotton-wool patches, hemorrhages
5. Edema of disc, often

E. *Terminal, malignant hypertension*

1. Generalized arteriolar sclerosis, always
2. Papilledema, always
3. Generalized attenuation of arterioles
4. Focal constrictions in arterioles
5. Edema, hemorrhages, cotton-wool patches, edema residues, macular stars

From the foregoing classification it can be seen that the presence of papilledema is not pathognomonic of malignant hypertension unless it is accompanied by arteriolar sclerosis. If ophthalmoscopic changes with papilledema are present but arteriolar sclerosis specifically is absent, the condition is classified as *acute angiospastic hypertension*; the course may progress to complete resolution, to chronic hypertension, or to malignant hypertension and death.

I have found a combination of these two classifications, the Wagener-Clay-Gipner and the Keith-Wagener, to be the most useful for evaluating changes in the fundus in relation to hypertension. After describing and grading the ophthalmoscopic changes, the impression is given as *chronic nonprogressive hypertension, group I*, or *chronic progressive hypertension, group II*, or any applicable combination as the particular case warrants. A supplementary notation may then be added indicating corollary impressions, such as evidence of previous papilledema or angiospastic episodes.

The grade of arteriolar sclerosis indicates the probable duration of the hypertension—a fact that often is difficult to deduce from the history. When the arteriolar sclerosis is minimal (grade I) or is absent, the hypertension most likely is of recent origin or is of neurogenic type. When arteriolar sclerosis is marked (grades III or IV) the hypertension is likely to be of long standing, although the more severe the hypertension the more rapidly sclerosis develops. The severity of hypertension usually can be assessed more readily by the internist. However, marked narrowing and focal constrictions of arterioles sometimes indicate severe hypertension when the blood pressure is normal or only slightly elevated; this condition may occur in a patient whose blood pressure has dropped as a result of coronary thrombosis or cardiac failure. Focal constrictions indicate more active hypertension than does generalized arteriolar constriction. Neovascularization and sheathing indicate previous angiospastic episodes and give a clearer picture of the history and prognosis of the disease.

Hemorrhages, exudates, and edema indicate active hypertension with breakdown of vessels. These changes are graded chiefly as a means of ascertaining the response of the patient to treatment; their disappearance indicates a favorable response. Early attenuation or mild focal constriction likewise may be lessened by treatment, but sclerosis is permanent and does not respond (Fig. 4).

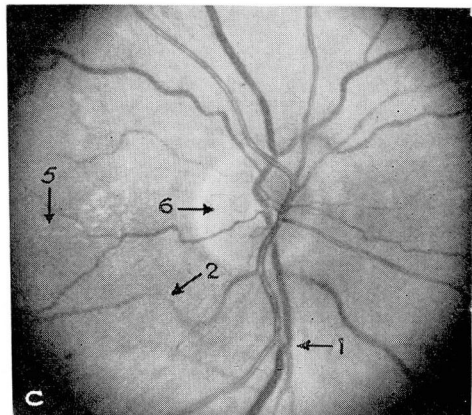
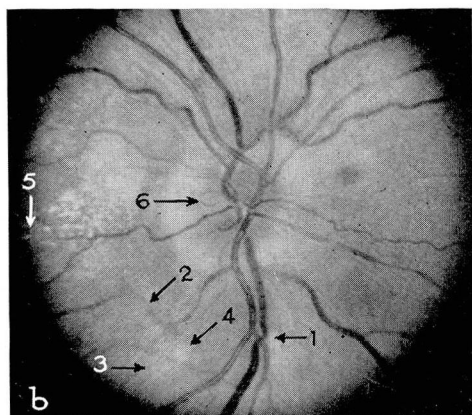
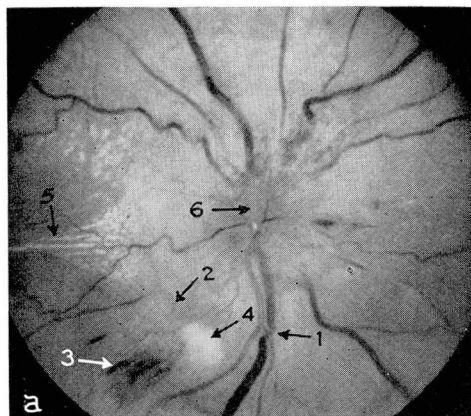


Fig. 4. Malignant syndrome with favorable response to treatment: (a) July 16. (b) Aug. 24. (c) Oct. 14. (1) Arteriolar sclerosis remains unchanged. (2) Arteriolar spasm lessens. (3) Hemorrhage is absorbed. (4) Cotton-wool patch disappears. (5) Macular star decreases. (6) Papilledema subsides.

Summary

Ophthalmoscopic changes in hypertension have been described, and the systems of grading and classification have been discussed, in an effort to clarify their value in determining the clinical status of hypertensive patients. Ophthalmoscopic examination in a hypertensive patient yields information concerning the appearance of the fundi and the status of arteriolar sclerosis, generalized attenuation, focal constrictions, hemorrhages, exudates, edema, neovascularization, sheathing, and choroidal changes. After examination and description of the fundi, the appropriate changes are graded and the over-all picture is then classified in terms of the Wagener-Clay-Gipner and the Keith-Wagener systems;

for example, *chronic progressive hypertension, group III*. When this method is followed, the ophthalmologist can be of great help to the internist in the evaluation of the hypertensive patient.

References

1. Keith, N. M., Wagener, H. P. and Barker, N. W.: Some different types of essential hypertension; their course and prognosis. *Am. J. M. Sc.* **197**: 332-343 (March) 1939.
2. Wagener, H. P., Clay, G. E. and Gipner, J. F.: Classification of retinal lesions in presence of vascular hypertension; report submitted by committee. *Tr. Am. Ophth. Soc.* **45**: 57-73, 1947.
3. Wilson, F. M.: Ophthalmoscopic evaluation of hypertensive patient. *J. Kansas M. Soc.* **53**: 225-229 (May) 1952.
4. Minsky, H.: Correlation of ocular changes in essential hypertension with diastolic blood pressure. *Arch. Ophth.* **51**: 863-874 (June) 1954.
5. Scheic, H. G.: Evaluation of ophthalmoscopic changes of hypertension and arteriolar sclerosis. *Arch. Ophth.* **49**: 117-138 (Feb.) 1953.
6. Castleman, B. and Smithwick, R. H.: Relation of vascular disease to hypertensive state. II Adequacy of renal biopsy as determined from study of 500 patients. *New England J. Med.* **239**: 729-732 (Nov. 11) 1948.
7. Wendland, J. P.: Relationship of retinal and renal arteriolosclerosis in living patients with essential hypertension. *Am. J. Ophth.* **35**: 1748-1752 (Dec.) 1952.