# Causes and management of surgical wound dehiscence

Michael S. Eisenstat, M.D.*
Stanley O. Hoerr, M.D.

*Department of General Surgery*

Dehiscence of the wound after abdominal surgery is a serious complication that continues to plague the surgeon and threaten the patient. Dehiscence is the disruption or breakdown of a wound.[1, 2] It may range in magnitude from a failure of the deeper portions of the abdominal incision to unite, unrecognized in the postoperative course but resulting later in an incisional hernia, to the dramatic "burst abdomen" or evisceration in which dehiscence of the wound occurs suddenly and is accompanied by protrusion of abdominal contents, usually bowel, through the disrupted wound.

Significant wound dehiscence occurs in approximately 1% of all laparotomies.[1-8] The incidence of wound disruption is correspondingly greater in a series of patients with various predisposing factors. For example, a recent report[9] stated that there was 7% wound disruption (21 of 291) in patients who underwent laparotomy for carcinoma. At the other extreme, in one author's (S.O.H.) experience there has been no incidence of significant disruption in a McBurney-type, muscle-splitting incision where the very nature of the incision effectively prevents such an occurrence.[10]

* *Present address: 2475 East 22nd Street, Cleveland, Ohio 44115.*

**Table 1.**—Summary: factors and treatment concerning surgical wound healing

| Factor | Treatment |
|---|---|
| I. *Systemic* | |
| Hypoproteinemia, especially hypoalbuminemia | Correct imbalances when possible before surgery. When correction is not possible, use retention sutures in addition to standard closure. |
| Anemia | |
| Vitamin C deficiency | |
| Steroid therapy | |
| Active infection | |
| Old age (affects rate of healing) | |
| II. *Local* | |
| Poor hemostasis | Good surgical technique and good anesthesia. Consider antibiotics (systemic and local) if infection is present or contamination unavoidable. Type of anesthesia is not a factor. |
| Poor blood supply | |
| Ragged wound edges | |
| Contamination of raw wound edges | |
| Inadequate drainage of undercut wounds (as in incisional hernia) | |
| Poor technique in making incision | |
| Poor technique in closing incision | |
| Anesthesia*—poor relaxation at time of closure and uneven tension and cutting of sutures | |
| III. *Postoperative* | |
| Violent coughing | Preoperative preparation and postoperative anticipation with institution of appropriate measures immediately. |
| Violent emesis | |
| Ileus | |
| Strain at urination | |
| Strain at passing flatus | |

* The type of anesthesia—general, regional, spinal, caudal, or local—is *not* a factor.

A number of factors influence the healing of a wound. Since we do not know how to accelerate the healing of wounds, it is more pragmatic to deal with those factors that may interfere with proper healing of the wound and hence predispose toward dehiscence. Factors can be divided into three groups: (1) *systemic,* such as severe anemia; (2) *local,* such as infection, or the technique followed in making and suturing the surgical incision; and (3) *postoperative,* such as abdominal distension (*Table 1*).

## Systemic factors

There is abundant experimental evidence supported by clinical experience that hypoproteinemia,[11, 12] especially hypoalbuminemia, or anemia,[1, 13] significantly retards the rate of healing. In practice, this means that every effort must be made preoperatively to correct abnormal metabolic states. A serum albumin content of 2 g/100 ml or less, for example, is of ominous importance, and its correction may present a formidable problem, particularly when gastrointestinal disease is the cause of the deficiency. Fortunately, anemia is more easily remedied by whole blood transfusions. A minimum hemoglobin level of 10 g/100 ml should be insisted upon and obtained for all types of elective abdominal surgery.

The role of vitamin C deficiency in preventing proper healing of wounds has also long been recognized.[14] In surgical practice in this country, clinical scurvy is rarely seen in adults. Suspected subclinical states in patients with wasting disease, for example, may be treated empirically by including vitamin C in the intravenous fluids the patient receives postoperatively.

Although patients who have had corticosteroid therapy preoperatively may have some impairment of normal healing powers,[15] this factor in itself is rarely a principal cause of dehiscence and is disregarded by most surgeons unless the therapy has been massive and lengthy. It is usually not practical to discontinue steroid therapy sufficiently long in advance to be of value; in fact a steroid preparation is indicated for the patient who has been treated with steroids to prevent an Addisonian crisis.

Some surgeons[2] believe obesity interferes with wound healing. We suspect this belief stems from the fact that most surgeons dislike to operate on extremely fat patients because of the technical difficulties, rather than from proof of any truly systemic effect of the obesity itself. It is our impression that otherwise healthy obese patients heal just as well postoperatively as otherwise healthy thin ones when uniform care is employed in making and closing the abdominal incision.

Certain systemic factors cannot be corrected or counteracted, such as advanced age,[3] previous irradiation of a proposed operative site, or the cachexia associated with advanced malignant disease. Under such circumstances, the most the surgeon can do is exercise maximal care in the technical performance of the operation, and perform the minimal procedure acceptable under the circumstances and in the prevention of postoperative complications. Retention sutures are useful when these states assume great significance.

Most wounds will heal despite the existence of systemic problems. Some surgeons believe the healing wound has biologic priority over other metabolic processes[16] and receives nutrition at the expense of other portions of the body. Nevertheless, it is prudent to correct existing abnormal systemic states when possible before performing any elective operation.

**Local factors**

Local factors adversely affecting wound healing include such obvious conditions as postirradiation changes, scars of previous incisions near the operative site, and infection in the skin. We have nevertheless noted the sound healing of an incision unavoidably placed through a psoriatic lesion.

A good blood supply must be available to any wounded area if proper healing is to take place.[13] Fortunately, the problem of blood supply in the abdominal incision rarely arises unless a new incision is placed parallel to a previous one, and then only the skin and subcutaneous fat may suffer ischemic necrosis. The muscles and fascia revascularize promptly after abdominal surgery.

This possible complication is usually preventable by excising the skin scar and subcutaneous fat as the first step in entering the abdomen. Two or even three previous parallel, closely placed incisions may be excised through an elliptical incision (*Fig. 1*) improving the appearance and the likelihood of sound healing.

## TECHNIQUE FOR EXCISION OF OLD SCARS

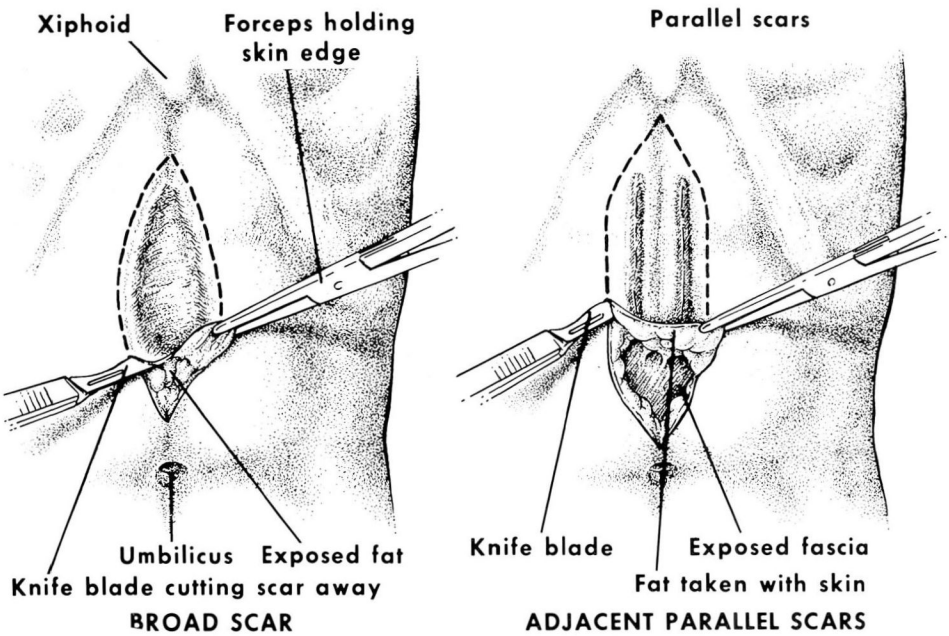


Fig. 1

The technique by which an incision is made strongly influences the degree of cellular injury in the wound. A clean sweep with the scalpel through skin and fat with minimal "sawing" with the knife blade or scissors will produce clean, straight wound edges rather than a terraced wound and will insure optimal circumstances for healing. To produce such a clean line of incision the surgeon should keep the two ends of the incision in sight at all times and not permit them to be obscured by drapes or assistants' hands. Undercutting of the wound edges or ends, although necessary in some hernia repairs, should also be avoided.

The raw wound edges should be protected during the operation. An ingenious plastic drape devised by Bernard (*Fig. 2*) is an effective barrier against contamination from open gastrointestinal anastomoses. Unnecessary or sudden movements of retractors held by assistants should be avoided. Self-retaining retractors are valuable and should be used when possible. Needless injury from rough handling of the wound, excessive use of electrocoagulation, or overlarge bites of tissue with hemostats predispose to wound infection and delay in normal healing. Most wound infections[1] are confined to the subcutaneous tissues and do not lead to an immediate disruption of the wound or a late hernia. Hematomas and seromas collecting in the wound also interfere with healing by increasing the likelihood of infection and by keeping apart tissues that must unite.

The method of wound closure is perhaps the most important factor in avoiding wound disruption and, to-

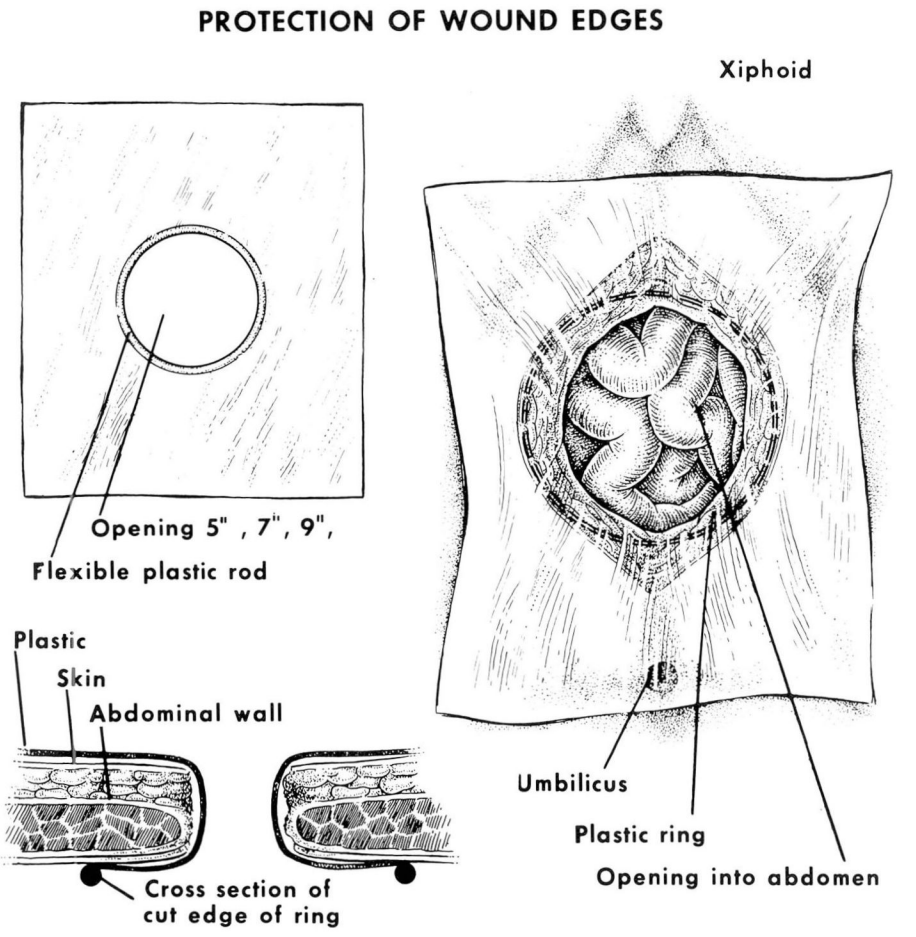


Fig. 2

gether with closure of the disrupted wound, is discussed in a separate section of this report.

Carefully constructed wounds in basically healthy patients will often heal per primam even if the surgeon must operate through an infected field, and wound contamination is unavoidable, as in secondary operations for enterocutaneous fistulas. Master surgeon Halsted operated on animals in his shirtsleeves and with clean but not sterilized hands. The surgical wounds usually healed perfectly, a result ascribed to his meticulous technique.

A point not often stressed is the role of anesthesia and the anesthesiologist in proper wound healing. An anesthetic which does not give adequate relaxation at the time of closure may result in torn tissue, extra strain on sutures, and hence a predisposition to dehiscence or a late hernia.

**Postoperative complications**

The triad of coughing, vomiting, and abdominal distension puts a tremendous stress on the abdominal incision, and each action may be sufficient to cause torn sutures, disruption, and

evisceration. The best treatment is prevention. A patient with a chronic cough related to cigarette smoking should be urged to cease smoking for several days before elective laparotomy. An upper respiratory infection, which increases the danger of postoperative pneumonitis, contraindicates any elective procedure. Vomiting and abdominal distension are also more easily controlled by preventive measures than by direct treatment once they are established. Appropriate use of nasogastric suction, enemas, and a drug such as physostigmine will help to arrest a developing ileus.[1, 4, 6-8, 17]

Although nasogastric syphonage is very effective in preventing ileus, it is not altogether harmless, and also its intrinsic discomfort to the patient interferes with coughing and may predispose toward a postoperative pulmonary complication. The surgeon must decide for each patient whether it is necessary. For several years we have been removing nasogastric tubes from nearly all patients in the recovery room, including those who have undergone vagotomy with some other gastric procedure. We rely heavily on the vigilance of the nursing and resident staffs to reinstitute nasogastric suction when vomiting or distension occurs. We are convinced that this is a valid practice for most patients, and it has reduced the incidence of pulmonary complications.

Any sudden setting of the abdominal muscles may strain the wound beyond endurance. One must guard against the too vigorous cough, both in managing postoperative pulmonary complications and in their prophylaxis by encouraging the patient to cough. In one of our patients disruption and evisceration were directly related to strenuous coughing. This applies also to undue effort to urinate or expel gas. A catheter is certainly preferable to an overextended bladder; a rectal suppository or an enema may be all the assistance needed for a relatively effortless passing of flatus.

**Primary closure**

One of the authors (S.O.H.) was trained in the interrupted-silk-layered closure of the abdominal incision. This is the use of interrupted silk sutures to the peritoneum, the muscle, the rectus fascia, the subcutaneous tissue, and the skin, as five separate layers. It is undoubtedly an effective closure but may be time-consuming and vexing. During 1950 and 1951, in a consecutive series of patients, one of two closures was used on alternate patients: the interrupted-silk closure or a mass wire closure of fascia, muscle, and peritoneum using the procedure introduced by the late Dr. Thomas E. Jones (*Fig. 3*).[5, 10]

The study included a measurement of the length and depth of the wound of each patient, the time consumed during the closure, the number of doses of narcotics required postoperatively by each patient, an estimate of the subjective wound pain, and notation of any wound complications. Results showed that the two methods of closure had the same general postoperative success and about the same incidence of early complications. Occasionally a wire suture must be removed to relieve discomfort or because of a persisting small sinus; the same applies to silk sutures which may sometimes be poorly tolerated. It was clearly apparent, however, that wire

## TECHNIQUE OF WIRE CLOSURE

### IN MIDLINE INCISION, MUSCLE NOT SHOWING

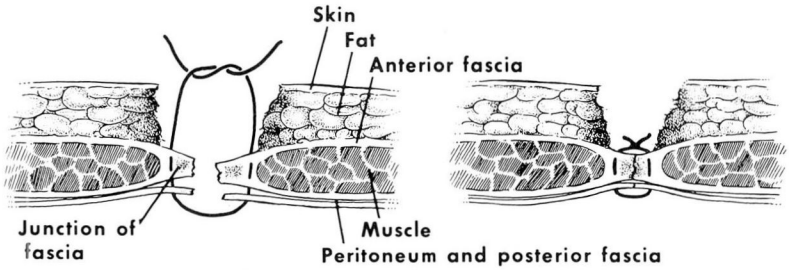


Plain interrupted #30 stainless steel wire

Simple suture. Figure of 8 unnecessary to coapt anterior fascia

### IN MIDLINE INCISION, MUSCLE SHOWING ON ONE SIDE

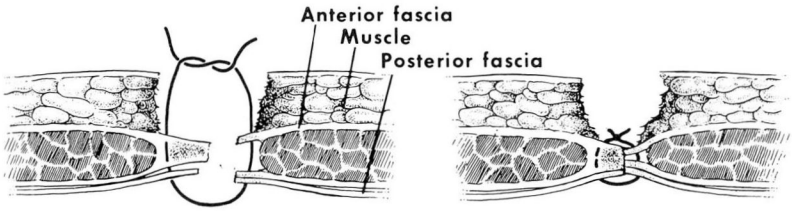


Muscle not entered, suture in anterior and posterior fascia, and fascia on opposite side

### FIGURE OF 8 SUTURE

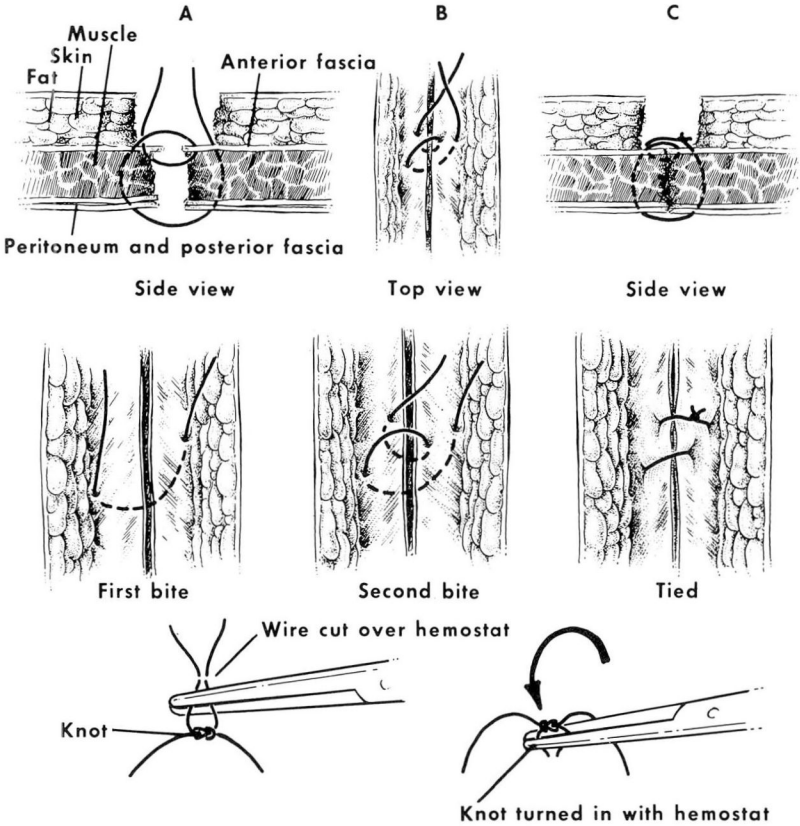


Fig. 3

closure was vastly superior to the silk closure both in the ease and speed of performance. It has become the preferred closure for nearly all surgeons operating at the Cleveland Clinic. Those who received their training in other institutions liked and used the wire closure once they became familiar with it, through their residents. One advantage of wire is that it produces a good closure of the midline incisions so useful for many abdominal operations. Surgeons employing an interrupted-silk or catgut closure hesitate to use an upper abdominal midline incision because they do not feel secure in using small, delicate stitches in only one deep layer. They prefer the paramedian incision, in which the peritoneum and fascia are closed separately, creating two layers with interposed muscle, adding security to the wound's closure.

Although there is a variety of acceptable methods of closing abdominal incisions we have found Doctor Jones' wire closure to be a safe, sound way to close all types of abdominal incisions, with low incidence of disruption and late incisional hernia. The second author (S.O.H.), in a series of 472 abdominal operations for carcinoma of the stomach, has observed only three disruptions. The standard incision for these cases was the upper abdominal midline incision closed with interrupted No. 30 stainless steel wire through fascia, muscle, and peritoneum. Additional retention sutures through all layers were not used.

The mass wire closure may be contraindicated in exceptionally thin patients and in children. In recent years, Ethiflex suture material has been used instead of wire in the mass closure by many of our staff.

**Disruption and evisceration**

Disruption can take place at any time in the postoperative period but most often occurs between the fifth and twelfth postoperative days. In patients with healing problems the disruption may occur much later. It may occur shortly after the skin sutures have been removed. In about half the cases disruption will be heralded by the appearance of a serosanguinous discharge on the dressing.[1, 2] If this occurs before the seventh day, it may be considered pathognomonic of dehiscence. The patient should be taken immediately to the operating room to undergo exploration of the wound under an anesthetic. When the discharge is the result of a hematoma, it can be evacuated and the superficial portions of the wound resutured without harm, but if there is in fact a disruption, the wound can be immediately resutured with minimal risk and discomfort to the patient. In the absence of infection a resutured wound heals more rapidly than the primary wound, presumably because some metabolic preparation of the tissues has already taken place.[15]

In a few patients the disruption is violent and sudden, with protrusion of the intestines through the wound onto the surface of the abdomen.[1] Appropriate treatment at the bedside includes protecting the intestines with sterile towels, promptly administering a narcotic, intravenously if possible, and immediately taking the patient to the operating room. This type of disruption has long been associated with a substantial mortality rate, but most often, death is a result not of the disruption but of the underlying conditions that caused it. The most fre-

quent complications after disruption and resuture of a wound are a generalized peritonitis or a pulmonary complication. These should be anticipated and appropriate preventive measures taken.

Some patients experience and describe a tearing sensation preceding the disruption. When such an event is described by an extremely obese patient and there is no surface evidence of the disruption, an oblique soft-tissue roentgenogram of the abdominal wall may help to establish the diagnosis by showing gas in intestinal loops trapped in the deep subcutaneous tissues.[18]

There are various ways of resuturing these incisions. One method employs heavy German silver wire with pointed ends brought up through all layers and twisted together to the desired degree of tension.* These wire ends can be untwisted as the wound swells, to prevent cutting. By another method a small rubber catheter is brought up through a stab wound and either sutured at the desired degree of tension or held with a clamp.† One of us (S.O.H.) has devised a highly satisfactory method in which braided silk (fistula silk) sutures are placed through all layers of the abdominal wall at a distance of less than 1 cm apart. Every alternate suture is tied; then, on the third or fourth day, when the wound swelling is maximal, the sutures that had been left untied are tied, and the tied ones are removed. This eliminates the cutting that is the chief adverse effect of retention sutures.[19] Suturing the original muscle wall as a single portion of the closure can be accomplished with an interrupted No. 30 stainless steel wire as well as with the braided silk.[3, 14, 17, 18]

A disruption without evisceration occasionally may occur in a patient who is extremely ill. Broad adhesive tape straps, two or three inches wide, placed closely together, with most of the anterior abdominal wall under the tape provide control. The conventional "butterfly" tape is not useful and actually prevents maximum gripping of the normal skin by the tape.

## Summary and conclusion

Wound disruption is a serious complication that may follow any laparotomy, and may vary in extent from a separation of the wound edges to evisceration with bowel and other abdominal contents protruding through the wound. In an unselected series the incidence of wound disruption generally occurs in about 1% of all laparotomies; in patients with late malignant diseases or other serious illnesses the incidence may be much greater. Factors predisposing toward dehiscence include systemic abnormalities such as anemia and hypoproteinemia, local influences such as poor technique in construction and closure of the incision, and postoperative complications that increase the tension on the wound (such as coughing, vomiting, and abdominal distension). The method used in the closure of the wound has some significance, although dehiscence with evisceration may follow any type of closure except one employing retention sutures through all layers. We prefer a mass closure of fascia, muscle, and peritoneum with interrupted No. 30 stainless steel wire for the primary incision, and a resu-

* *Personal communication from Eugene Bricker, M.D., St. Louis, Missouri.*

† *Personal communication from Howard Dorton, M.D., Lexington, Kentucky.*

ture of disrupted wounds with interrupted braided silk sutures through all layers by a special technique in which every other suture is tied initially, and the untied ones tied later when the first ones are cutting into the wound and may be removed. When the risk of dehiscence seems to be unusually great, retention sutures of the type described may be combined advantageously with a standard wire closure.

## References


1. Maingot R: Management of the wound. Chap. 2, p. 29–50 *in* Abdominal Operations. Edited by R Maingot, New York: Appleton-Century-Crofts, Inc., 1964.
2. Mayo CW, Lee MJ Jr: Separation of abdominal wounds. AMA Arch Surg **62:** 883–894, 1951.
3. Abt AF, Von Schuching S: Aging as a factor in wound healing. L-ascorbic-1-C14 acid catabolism and tissue retention following wounding in young and older guinea pigs. Arch Surg **86:** 627–632, 1963.
4. Efron G: Abdominal wound disruption. Lancet **I:** 1287–1290, 1965.
5. Jones TE, Newell ET, Brubaker RE: The use of alloy steel wire in the closure of abdominal wounds. Surg Gynecol Obstet **72:** 1056–1059, 1941.
6. Lehman JA Jr, Cross FC, Partington PF: Prevention of abdominal wound disruption. Surg Gynecol Obstet **126:** 1235–1241, 1968.
7. Tweedie FJ, Long RC: Abdominal wound disruption. Surg Gynecol Obstet **99:** 41–47, 1954.
8. Wolff WI: Disruption of abdominal wounds. Ann Surg **131:** 534–555, 1950.
9. Mendoza CB Jr, Watne AL, Grace JE, et al: Wire versus silk: choice of surgical wound closure in patients with cancer. Am J Surg **112:** 839–845, 1966.
10. Hoerr SO, Allen R, Allen K: The closure of the abdominal incision; a comparison of mass closure with wire and layer closure with silk. Surgery **30:** 166–173, 1951.
11. Kobak MW, Benditt EP, Wissler RW, et al: The relation of protein deficiency to experimental wound healing. Surg Gynecol Obstet **85:** 751–756, 1947.
12. Sisson R, Lang S, Serkes K, et al: Comparison of wound healing in various nutritional deficiency states. Surgery **44:** 613–618, 1958.
13. DeVito RV: Healing wounds. Surg Clin North Am **45:** 441–459, 1965.
14. Dunphy JE, Udupa KN: Chemical and histochemical sequences in the normal healing of wounds. N Engl J Med **253:** 847–851, 1955.
15. Savlov ED, Dunphy JE: The healing of the disrupted and resutured wound. Surgery **36:** 362–370, 1954.
16. Moore FD: Part I. Section III. Wound healing: biochemical changes and nutritional effects. p. 127–133 *in* Metabolic Care of the Surgical Patient. 1st Edition. Edited by F D Moore, Philadelphia: W. B. Saunders Co., 1959.
17. Alexander HC, Prudden JF: The causes of abdominal wound disruption. Surg Gynecol Obstet **122:** 1223–1229, 1966.
18. Gilfillan RR: Abdominal wound disruption. Lancet **II:** 499, 1965.
19. Hoerr SO: A new single layer technique for closing the disrupted wound. Surg Gynecol Obstet **126:** 119–120, 1968.