

THE CLINICAL PICTURE

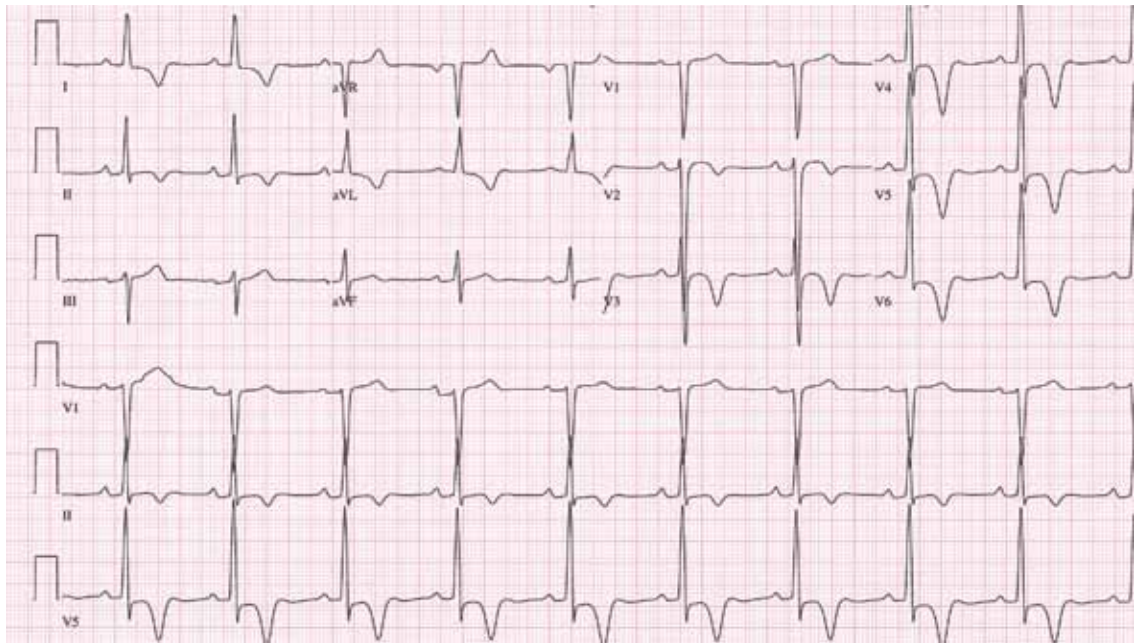
SURABHI MADHWAL, MD
Mount Sinai Heart at The Mount Sinai
Medical Center, New York, NY

VIJAGANESH NAGARAJAN, MD, MRCP, FACP
Department of Hospital Medicine, Cleveland Clinic,
Cleveland, OH

DONALD A. UNDERWOOD, MD
Department of Cardiovascular Medicine,
Cleveland Clinic, Cleveland, OH

The Clinical Picture

Giant inverted T waves



LVH with giant T waves of this quality should raise the suspicion of hypertrophic cardiomyopathy with apical hypertrophy

FIGURE 1. The patient's 12-lead electrocardiogram showed sinus bradycardia with a rate of 57 beats per minute, QRS duration of 110 ms, increased voltage compatible with left ventricular hypertrophy, and notably large, asymmetric inverted T waves in the lateral and midprecordial leads.

A 48-YEAR-OLD MAN with hypertension was being evaluated for a noncardiac issue (progressive multifocal leukoencephalopathy). He had been an active runner and did not have any cardiovascular symptoms at the time. The electrocardiogram (ECG) shown in **FIGURE 1** was a routine study done as a part of that evaluation. His cardiovascular examination was unremarkable, without murmur, S3, or S4. His pulse was regular at 72 beats per minute, and his blood pressure was 112/76 mm Hg.

doi:10.3949/ccjm.80a.11139

Q: Which of the following electrocardiographic findings suggest left ventricular hypertrophy?

- Sum of the S wave in V₁ and the R wave in V₆ ≥ 35 mm
- Sum of the S wave in V₃ and the R wave in aVL > 28 mm (men)
- Sum of the S wave in V₃ and the R wave in aVL > 20 mm (women)
- All of the above

A: The correct answer is all of the above.^{1,2}

Our patient's ECG shows sinus bradycardia and left ventricular hypertrophy, suggested by

prominent voltage (sum of S in V₁ and R in V₆ ≥ 35 mm) and supported by ST-segment and T-wave changes in the lateral and midprecordial leads. Classic changes of left ventricular hypertrophy often include increased voltage and downsloping ST-segment depression with negative T waves in V₅ and V₆ (secondary repolarization changes or “strain” pattern).

Notable on this tracing are the large, asymmetric negative T waves in leads V₃ through V₆. Giant T waves are defined as negative T waves with voltage greater than 10 mm.³ Although there is no specific pattern of ventricular hypertrophy on an ECG that establishes the diagnosis of hypertrophic cardiomyopathy, left ventricular hypertrophy with T waves of this quality suggest the possibility of hypertrophic cardiomyopathy with apical hypertrophy.

Q: What are the other causes of giant negative T waves?

- Subarachnoid hemorrhage
- Complete heart block
- Non-Q-wave myocardial infarction
- All of the above

A: The correct answer is all of the above. Additional causes of dramatic T-wave inversion are listed in **TABLE 1**. Clinically, non-Q-wave myocardial infarction with T-wave changes and acute central nervous system injury are probably the most commonly seen.⁴

Echocardiography in this patient revealed severe apical hypertrophy of the ventricle with distal cavity obliteration. The left ventricular

TABLE 1

Causes of giant T-wave inversion

- Apical hypertrophic obstructive cardiomyopathy
- Subarachnoid hemorrhage
- Cocaine abuse
- Non-Q-wave myocardial infarction
- Acute abdomen (eg, acute pancreatitis)
- Complete heart block
- Severe right ventricular hypertrophy
- Elevated intracranial pressure
- Post-pacemaker syndrome
- Wolff-Parkinson-White syndrome

outflow-tract gradient was normal. The mitral valve appeared normal, and there was no resting systolic anterior motion.

Cardiac magnetic resonance imaging showed the apical variant of hypertrophic cardiomyopathy but no evidence of left ventricular noncompaction, which is a differential diagnosis of apical hypertrophic obstructive cardiomyopathy. This disease was first described in Japan by Yamaguchi et al⁵ and Sakamoto et al⁶ and is regarded as a subgroup of nonobstructive hypertrophic cardiomyopathy. The prognosis of apical hypertrophic cardiomyopathy with regard to sudden cardiac death is believed to be better than that of other forms of hypertrophic cardiomyopathy.³

Echo revealed severe apical hypertrophy of the ventricle with distal cavity obliteration

REFERENCES

1. Sokolow M, Lyon TP. The ventricular complex in left ventricular hypertrophy as obtained by unipolar precordial and limb leads. 1949. *Ann Noninvasive Electrocardiol* 2001; 6:343–368.
2. Casale PN, Devereux RB, Alonso DR, Campo E, Kligfield P. Improved sex-specific criteria of left ventricular hypertrophy for clinical and computer interpretation of electrocardiograms: validation with autopsy findings. *Circulation* 1987; 75:565–572.
3. Eriksson MJ, Sonnenberg B, Woo A, et al. Long-term outcome in patients with apical hypertrophic cardiomyopathy. *J Am Coll Cardiol* 2002; 39:638–645.
4. Jacobson D, Schrire V. Giant T wave inversion. *Br Heart J*

- 1966; 28:768–775.
5. Yamaguchi H, Ishimura T, Nishiyama S, et al. Hypertrophic nonobstructive cardiomyopathy with giant negative T waves (apical hypertrophy): ventriculographic and echocardiographic features in 30 patients. *Am J Cardiol* 1979; 44:401–412.
6. Sakamoto T, Tei C, Murayama M, Ichiyasu H, Hada Y. Giant T wave inversion as a manifestation of asymmetrical apical hypertrophy (AAH) of the left ventricle. Echocardiographic and ultrasono-cardiographic study. *Jpn Heart J* 1976; 17:611–629.

ADDRESS: Vijaiganesh Nagarajan, MD, MRCP, Department of Hospital Medicine, M2 Annex, Cleveland Clinic, 9500 Euclid Avenue, Cleveland, OH 44195; e-mail doctorviji@yahoo.co.uk.

CME ANSWERS

Answers to the credit tests on page 191 of this issue

Cervical cancer screening 1C 2D

Abdominal aortic aneurysm 1B 2A

Frailty 1D 2B

Septic shock 1B 2D