Current techniques in the management of pain

Russell W. Hardy, M.D.

Department of Neurological Surgery

The management of intractable pain has been a traditional interest of the neurosurgeon. Historically, most attempts to relieve pain involved cutting pain tracts either in peripheral nerve, sensory root, brain, or spinal cord. Such procedures, whether performed by open operation or chemical block, were based on the supposition that pain sensation could be defined anatomically and that interruption of the pain pathways could relieve pain. Thus, the anterolateral cordotomy was developed shortly after the function of the spinothalamic tract was established, and proved to be particularly useful in relieving unilateral pain of cancer. Similarly, dorsal rhizotomies and peripheral neurectomies have been used to manage many types of pain, but most successfully in the treatment of tic douloureux.

Many of these ablative procedures remain extremely useful in the management of patients with certain types of pain. Unfortunately, operations aimed at the interruption of pain tracts are not always successful in relieving pain, even though they produce analgesia. The explanation lies in the anatomy of the pain system. The classic notion of pain as a discrete entity transmitted by the spinothalamic tract is only partially correct; it appears that pain is carried by an anatomically more diffuse system. It is now thought that pain

sensation is transmitted by two fiber systems.[1] The first, located in the anterolateral quadrant of the cord, carries only a portion of the pain fibers. This transmits what we might call "fast" pain, the kind that one experiences following a pin prick. However, there is a second, more diffuse type of fiber system that is poorly defined and probably bilateral. We might refer to this as "slow" pain system. This fiber system transmits much of the sensation experienced by the patient with chronic pain.

When it is realized that the sensation of pain is transmitted by a diffuse, dual system, it becomes obvious that it is difficult to relieve pain permanently by interrupting pain tracts. Moreover, it should be realized that pain is also a complex psychic phenomenon, and that mere anatomical relief of pain may not eliminate suffering. It is for these reasons a great many patients with intractable pain may be helped only temporarily or not at all by interruption of pain pathways. For such patients, other methods of pain control are being devised.

The past decade has seen the introduction of a number of new approaches to the management of patients with chronic pain. Some of these, such as the percutaneous cordotomy, involve technical improvements in established procedures; others, however, rely on neural stimulation rather than ablation. Procedures such as dorsal column stimulation (DCS) have been introduced in an attempt to help patients who do not respond to more conventional treatment. The purpose of this paper is to review some of the more important of these advances and to discuss their application.

Percutaneous cordotomy

The anterolateral cordotomy has, in the past, been the basic method for management of pain of malignant disease and certain forms of benign pain. It remains an effective operation for pain control, particularly when the pain is unilateral. It is less useful in treating "benign" pain because of the tendency for pain to recur after a year or two. It has the disadvantage, moreover, of requiring an open operation to achieve its purpose. Thus, its application is limited to patients who are in relatively good condition and have a reasonable life expectancy.

A significant advance in the technique of cordotomy occurred in 1963 when Mullan et al[2] described percutaneous cervical cordotomy. Mullan initially used a strontium-90 needle to make the lesion, but 2 years later Rosomoff et al[3] reported a percutaneous radiofrequency cordotomy. A further modification was described by Lin et al,[4] who developed an anterior approach to the lower cervical cord.

Percutaneous cordotomy has the advantage that it is at least as effective as open cordotomy in achieving analgesia and in producing relief of pain. It has the further advantage that the procedure may be performed under local anesthesia and, thus, may be used to treat patients who are poor candidates for direct surgical intervention. In addition, the fact that the patient is awake allows the surgeon to monitor the patient's neurological status, and thus achieve analgesia with a low morbidity.

The lateral cervical approach has been described but will be briefly reviewed. As seen in *Figure 1*, the spinal canal is entered with a thin walled 18-

gauge needle at C 1-2. The dentate ligament is identified with Pantopaque, and this serves to delineate the anterior half of the cord. The cord is then entered with an insulated RF electrode anterior to the dentate ligament. Confirmation of cord penetration is obtained with impedance monitoring, and the spinothalamic tract is then identified by stimulation. When an adequate placement, as defined by motor and sensory stimulation, has been achieved, an RF lesion is then placed.

As noted, this has the advantage of not requiring a general anesthetic and may be used even in poor risk patients. In general, the best candidates for this procedure are patients with unilateral extremity pain from malignant disease. Certain patients with benign conditions such as phantom limb pain, brachial plexus avulsion, or herpetic neuralgia may also benefit from percutaneous cordotomy.

Patients with bilateral pain from malignant disease may also be treated with bilateral, staged cordotomies. However, the risks of motor weakness and bladder complications are higher when a bilateral lesion must be made. In addition, the high cervical procedure harbors the additional risk of respiratory dysfunction when bilateral lesions are made, or when the patient has a marginal pulmonary reserve.[5]

Percutaneous thermocoagulation of the trigeminal ganglion

Radiofrequency coagulation has also been used to treat trigeminal neuralgia. Historically, a variety of procedures have been employed to treat this condition, ranging from peripheral neurectomies and alcohol blocks through open operations to decompress or section the fifth nerve. White and Sweet[6] reported that electrocoagulation of the gasserian ganglion was, itself, first employed in 1931. The original procedure was used extensively in Europe, but was associated with a number of complications.

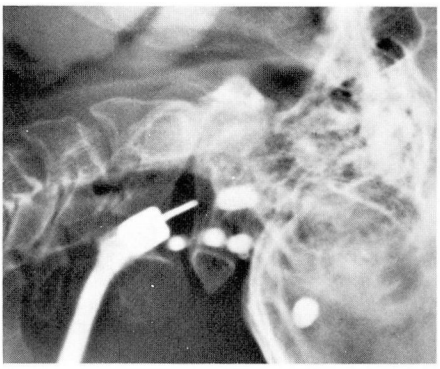

Fig. 1. Lateral roentgenogram illustrating percutaneous cervical cordotomy. The spinal needle is positioned just anterior to the dentate ligament, which is outlined by Pantopaque.

Since the introduction of radiofrequency lesion making, thermocoagulation has been revived in this country by Sweet and Wepsic[7] and by Nugent and Berry[8] with considerable success and a minimal complication rate. It has been established that relief of tic pain can be accomplished in 91% of patients with a recurrence rate of 22% over an extended follow-up period.[7] The method has the advantage of not requiring endotracheal anesthesia, of having no mortality and a relatively low complication rate. *Figure 2* illustrates the procedure as performed in a 70-year-old woman with trigeminal neuralgia in the second division. The foramen ovale is entered anteriorly with an RF electrode placement confirmed by roentgenogram. Additional localization is obtained by stimulation of the nerve. Sequential thermocoagu-

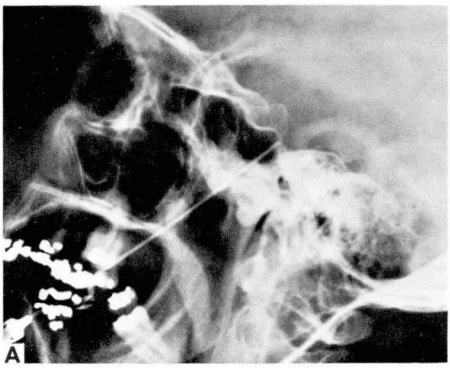

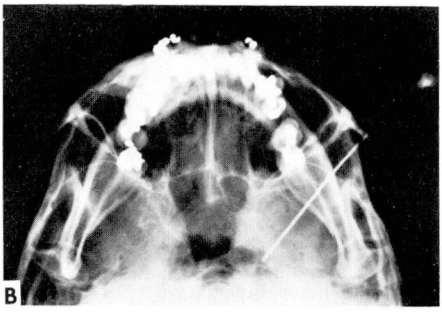

Fig. 2. A, B, Skull roentgenograms illustrating electrode placement for electrocoagulation of the gasserian ganglion.

lations of the ganglion are then performed. The lesions are controlled by monitoring the temperature of the electrode tip and by testing the patient between successive lesions. Initial electrode placement and lesion making are performed under Innovar and methohexital (Brevital) anesthesia, and the patient is awakened between lesions for testing.

Central procedures for the relief of pain

A number of surgical procedures have been developed with the aim of interrupting pain tracts within the brain.[6, 9, 10] In general, such procedures carry a significant morbidity, and their usefulness is limited to certain patients. Thus, mesencephalic or medullary tractotomy may be useful in treating some patients with pain of malignant or central origin. Medullary and mesencephalic tractotomy aim at the destruction of specific pain pathways. The mechanism of pain relief by thalamotomy is more complex, but this procedure may afford short-term relief of pain particularly for patients with pain from head and neck cancer.[10] Cingulotomy produces its effect by interruption of the limbic system and, therefore, by altering the patient's effective response to pain.[11] Although any of these operations may be useful in certain situations, their overall application remains limited to patients whose pain cannot be adequately managed by other means.

Thus far, all of the procedures we have discussed have relied on neural destruction to achieve their results. However, a new type of pain control based on stimulation of afferent fibers rather than on ablation has been developed. In 1965, Melzack and Wall[12] proposed the so-called "gate theory" of pain. Briefly stated, this theory supposes that the sensation of pain is dependent on the reciprocal actions of large and small fiber input into the dorsal column of the spinal cord. The small fibers are presumed to facilitate the transmission of pain, the large fibers to inhibit it. The theory itself has been challenged, but it has provoked the development of methods of pain control that rely on neural stimulation rather than destruction. Stimulation of afferents is performed peripherally or in the spinal cord. In either case, the underlying hypothesis is that by stimulation of large fiber afferents, neural transmission of pain

Table. Results of external stimulation for pain relief

Etiology	Good relief	Fair relief	Poor or no relief	Total
Postlaminectomy syndrome	5		8	13
Phantom limb			1	1
Postsurgical chronic pain	2		6	8
Peripheral neuropathy	1	1		2
Cancer	2		2	4
Miscellaneous somatic pain	2	1	7	10
Multiple sclerosis		1		1
Causalgia	1			1
Neuromuscular pain (uncertain etiology)	4	1	5	10
Brachial plexus avulsion	1		1	2
Postherpetic neuralgia			1	1
Total	18	4	31	53

Good relief is defined as either complete or very substantial short-term reduction in pain. Of the 18 "good" results, 10 patients felt the pain relief sufficient to warrant purchase of the device for home use. Of these, 9 enjoy continued pain relief of several months' duration.

will be inhibited and the conscious sensation of pain reduced. Several modifications will be discussed.

Stimulation of large fiber afferents

In 1968, Sweet and Wepsic[13] described a technique for stimulation of primary afferent neurons using implanted electrodes to produce analgesia. It was discovered that relief of pain could be produced by stimulating at voltages and frequencies sufficient to produce a tingling sensation in the painful area. It was also noted that pain could be relieved by external application of electrodes. Further experience with implanted and externally applied electrodes has been reported by Long,[14] who finds both methods effective in producing pain relief. Our experience is limited to the use of external stimulators and is summarized in the *Table.*

Fifty-three patients with pain of diffuse etiology were treated with EPC stimulators.* The patients were generally screened on an outpatient basis, but a few were admitted to the hospital. In general, all of these patients had chronic pain which had been refractory to standard forms of treatment. Many of them were receiving narcotic analgesics. The patients tried the stimulator for three or four sessions of about an hour each. No attempt at psychiatric screening was made. Electrode placements were performed by a nurse clinician. An attempt was made to place the electrodes over nerves supplying the painful area, but varying electrode placements were utilized. As can be seen, the overall success rate was relatively low. It should be noted, however, that in those patients for whom stimulation was successful, the degree of pain relief was often striking. It should be further noted that external stimula-

* Stimulators obtained from Stimulation Technology, Inc., Minneapolis, Minnesota.

tion was associated with no morbidity other than occasional skin irritation. Although external stimulation was effective in only a minority of patients, we feel it is a useful adjunct to managing patients with intractable, benign pain and may be very successful in individual cases.

Dorsal column stimulation

DCS differs from primary afferent stimulation only in that the electrical stimulus is applied to the dorsal column of the cord rather than to the large afferents in peripheral nerve. This technique was first described by Shealy et al,[15] and experience with it has been reported by other authors.[16] The stimulator is installed by performing a laminectomy and placing intradural or subdural electrodes over the dorsal column. The electrodes are connected subcutaneously to a dorsal column receiver which is generally placed on the anterior chest wall. The patient then stimulates the subcutaneous receiver with an external transmitter. Relief of pain is associated with a tingling or buzzing sensation in the painful area. Various subjective responses have been obtained, some patients requiring almost continuous stimulation for relief of pain, whereas others find that relief can be adequately obtained with periods of intermittent stimulation separated by several hours.[16]

In the several years that DCS has been used, degrees of initial success ranging from 20% to 65% have been reported. DCS is associated with a number of complications, most seriously the threat of occasional neurological deficit.[17] Various attempts at prescreening of patients with external stimulation or with psychometric profiles have been employed. A favorable response to external stimulation suggests a good response to DCS.[18] In general, most of the patients treated with this method have had some form of benign pain refractory to other forms of treatment. Paradoxically, it has been suggested that patients with pain from cancer do not respond well to DCS.[17]

At present it would appear that DCS has a definite place in the control of pain, but its long-term effectiveness has yet to be established.

Other techniques

In addition to the methods described, other techniques merit mention. The value of acupuncture remains unproved, but individual successes have been reported.[19] Even it is not without morbidity;[20] probably acupuncture should be used only when conventional methods of pain relief have been unsuccessful. Psychotropic drugs have been employed for patients with refractory benign pain, again with success in certain situations.[21] Other techniques such as facet rhizotomy for the treatment of sciatic type pain are in the developmental stage.[18]

Summary

During the past decade a number of new methods have been developed for the management of pain. Although the long-range effectiveness of some methods has not been established, these procedures have nonetheless stimulated considerable interest in a group of patients who may be difficult to manage. At present, the patient with pain from cancer would appear to be managed best with conventional ablative techniques, such as percutaneous cordotomy. Patients with certain forms of benign pain, such as phantom limb syndrome or postherpetic neuralgia,

may also be successfully treated with percutaneous cordotomy. Patients with tic pain who are refractory to drug therapy may be considered for percutaneous RF trigeminal rhizolysis. Those with such difficult problems as the postlaminectomy syndrome may not respond to conventional methods. Upon failure of these methods, such patients are potential candidates for the use of such newer techniques as afferent or dorsal column stimulation.

References

1. Mountcastle VB, editor: Medical Physiology. Twelfth edition. St. Louis, CV Mosby Co, 1968.
2. Mullan S, Harper PV, Hekmatpanah J, et al: Percutaneous interruption of spinal-pain tracts by means of a strontium-90 needle. J Neurosurg **20:** 931–939, 1963.
3. Rosomoff HL, Carroll F, Brown J, et al: Percutaneous radiofrequency cervical cordotomy; technique. J Neurosurg **23:** 639–644, 1965.
4. Lin PM, Gildenberg PL, Polakoff PP: An anterior approach to percutaneous lower cervical cordotomy. J Neurosurg **25:** 553–560, 1966.
5. Mullan S, Hosobuchi Y: Respiratory hazards of high cervical percutaneous cordotomy. J Neurosurg **28:** 291–297, 1968.
6. White JC, Sweet WH: Pain and the Neurosurgeon. Springfield, Charles C Thomas, 1969.
7. Sweet WH, Wepsic JG: Controlled thermocoagulation of trigeminal ganglion and rootlets for differential destruction of pain fibers. Part I. Trigeminal neuralgia. J Neurosurg **40:** 143–156, 1974.
8. Nugent GR, Berry B: Trigeminal neuralgia treated by differential percutaneous radiofrequency coagulation of the gasserian ganglion. J Neurosurg **40:** 517–523, 1974.
9. Nashold BS Jr, Wilson WP, Slaughter DG: Stereotaxic midbrain lesions for central dysesthesia and phantom pain. Preliminary report. J Neurosurg **30:** 116–126, 1969.
10. Roth DA, Mark VH: Thalamotomy for relief of pain. *In,* Neurological Surgery. Vol. 3. Edited by JR Youmans, Philadelphia, WB Saunders Co, 1973, pp 1783–1789.
11. Foltz EL, White LE: Pain "relief" by frontal cingulumotomy. J Neurosurg **19:** 89–100, 1962.
12. Melzack RF, Wall PD: Pain mechanisms; a new theory. Science **150:** 971–979, 1965.
13. Sweet WH, Wepsic JG: Treatment of chronic pain by stimulation of fibers of primary afferent neuron. Trans Am Neurol Assoc **93:** 103–107, 1968.
14. Long DM: Electrical stimulation for relief of pain from chronic nerve injury. J Neurosurg **39:** 718–722, 1973.
15. Shealy CN, Mortimer JT, Hagfors NR: Dorsal column electroanalgesia. J Neurosurg **32:** 560–564, 1970.
16. Nashold BS, Friedman H: Dorsal column stimulation for control of pain. J Neurosurg **36:** 590–597, 1972.
17. Fox JL: Dorsal column stimulation for relief of intractable pain; problems encountered with neuropacemakers. Surg Neurol **2:** 59–64, 1974.
18. Burton C: Seminar on dorsal column stimulation; summary of proceedings. Surg Neurol **1:** 285–289, 1973.
19. Mann F, Bowsher D, Mumford J, et al: Treatment of intractable pain by acupuncture. Lancet **2:** 57–60, 1973.
20. Carron H, Epstein BS, Grand B: Complications of acupuncture. JAMA **228:** 1552–1554, 1974.
21. Taub A: Relief of postherptic neuralgia with psychotropic drugs. J Neurosurg **39:** 235–239, 1973.