CLEVELAND CLINIC QUARTERLY
Volume 38, April 1971
Copyright © 1971 by The Cleveland Clinic Foundation
Printed in U.S.A.

Congenital rubella syndrome with viral esophagitis

An electron microscopic study

EYAD M. CHATTY, M.D.
Department of Pathology

M. OSSAMAH TOMEH, M.D.*

ROBERT D. MERCER, M.D.
Department of Pediatrics

DALLAS G. OSBORNE
Department of Pathology

THE congenital rubella syndrome is a multisystemic disorder with specific teratogenic anomalies and a variety of complications. This is a report on the ultrastructure of a viral hemorrhagic esophagitis, a hitherto not reported complication in congenital rubella syndrome.

Report of a case

The patient, a 15-month-old Caucasian female was born at full term to a woman who had had rubella at three weeks of gestation. After birth the patient was noted to have a patent ductus arteriosus, bilateral cataracts, left hip dysplasia, and microcephaly. The patent ductus arteriosus was repaired at 14 weeks. A cataract operation was performed when the patient was 14 months old. Two weeks later she was admitted to the Cleveland Clinic Hospital with a fever of unknown origin, anorexia and vomiting. Between the time of operation and the fever, the patient had been doing well. There was no history of convulsions or diarrhea. On physical examination the patient was moderately dehydrated, irritable, pale and distressed. The pupils reacted to light, the ears were normal, and the neck supple. The chest showed an old surgical scar; the lungs were clear to auscultation, and the heart sounds were normal. Laboratory studies revealed a blood sugar of 238 mg per 100 ml, and a blood urea nitrogen of 57 mg per 100 ml. The serum electrolytes were normal. The hemoglobin was 15.4 g per 100 ml. The hematocrit was 44 percent; the white cell count was 11,500 per cu mm with 34 percent lymphocytes, 61 percent polymorphonuclear cells and 5 percent monocytes. No abnormal cells were noted. The cerebrospinal fluid was clear and acellular, the protein level 25

* *Former Fellow, Department of Pediatrics, The Cleveland Clinic Foundation, Cleveland, Ohio. Present address: Department of Pediatrics, Charity Hospital, Louisiana State University.*

mg per 100 ml, and the sugar 172 mg per 100 ml. The urine was normal. The rubella complement fixation and neutralization tests were positive at the time of repair of the patent ductus; the rubella hemagglutination inhibition test was positive at a titer of 1:80. The temperature on admission was 106 F. Numerous blood and throat cultures were negative; no virus cultures were attempted. A few hours after admission the patient had respiratory arrest; an intubation was performed and the respirator was applied to the patient. She died less than 24 hours after admission.

Autopsy findings

At autopsy there was histologic evidence of viral interstitial pneumonitis, and a nodularity of the aortic valve which on section showed a deposition of a mucopolysaccharide material. Sections from the eyes showed focal areas of degeneration and proliferation of the retinal pigment epithelium, mainly in the posterior pole. The brain was microcephalic and weighed 820 g. The gastrointestinal tract was filled with fresh red blood and the only lesion found was in the esophagus.

Numerous superficial erosions and freshly clotted blood were observed at the lower third of the esophagus. Multiple sections taken from the esophagus for histologic study revealed dilatation and congestion of the capillaries in the upper dermis with a few of them ruptured through the mucosa and giving rise to the massive gastrointestinal hemorrhage (*Fig. 1*). Multinucleated squamoid cells were present in the epithelial layer of the esophagus. Intranuclear inclusions that stained red with the hematoxylin-eosin stain were found in many of the mono- and multinucleated cells (*Inset, Fig. 1*).

Sections for the electron microscope were prepared from 2 x 2 x 1 mm blocks of esophagus which had been already fixed in formalin for 24 hours. These blocks were postfixed for one hour with osmium tetroxide; then the specimen was dehydrated with ethyl alcohol and embedded in mara glass. Multiple 1 micron thick sections were obtained, and selected areas showing the giant cells with the intranuclear inclusions were chosen for thin sectioning. These thin sections were stained with uranyl acetate and lead citrate and then viewed. The electron microscope was an RCA Model EMU-4.

Intranuclear inclusions were observed in all of the multinucleated giant cells (*Fig. 2*) as well as in some of the mononuclear cells. All of these cells were epithelial in nature with desmosomes present between them. The intranuclear inclusions were composed of bundles of paracrystalline structures that measured between 1 and 2 microns in greatest diameter. Higher magnifications of × 102,500 (*Inset, Fig. 2*) showed these inclusions to be composed of multiple dense granules, each measuring approximately 100 angstroms, and each surrounded by an outer rim of less electron-dense material. These granules were present in a fairly light concentration in certain areas and in heavy concentrations in others (*Fig. 3*). No such structures were noted in the cytoplasm. The heterochromatin, nuclear membrane, endoplasmic

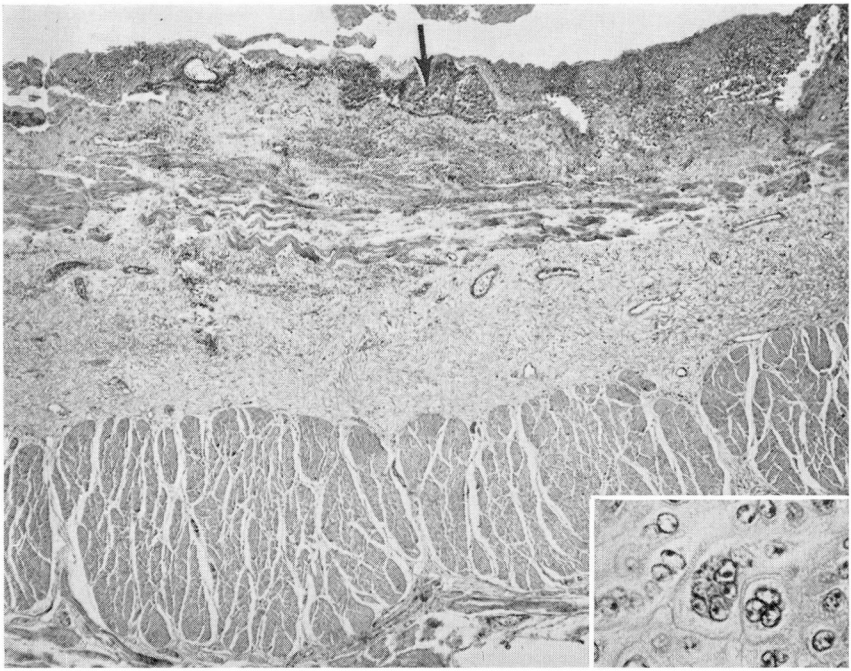

Fig. 1. Section of esophagus showing vascular dilatation in the upper dermis with rupture of some vessels and hemorrhage through the mucosa. Epithelium shows ulceration, spongiosis and presence of giant cells (arrow). Hematoxylin-eosin stain; magnification × 40. Inset: Giant multinucleate cells with intercellular bridges and intranuclear inclusions. Hematoxylin-eosin stain; magnification × 400.

reticulum, Golgi apparatus, mitochondria and plasma membrane did not reveal any abnormalities.

Discussion

Various manifestations and complications affecting many organs have been reported in association with the congenital rubella syndrome.[1, 2] A review of the literature on these complications is not the purpose of this paper, since inclusive reviews and other reports of specific organ involvement already have been published.[3-8] In spite of the considerable literature on this subject, the gastrointestinal tract has received little mention. Hardy, Sever, and Gilkeson[9] reported a case of congenital rubella manifested as gastroenteritis; Rorke and Spiro[5] reported the presence of ileitis with pneumonia and necrosis of the kidneys in another case of congenital rubella syndrome. The rubella virus has been isolated from the gastrointestinal tract on at least two occasions.[10, 11]

To our knowledge this is the first report of esophagitis complicating the congenital rubella syndrome. The multinucleation, intranuclear inclusions and the presence of the virus-like particles revealed by the electron micro-

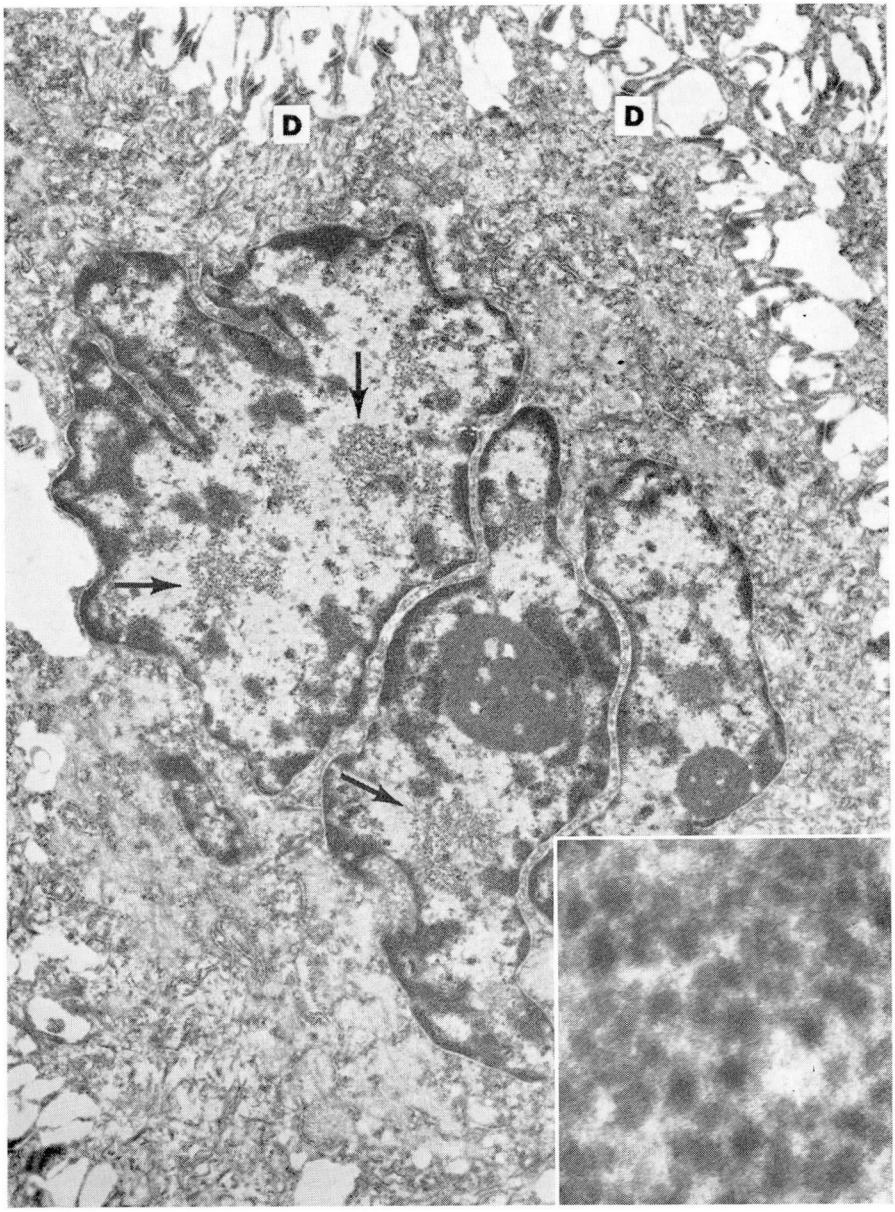

Fig. 2. Giant multinucleate cell with intranuclear inclusions (arrows) and desmosomes (D) between two adjacent cells. Electron micrograph, magnification × 12,000. Inset: High magnification of the viral particles showing a central dense core and an outer less electron-dense zone. Electron micrograph, magnification × 102,500.

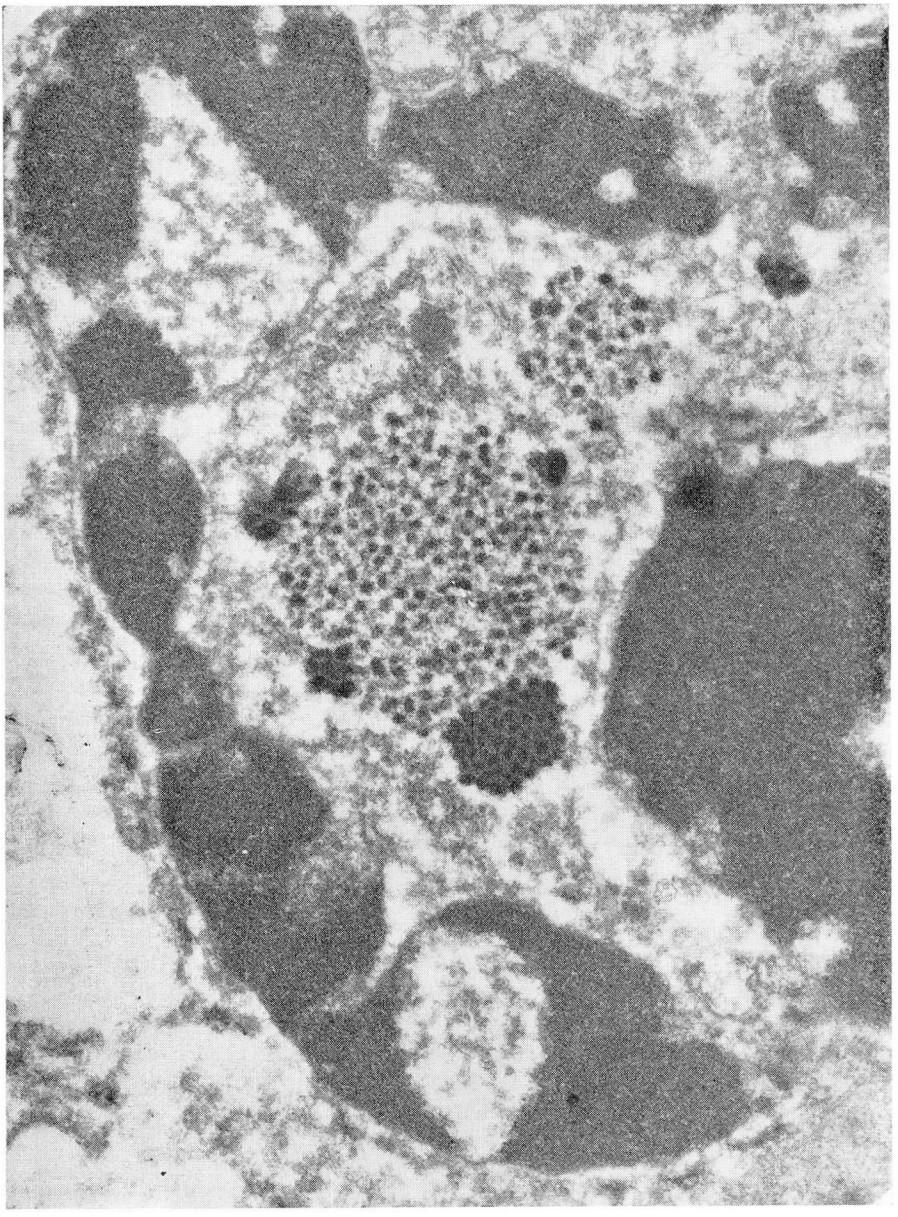

Fig. 3. Portion of nucleus with intranuclear paracrystalline profiles representing viral particles. Electron micrograph, magnification × 26,000.

scope suggest that the esophagitis is of viral origin. The virus-like particles noted here differ morphologically from the rubella virus.[12] The exact nature of the virus in this case is difficult to determine.

Summary

A case of congenital rubella syndrome complicated by hemorrhagic esophagitis and terminating in massive hemorrhage is described. Microscopically, the mucosa of the esophagus contained many multinucleated and mononuclear squamous cells, with intranuclear inclusions. The electron microscope revealed these inclusions to be paracrystalline profiles composed of multiple dense granules, each surrounded by an outer rim of less electron-dense material. This suggests that these inclusions are of viral origin.

References

1. Rubella Symposium. Amer. J. Dis. Child. **110:** 345–476, 1965.
2. Cooper, L. Z.: Rubella—a preventable cause of birth defects, *in* Intrauterine Infections, Vol. 4, p. 23–35, The National Foundation of Birth Defects, 1968.
3. Hastreiter, A. R., and others: Cardiovascular lesions associated with congenital rubella. J. Pediat. **71:** 59–65, 1967.
4. Kresky, B., and Nauheim, J. S.: Rubella retinitis. Amer. J. Dis. Child. **113:** 305–310, 1967.
5. Rorke, L. B., and Spiro, A. J.: Cerebral lesions in congenital rubella syndrome. J. Pediat. **70:** 243–255, 1967.
6. Rudolph, A. J., and others: Osseous manifestations of the congenital rubella syndrome. Amer. J. Dis. Child. **110:** 428–433, 1965.
7. Singer, D. B., and others: Pathology of the congenital rubella syndrome. J. Pediat. **71:** 665–675, 1967.
8. Zinkham, W. H.; Medearis, D. N., Jr., and Osborne, J. E.: Blood and bone marrow findings in congenital rubella. J. Pediat. **71:** 512–524, 1967.
9. Hardy, J.; Sever, J., and Gilkeson, M.: Declining antibody titers in children with congenital rubella. J. Pediat. **75:** 213–220, 1969.
10. Cooper, L. Z., and others: Neonatal thrombocytopenic purpura and other manifestations of rubella contracted in utero. Amer. J. Dis. Child. **110:** 416–427, 1965.
11. Bellanti, J. A., and others: Congenital rubella. Amer. J. Dis. Child. **110:** 464–472, 1965.
12. von Bonsdorff, C. H., and Vaheri, A.: Growth of rubella virus in BHK21 cells: electron microscopy of morphogenesis. J. Gen. Virol. **5:** 47–51, 1969.